

Cutaneous Implantation Metastasis of Cholangiocarcinoma after Percutaneous Transhepatic Biliary Drainage

Alberto Balzani¹, Rita Clerico¹, Robert A. Schwartz², Serena Panetta¹, Chiara Panetta¹, Nevena Skroza¹, Daniele Innocenzi¹, Stefano Calvieri¹

¹Department of Dermatology and Plastic Surgery, La Sapienza University, Rome, Italy;

²New Jersey Medical School, Newark, New Jersey, USA

Corresponding author:

Prof. Daniele Innocenzi, MD
Department of Dermatology and Plastic Surgery
La Sapienza University of Rome
Via del Policlinico 155
00161 Rome,
Italy
danielle.innocenzi@uniroma1.it

Received: February 11, 2005.

Accepted: April 10, 2005.

SUMMARY Percutaneous transhepatic biliary decompression is a preoperative surgical adjunct in patients with obstructive jaundice that has been in use since 1973. It is recommended that this procedure be adopted for both palliative treatment in unresectable patients and as a preoperative means of lowering serum bilirubin in patients with potentially resectable malignancies of the pancreas or biliary tract. Metastatic tumor seeding along the transhepatic biliary catheter is an unusual complication resulting from this procedure but there have been a few cases reported in the literature. Below is a report on a 59-year-old woman in whom the percutaneous transhepatic catheter drainage of the biliary tree, performed before surgical resection of a cholangiocarcinoma, caused cutaneous tumor implantation at the catheter site 3 months later. The clinical aspect was morphea-like and histopathologic examination revealed typical features of a dermal metastasis of adenocarcinoma. Immunohistochemistry revealed cytoplasmic positivity for cytokeratin 7-19, specific for the biliary tract epithelium. A review of the literature available led us to conclude that port-site metastasis in patients with obstructive jaundice treated with percutaneous transhepatic biliary decompression was an unusual but possible complication. In fact, many catheter-tract metastatic deposits in the liver parenchyma, detected at autopsy or on operation, are mistakenly identified as hematogenous or lymphatic metastasis and are not attributed to a catheter-related process. We also report on this case because of the atypical morphea-like aspect of the skin metastasis.

KEY WORDS: percutaneous transhepatic biliary drainage; morpheiform cutaneous metastasis; cholangiocarcinoma; immunohistochemistry

INTRODUCTION

Percutaneous transhepatic biliary drainage (PTBD) has become an established and effective method of treatment for malignant obstructive jaundice. Although PTBD is considered safe, the procedure is not entirely free of complica-

tions, which include bile peritonitis, cholangitis, catheter dislocation, or hemorrhage. Metastatic tumor seeding along the transhepatic biliary catheter is a very rare complication and until now there have been very few reported cases (1).

We recently treated a patient in whom percutaneous biliary drainage was employed before an operation, and which resulted in an atypical cutaneous morphea-like tumor implantation at the catheter site 2 months later. This led us to discuss "the theories and the realities" of port-site metastasis and the usefulness of percutaneous transhepatic biliary decompression.

CASE REPORT

In October 2001, a 59-year-old woman was admitted to the Department of Dermatology and Plastic Surgery of the La Sapienza University of Rome, with a morphea-like plaque involving the mesogastric region. The lesion was localized near a surgical scar (Fig. 1). Her past medical history included hypertension that had been treated with Ca-antagonists from 1990. On January 15, 2001,

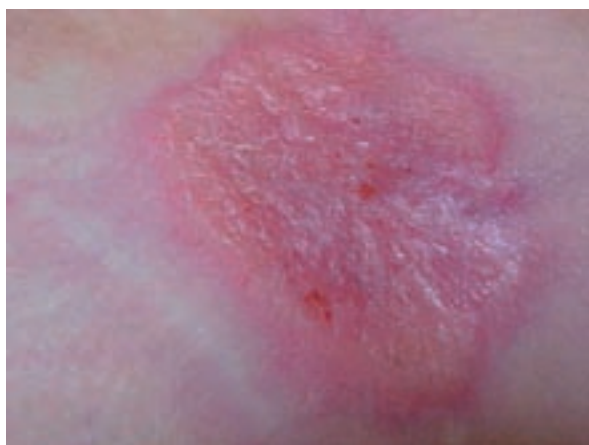

Figure 1. A morphea-like plaque involving the mesogastric region near surgical scar.

she was admitted to the Rome Medical Hospital for malaise and jaundice. Examinations including computed tomography (CT) scanning and ultrasonography (US) of the abdomen revealed a tumor mass in the enhanced common bile duct. Total bilirubin at the time of admission was 8.5 mg/dl. On January 16, 2001, PTBD was performed and the total bilirubin level decreased to normal. On February 1, 2001, the patient underwent PTBD with type II reconstruction and no evidence of liver metastasis or intra-abdominal spread of the neoplasm was found. The final histologic diagnosis was cholangiocarcinoma of the common bile duct. No metastasis was found in the resected lymph nodes. After the operation, the patient was given chemotherapy treatment consisting of 200 mg/day of 5-fluorouracil intravenously for 10 days and 10 mg/day of cisplatin intravenously for 10 days, and the patient was discharged on the postoperative

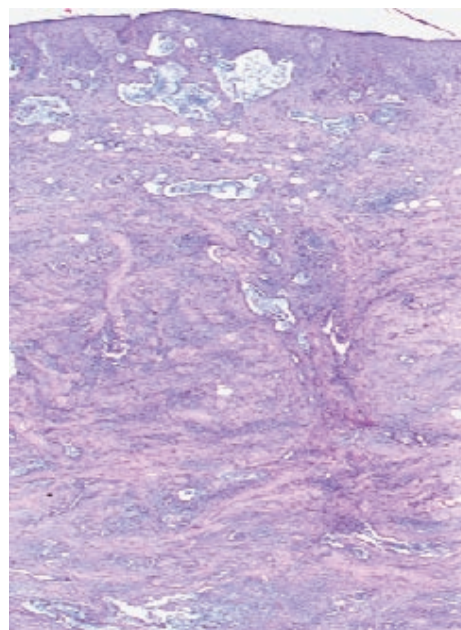


Figure 2. A dermal adenocarcinomatous infiltration of epithelial neoplastic cells, organized in ducts and cords.

day 40. In April 2001, the patient developed an erythematous macule which had subsequently enlarged as a nodule that underwent a sclerotizing process at the skin site of PTBD. Physical examination revealed a sclerotic plaque measuring 2.5 to 3 cm in diameter in the mesogastric region. The lesion was red in color with a well circumscribed border, and it was near the surgical scar.

A biopsy specimen of the lesion was obtained. Histologically, the lesion showed dermal adenocarcinomatous infiltration of epithelial neoplastic cells, organized in ducts and cords and occasionally forming mucinous lakes (Fig. 2). At high power, the abnormal shape and size of the epithelial cells were very evident. Areas of sclerosis of the stroma with hypertrophic collagen bundles were occasionally observed (Fig. 3); they were responsible for the clinical aspect of the lesion. The positivity for cytokeratins 7 and 19 revealed the biliary derivation of the neoplastic epithelial cells (Fig. 4). The lesion was completely excised under local anesthesia. The patient was re-examined at 3-month intervals for one year, with no evidence of recurrence so far.

DISCUSSION

In 1973, Molnar and Stockum presented the first reported series (2), in which PTBD was used as a diagnostic and therapeutic procedure in patients with obstructive jaundice. Several subsequent

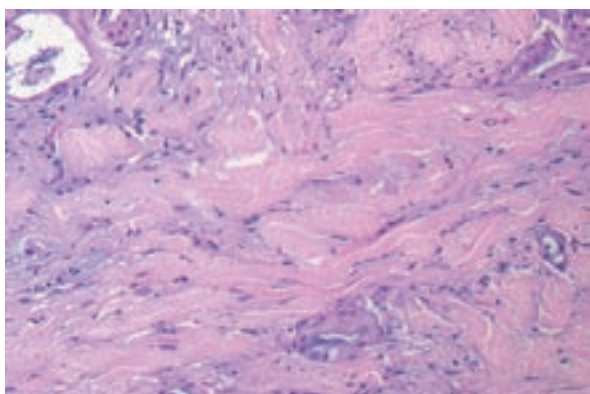


Figure 3. Areas of sclerosis of the stroma with hypertrophic collagen bundles.

reports suggested that this procedure, by improving hepatic function before an operation, could reduce the postoperative incidence of morbidity and mortality in patients with hyperbilirubinemia, and its use was recommended as a preoperative adjunct in patients with both benign and malignant disease. However, these retrospective studies compared sequential groups of patients with and without preoperative drainage (3,4). Major complications of PTBD include bacteremia, septicemia, hemorrhage (0.2%), catheter dislocation (5%), and bile leak with or without peritonitis (3%). Minor complications include periprocedural pain (2%-20%), incomplete catheter dislocation (5%-18%), catheter obstruction (3%-27%) and pneumothorax (0.5%). Bacteremia and septicemia occur in 12%-47% of patients, but they are reduced significantly by the preprocedural use of antibiotics (5-6).

Implantation metastasis is another possible complication which has been documented in 19 patients in the literature (including this case report) (1).

How can we explain the port site metastases in these cases and in our patient? There are a few theories: (a) transfer of tumor cells; (b) the effect of the pneumoperitoneum on tumor growth; and (c) perineural tumor growth (7).

a) Tumor cells may theoretically arrive at the trocar wounds by direct contact, indirect spread, or by hematogeneous route. One report states that during a fine-needle aspiration biopsy, approximately 1,000 cells can be seeded along the needle track (8). Direct contamination of the wounds by the tumor cell-carrying instruments or direct contact of the wounds with the tumor specimen is the most probable way.

b) Classic experiments by Eggermont *et al.* showed that laparotomy stimulated subcutaneous

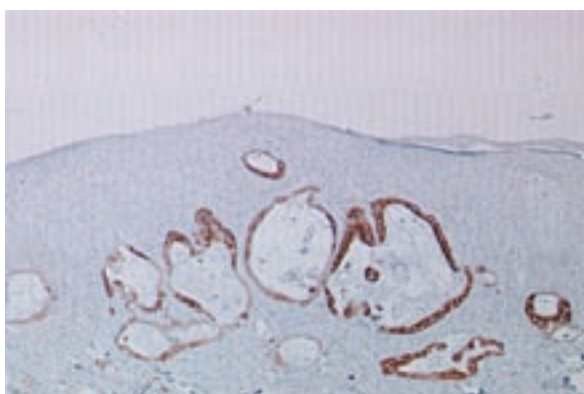


Figure 4. The positivity of the cytokeratins 7 and 19.

ous tumor growth due to a direct depressant effect of the operative system on the immune system (9).

c) A third possible way is tumor cell growth along the tract similar to perineural tumor growth.

In the light of these considerations, we believe that, as reported in the literature, many catheter-tract metastatic deposits are detected at autopsy but are mistakenly identified as arising from a hematogenous or lymphatic source and are not attributed to a catheter-related process.

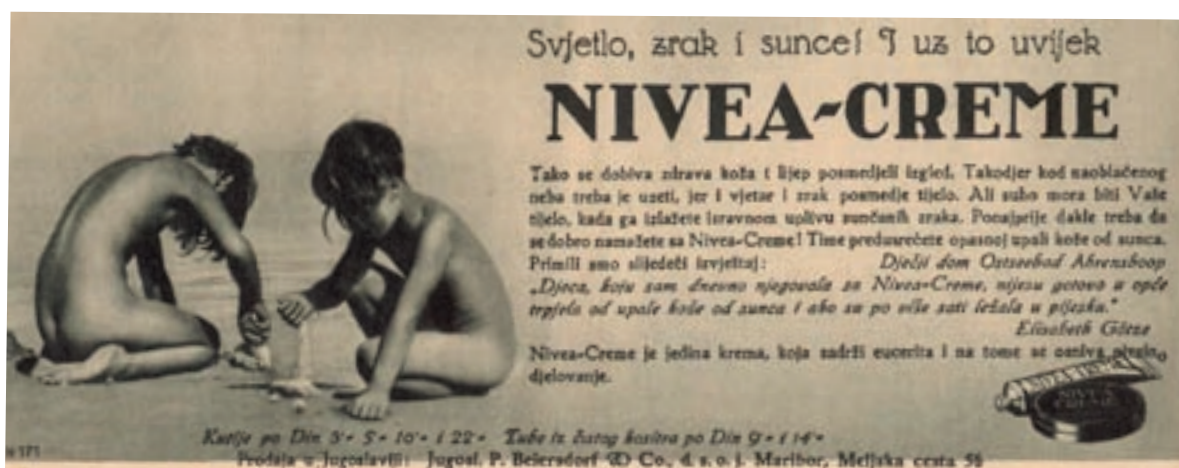We also report on this case because of the unusual clinical morphea-like manifestation. Clinically, a sclerotic plaque may suggest an annular granuloma, morphea, sclero-atrophy scar or a xanthogranuloma. In fact, most cutaneous metastases arise as nonspecific painless dermal or subcutaneous nodules with an intact, overlying epidermis. The most common clinical finding are clusters of discrete, firm, painless nodules emerging rapidly without explanation at a given anatomic site, which proliferate rapidly and then remain stationary (10).

We also report the long survival of our patient: cutaneous metastases still have a poor prognosis, especially in patients with cancer of the lung, ovary, upper respiratory tract and, as in our case, upper digestive tract.

In conclusion, we report on this case because we believe that the incidence of implantation metastases after fine-needle procedures is probably underestimated: we do not recommend that invasive techniques be abandoned, but we would simply like to warn of their rare but real risk; because of the unusual clinical finding of the lesion with a morphea-like appearance, and because our patient is still alive 1 year after the cutaneous recurrence.

References

1. Loew R, Dueber C, Schwarting A, Thelen M. Subcutaneous implantation metastasis of a cholangiocarcinoma of the bile duct after percutaneous transhepatic biliary drainage (PTBD). *Eur Radiol* 1997;7:259-61.
2. Molnar W, Stockum AE. Relief of obstructive jaundice through percutaneous transhepatic catheter – a new therapeutic method. *AJR Am J Roentgenol* 1974;122:356-67.
3. Nakayama T, Ikeda A, Okuda K. Percutaneous transhepatic drainage of the biliary tract: technique and results in 104 cases. *Gastroenterology* 1978;74:554-9.
4. Denning DA, Ellison EC, Carey LC. Preoperative percutaneous transhepatic biliary decompression lowers operative morbidity in patients with obstructive jaundice. *Am J Surg* 1981;141:61-5.
5. Carrasco CH, Zornoza J, Bechtel WJ. Malignant biliary obstruction: complications of percutaneous biliary drainage. *Radiology* 1984;152:343-6.
6. Gunther RW, Schild H, Thelen M. Percutaneous transhepatic biliary drainage: experience with 311 procedures. *Cardiovasc Intervent Radiol* 1988;11:65-71.
7. Hubens G. Port site metastasis: where are we at the beginning of the 21st century? *Acta Chir Belg* 2002;102:230-7.
8. Casella G, Cacopardo E, Rovere G, Buda C, Cascinu S, Baldini V. Cutaneous seeding after ultrasound-guided percutaneous ethanol injection for treatment of hepatocellular carcinoma. *J Clin Ultras* 2001;29:354-8.
9. Eggermont A, Steller E, Parquet R. Local regional promotion of tumour growth after abdominal surgery is dominant over immunotherapy with interleukin-2 and lymphokine activated killer cells. *Cancer Detect Prev* 1988;12:421-9.
10. Schwartz A. Cutaneous metastatic disease. *J Am Acad Dermatol* 1995;33:161-82.



Sun, air and light with Nivea cream forever.
From the Nivea collection of Zlatko Puntijar (1927)