

Is the Term »Fasciculus Opticus Cerebralis« more Justifiable Than the Term »Optic Nerve«?

Božo Vojniković¹, Snježana Bajek², Goran Bajek³, Ines Strenja-Linić⁴ and Aron Grubešić⁵

¹ Velika Gorica University of Applied Sciences, Velika Gorica, Croatia

² University of Rijeka, School of Medicine, Department of Anatomy, Rijeka, Croatia

³ University of Rijeka, Rijeka University Hospital Center, Department of Neurosurgery, Rijeka, Croatia

⁴ University of Rijeka, Rijeka University Hospital Center, Department of Neurology, Rijeka, Croatia

⁵ Rijeka Institution for Emergency Medicine, Rijeka, Croatia

ABSTRACT

The terminology of the optic nerve had already been changed three times, since 1895 until 1955 when the term »nervus opticus« was introduced in the »Terminologia Anatomica«. Following our study we claim that, from the aspect of phylogenetic evolution of binocular vision development as well as optical embryogenesis where opticus is evidently presented as a product of diencephalic structures, the addition of the term »nervus« to opticus is not adequate and justified. From the clinical aspect the term »nervus opticus« is also inadequate, both as a »nerve« that has no functional regenerative properties, unlike other cranial nerves, as well as from a pedagogical and didactical aspect of educating future physicians. We suggest that the term »Fasciculus Opticus Cerebralis« should be used as it much better explains the origin as well as its affiliation to the central nervous system.

Key words: optic nerve, embriogenetic development, fasciculus opticus cerebralis

Introduction

Phylogenetic evolution of the organ of vision began with the first monocular and then the binocular conjugate eyes of primates, following with development of the sensorial retina of a spherical configuration and so reflecting a spherical horizon. A horopter angular projection of corresponding points in the retina, in dynamic accommodation of horopter's radius variation, from punctum proximum to infinite punctum remotum, is found in the equation: $R = PD/2 / \cos \alpha$ (Vojniković, 2008) (Figure 1).

As a product of more than a million years of evolution sensorial retina developed photochromism. It originated in phototropic procaryocytes and eucaryocytes that had the possibility to synthesize ATP from the absorbed sunlight energy and in the process of electron energy transport, metabolically create photopic-mesopic visual sensorial (luminosity) curve (Figure 2).

Second cranial nerve, the optic nerve, consists of the bundles of axons sprout from large ganglion cells that

represent the third neuron in the visual pathway (Figures 3 and 4)

Visual stimuli activate rods and cones as a first step of a very complex photochemical process, from light activation and isomerization of Rhodopsin (11-cis form of retinol) to the Pre-lumirhodopsin (all-trans isomer) the first neurons located in the outer layer of the retina carry the impulses to the second neurons (Figure 3), retinal bipolar cells, and after that to large ganglion cells. Passing within the deepest strata of the retina, the axons of ganglion cells converge toward the optic disc (Figure 4) and leave the eyeball through the chorioidea and lamina cribrosa of the sclera. About one million nerve fibers are found within one optic nerve. The orbital part of the optic nerve is 2.5 cm long. Its length in optic canal is about 0.5 cm¹. One centimeter behind calal, both optic nerves decussate partially in chiasma opticum (fibers from nasal parts of each retina). The chiasm is followed by right and left tractus opticus. Most of nerve fibers in the tract are

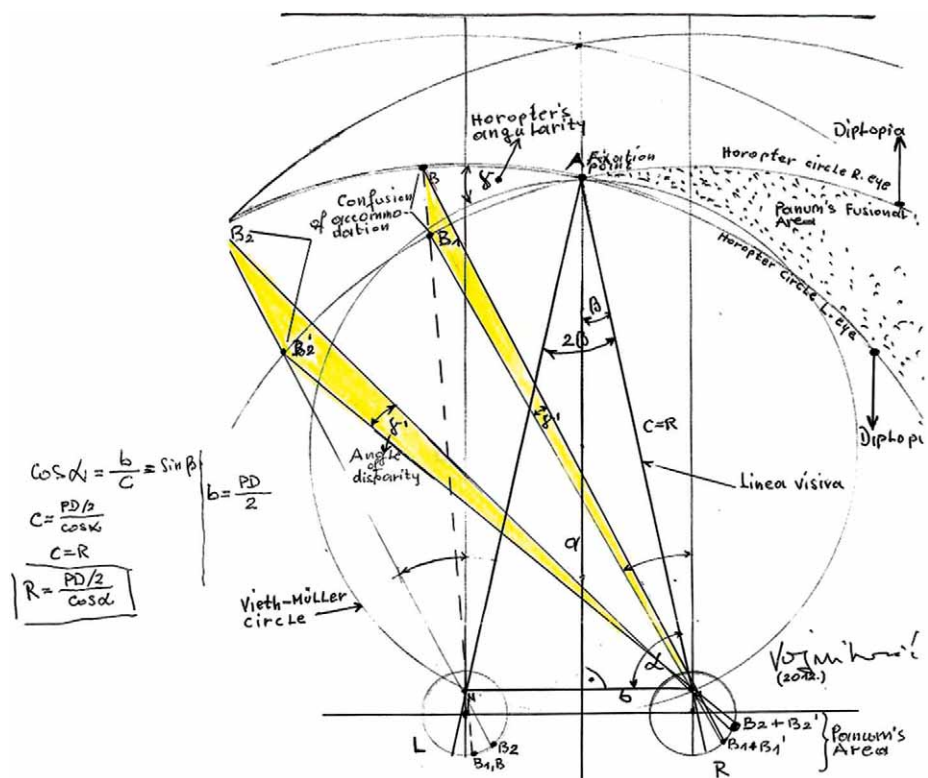


Fig. 1. The design of sensorial retina in corresponding points of horopter space. This is the first demonstrate of sensorial retina in horopters space as the function of dynamic accommodation, with determination of horopters radius variation, in very simple mathematical equation of geometrical optics: $R = PD/2 | \cos \alpha$.

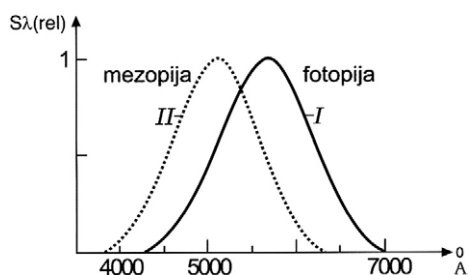


Fig. 2. The relative visual sensibility curve is presented with the function of wave length lambda (abscissa) and the means of relative visual perception (ordinate) as the values of minimum light-stimulus, threshold to monochromatic light in reciprocal values.

directed to corpus geniculatum laterale and subsequently to the visual cortex (Figure 5). Certain number of nerve fibers reach pretectal area for pupillar reflex and colliculus superior for reflex body movements to the light².

The optic nerve differs from other nerves embriologically and histologically. It is an outgrowth of diencephalon enveloped in meningeal sheets. Its fibers become myelinated posterior to lamina cribrosa, but myelin of optic nerve axons is a product of oligodendrocytes like in other parts of central nervous system, in contrast to myelination via Schwann cells in the peripheral nervous system. The optic nerve is wrapped with a sheet that is continuous with pia mater encephali throughout

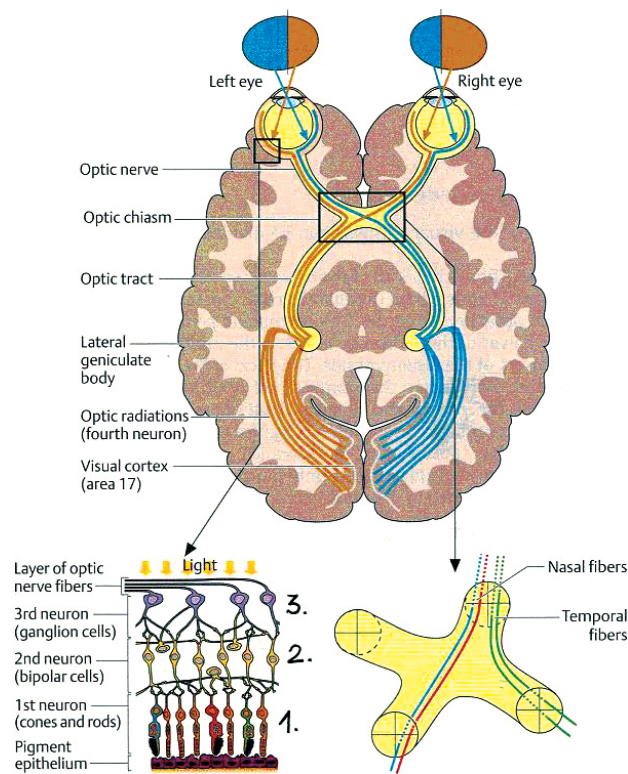


Fig. 3. Optical chiasm and the creation of visual (optic) tract.

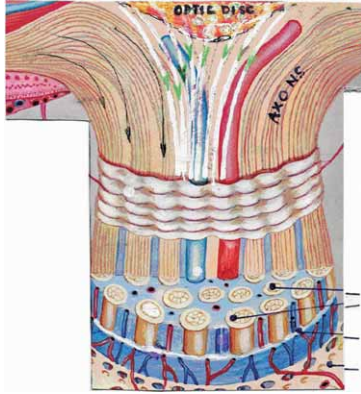


Fig. 4. Bundles of axons sprout from large ganglion cells that represent the third neuron in the visual pathway.

the length of the nerve and is named vagina interna n.optici. From the optic canal (including the canal) up to the egression of the nerve from the eyeball, this sheet is surrounded by vagina externa n.optici, the continuation of arachnoidea and dura. Between the internal and exter-

nal sheet lies a subarachnoid space that communicates with a subarachnoid space of the brain. The inner sheet also invests central vessels of the retina in the nerve as far as the optic disc. The astroglial membrane separates nerve fibers from connective tissue¹.

The optic nerve, as a part of the central nervous system, in contrast to the peripheral nervous system, hasn't the ability to regenerate. In an adult central nervous system there is little or no regeneration of destroyed ganglion cells and axons. The retinal ganglion cells die if the axons are cut, and vice versa. But it is known that optic nerve of lower vertebrates can regenerate³. Because it is a relatively easily accessible part of the central nervous system, the optic nerve and retina have been used in a variety of experimental animal trials for several decades in order to better understand reactions of damaged tissue in the central nervous system and possibly find treatments that could improve healing and subsequently its function.

The functional regeneration must be distinguished from morphological: disturbance of energy metabolism of sensorial retina, with consequent confusion in temporal

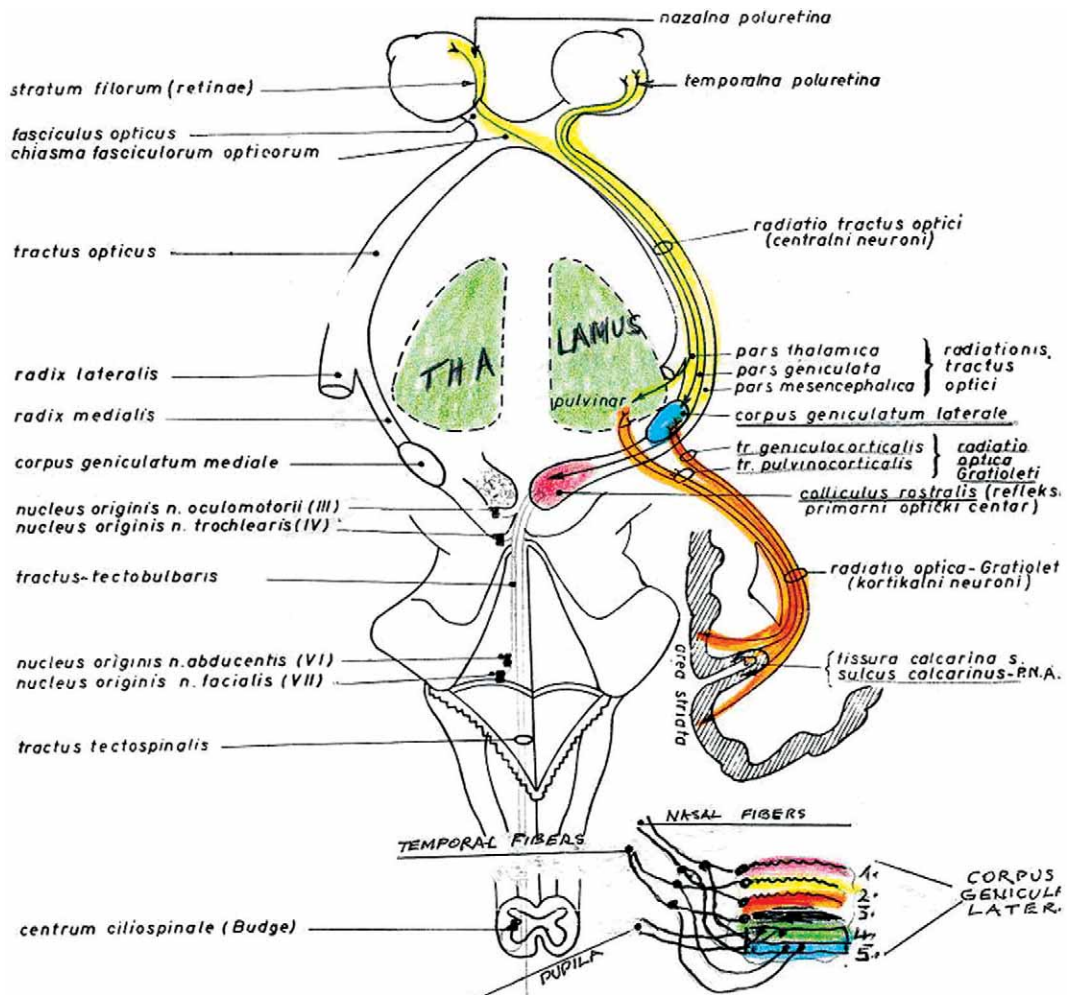


Fig. 5. Main visual pathways leading from retina to the visual cortex.

and spatial summation or the threshold levels of photopic fovea higher than 5 to 8 asb (apostilb) is a reversible process (Vojniković). This is very important because with early diagnosis, several retinal damaging processes are reversible with adequate therapy.

As it is emphasized in various anatomy and histology texts⁴ the optic nerve must, due to its embryological origin, histological structure and regenerative capacity, be regarded as an extended part of the central nervous system, and not as a usual (common) cranial nerve. Also interesting is the interpretation of W. Ernest et al in the review book »Anatomy« where it is explained that optic nerves are really tracts of the brain and consequently the portion of the optic tract anterior to the optic chiasm is often termed the optic nerve. Nevertheless, the true equivalents of optic nerves are represented in the retina by the bipolar cells which contact the optic tracts as well as lateral geniculate bodies and are diencephalic structures⁴.

Since the optic nerve does not fit to the classical definition of a nerve, over time, its name had been changed several times. Firstly, the term »nervus opticus« was determined by »Basel Nomina Anatomica« in 1895. Later, in 1935, this term was replaced by term »fasciculus opticus« in »Jena Nomina Anatomica«. But, again, by convention it was changed in the »Paris Nomina Anatomica« in 1955, and the term »nervus« has been returned⁵. Today the nomenclature found in 1998. »terminologia Anatomica« is in use and the term »nervus opticus« has become established. Sometimes, although rarely, in some articles or books today we can find the term »nervus seu fasciculus opticus«. In general, the term fasciculus is preserved for certain morphological bundles of axons within the spinal cord and brain. The same term is used in peripheral nervous system for a bundle of nerve fibers within the nerve surrounded by perineurium and also for formations that originate from united dorsal or ventral divisions of the brachial plexus.

Embryonic Development

The basis for eye development appears as an outgrowth on the lateral part of the forebrain (prosencephalon (Figures 6 and 7) in the fourth embryonic week. This hollow diverticle grows toward the ectoderm surface being wider and rounded distally, as the optical vesicle, and remains narrow proximally, as the optic stalk (Figure 8). Distal face of the optic vesicle then invaginates, transforming the single-walled optic vesicle to a double-walled optic cup⁶. The invagination that forms the optic cup occurs not at the center of the optic vesicle, but eccentrically, toward its ventral margin. Thus develops the choroidal fissure, a gap in the continuity of the wall of the optic cup and stalk that soon closes, except for its most posterior part. A rapid differentiation of two layers of the cup occurs: the external stratum of the cup persists as a single layer of cells and becomes later the pigmental layer of the retina, whilst the cells of internal stratum

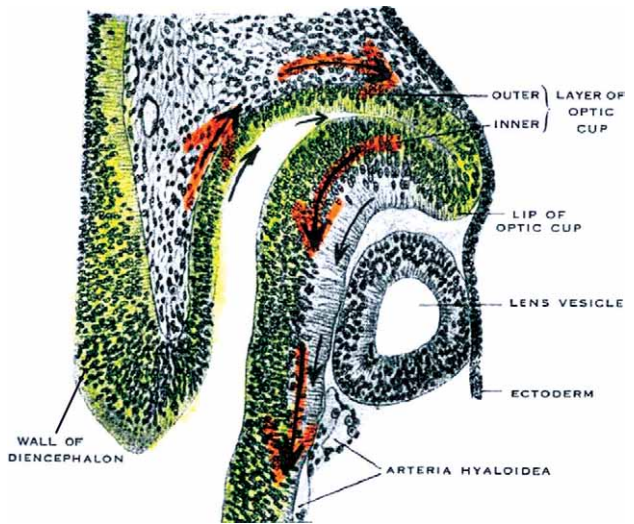


Fig. 6. Early period of embryo development – 8.5 mm. It is visible that inner layer of retina is continuous trough the wall of diencephalon. Arrows show the direction of temporary development of retina from diencephalon. (Modified from »Wolff's Anatomy of the Eye and Orbit«).

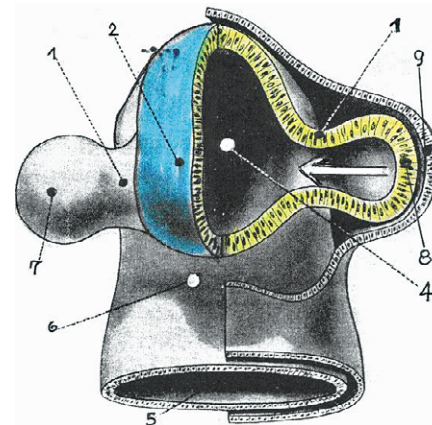


Fig. 7. 4 mm human embryo, the connection of eye development-optic vesicle from prosencephalon through extension of optic stalk. Arrow shows the direction of retinal invagination, contrary to the direction of optics vesicle formation. (Modified of »Wolff's Anatomy of the Eye and Orbit«). (1. Optic stalk, 2. prosencephalon, 3.-4. third ventricle, 5. mesencephalic cavity, 6. midbrain flexure, 7. optic vesicle, 8. optic vesicle, 9. lens ectoderm).

proliferate to develop into nervous elements and sustentacular cells of the retina, i.e. future neural layer of retina. By the eight month all layers of the retina can be identified^{1,7} (Figure 9). The internal stratum is differentiated in only the posterior 4/5 of the optical cup, i.e. in pars optica retinae. In the anterior part, anterior to future ora serrata, the internal stratum is not differentiated into neurons but forms only one layer of epithelial cells attached to the outer pigmented layer. These two epithelial layers continue onto the posterior surface of

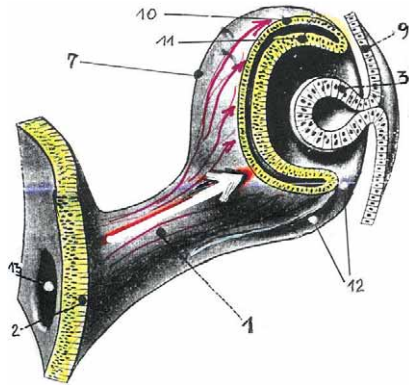


Fig. 8. 7.5 mm Human embryo. Direction of development from prosencephalon through optic stalk to invagination of sensorial retina. (Arrow shows the direction of optic cup formation from diencephalon-prosencephalon). (1. optic stalk, 2. diencephalic wall, 3. lens vesicle, 7. optic vesicle, 9. ectoderm, 10. outer layer of optic cup, 11. inner layer of optic cup, 12. foetal fissure, 13. lumen of optic stalk).

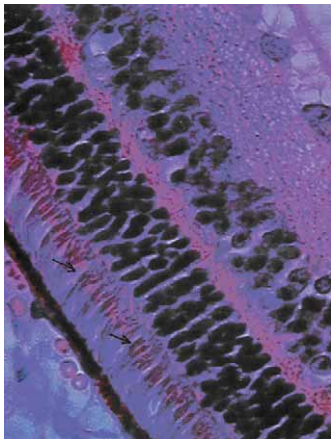


Fig. 9. Humana retina (H&E, x400 – Vojniković). Complete formation of sensorial retina elements. The arrows show the formation of sensorial elements of rods and cones, first neuron.

the developing ciliary body and iris. The ganglionic retinal cells in the optical part of retina sprout axons that form fiber layer of the inner retina surface. During the sixth week these nerve fibers continue their way surrounded by internal wall in the optic stalk to reach the brain⁷. As the number of nerve fibers continuously increases, the inner wall of the stalk becomes connected to the outer wall, and the stalk that already contains a hyaloid artery is transformed into the optic nerve. Both nerves grow in medial end posterior direction to connect in optic chiasm where they partially cross and thereafter continue as right and left optic tract. A condensation of mesenchyme around the optic nerve forms the sheets that are continuous with the meninges of the brain. The fibers of the optic nerve begin to acquire their myelin sheets shortly before birth, but the process is not completed until some time after birth¹.

Discussion

Trough several million years of eyesight organ evolution, from phototropic prokaryote and eukaryote photochemism, sensory retina had developed as a basic part of the central nervous system (CNS). The evolutionary process of sensory retina developed simultaneously with the development of CNS and as such connected both anatomically and functionally with diencephalon structures all the way to motoric and associative centers as well as Broadmann areas of the developed cortex.

Eyesight development grew from monocular special perception to binocular perception and light stimuli of horopteric spatial projection integration, forming a spheric sensory retina based on the principles of geometry optics^{8,9}. Spherically configured retinas correspond with their horopteric spatial projections, trough the laws of angular geometry optics projection and functionally, via optical accommodation, determine the curvature radius as well as the distance of the horopteric plane in space. Sensory retinocortical opticus system had evolutionary developed into an almost perfect level of wave length quantum distinction up to a threshold in the scotopic retina of only a few quant of lambda 550 mm.

Photochemical reactions in the retina are firmly quantified in a way that only one quant of light energy, by Einstein relation transforms Rhodopsin (11-cis) into Pre-lumirhodopsin (all-trans). Sensory retinocortical light threshold input is a summation effect of several stimulated photo receptors even though the elementary photochemical process is strictly quantized. Only one photon quant began the sensory development of a future retinocortical opticus.

Conclusion

CNS receives more than 90% of all information from the outside world trough sensory retina and the opticus, perception of space and time, associatively in four dimensional space, with the laws of geometry optics it adapts anatomically as a horopteric presentation of retina in space. With its photochemism CNS confirms Einsteins's law of elementary photochemical reactions: one quant of light energy = one elementary photochemical reaction.

In the end it is important to note that this discussion did not originate merely from well known facts in anatomy, embryology, phylogenesis, physiology and clinical medicine but because of didactical and pedagogical reasons in order for a student of medicine and relevant clinical professions: ophthalmology, neurology, neurosurgery, oral and maxillofacial surgery, otorhinolaryngology, to understand that opticus is not a nerve but an outgrowth of the brain, an evolutionary diencephalon structure that has no ability to regenerate *restitutio ad integrum*. This arises from every day opinion of clinicians as well as all other above mentioned professions and is important in order to take a more responsible attitude in relation to diseases of the retina and opticus as well as the complex retinocortical pathway.

REFERENCES

1. WARWICK R, WILLIAMS P, Gray's Anatomy. (Longman, London 1973). — 2. M MINN R, Last' Anatomy. (Edinburgh-London-Melbourne. New York, Churchill Livingstone, 1990). — 3. WOLPERT L, Principles of Development. (London-New York, Current Biology LTD 1998). — 4. APRIL E, Anatomy. (New York, Harwal Publishing Company 1984). — 5. KNESE K, Nomina anatomica von Kopsch F. (Stuttgart, Georg Thime Verlag 1957). — 6. CARLSON B, Patten's Foundations of Embriology. (New York, McGraw Hill 1988). — 7. LARSEN W, Human Embriology. (New York-Edinburgh-London. Melbourne-Tokyo, Churchil Livingstone 1993). — 8. VOJNIKOVIĆ B, Einsteinov zakon elementarne fotokemijske reakcije (Veleučilište Velika Gorica, Zagreb, 2005). — 9. BENČIĆ D, Geodetski instrumenti I. Optika (Sveučilište u Zagrebu, Geodetski fakultet, Zagreb, 1971).

B. Vojniković

Velika Gorica University of Applied Sciences, Zagrebačka cesta 5, 10410 Velika Gorica, Croatia

e-mail: decv@decv.com

DA LI JE NAZIV NERVUS OPTICUS OPRAVDAN ILI JE ADEKVATNIJI: FASCICULUS OPTICUS CEREBRALIS?

SAŽETAK

Terminologija optičkog živca mijenjala se tri puta, od 1895. do 1955., te konačno u »Terminologia Anatomica« uveden naziv »nervus opticus«. Autori obrazlažu, kako sa evolucijsko-filogenetskog aspekta binokularnog razvoja organa vida, tako i embriogeneze optikusa, u kojoj se evidentno prezentira optikus kao produkt diencefaličkih struktura, da naziv optikus sa atribucijom »nervus« nije adekvatan i korektan. Sa kliničkog aspekta, kao »živac« koji nema funkcionalno regenerativne sposobnosti, kao ostali kranijalni živci, te vrlo bitno sa pedagoško-didaktičkog aspekta u toku izobrazbe liječnika, naziv očni »živac« je posljedično ne adekvatan. Iz tog razloga autori predlažu naziv »nervus opticus cerebrialis«, kako bi se istaknulo njegovo porijeklo i pripadanost centralnom živčanom sustavu.