

## Osteopontin: A New Facilitating Factor in Alopecia Areata Pathogenesis?

Giulia Ganzetti<sup>1</sup>, Oriana Simonetti<sup>1</sup>, Anna Campanati<sup>1</sup>, Katia Giuliadori<sup>1</sup>, Vitangelo Scocco<sup>2</sup>, Marina Brugia<sup>2</sup>, Massimo Tocchini<sup>2</sup>, Anamaria Offidani<sup>1</sup>

<sup>1</sup>Dermatological Clinic, Department of Clinical and Molecular Medicine, Polytechnic Marche University, Ancona, Italy; <sup>2</sup>Laboratory Analysis, Ospedali Riuniti "Umberto I", Ancona, Italy

### Corresponding author:

Anna Campanati, MD  
Via conca 71  
60020 Ancona  
Italy  
annina.campanati@gmail.com

Received: August 30, 2013

Accepted: July 31, 2014

**ABSTRACT** Osteopontin (OPN) is a multifunctional glycoposphoprotein secreted by many cell types, including osteoblasts, lymphocytes, macrophages, epithelial cells, and vascular smooth muscle cells. It has been implicated in many physiological and pathological processes, such as cell-mediated immunity, inflammation, cell survival, and tumor invasion and metastasis. Osteopontin has multiple emerging roles in cutaneous biology and pathology and OPN involvement has been emphasized in Th1-mediated diseases such as psoriasis. Alopecia areata (AA) is a form of non-scarring hair loss affecting anagen stage hair follicles with a multifactorial autoimmune pathogenesis characterized by a prevalent Th1 cytokine profile. Given the role of osteopontin in Th1-mediated inflammation, we have postulated that OPN may be involved in AA pathogenesis. The aim of our study was to investigate plasma OPN level in alopecia areata before and after DPCP treatment. Our results showed that OPN plasma levels in patients with alopecia areata were higher than in healthy controls, but patients achieving complete recovery after DPCP treatment did not show a statistically significant reduction of OPN plasma levels.

**KEY WORDS:** osteopontin, alopecia areata, diphenylcyclopropenone

### INTRODUCTION

Alopecia areata (AA) is a type of non-scarring hair loss affecting anagen stage hair follicles with a multifactorial autoimmune pathogenesis and an unknown etiology (1).

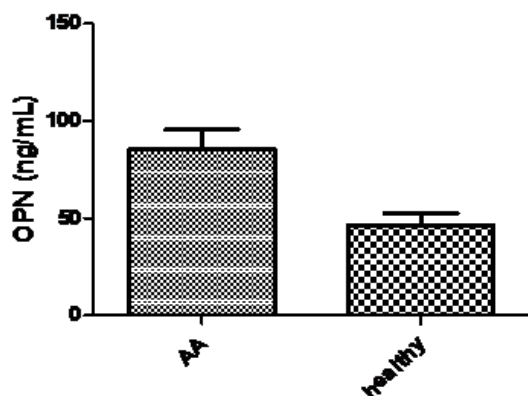
It affects about 2-3% of new patients attending Dermatology Clinics, presenting a wide range of clinical heterogeneity (1).

AA involves the scalp and any hair-bearing body surface, with possible nail localization in 10% of patients. A wide spectrum of clinical presentation can occur – from single or multiple patches of hair loss to a complete hair loss on the scalp (alopecia totalis) or the entire body (alopecia universalis); the affected skin appears normal or slightly erythematous and edematous.

Most cases of alopecia areata resolve spontaneously within 1 year, but up to 25% develop into severe forms such as alopecia totalis and alopecia universalis (1,2).

Topical immunotherapy with 2,3-diphenylcyclopropenone (DPCP) has shown to be one of the most effective treatments for severe and refractory AA and to be able to modify the "cytokine storm" (3).

Although many molecular pathways are implicated in AA immune-pathogenesis, Th1 cytokine profile seems to play a crucial role: a greater expression of interferon gamma (IFN- $\gamma$ ), interleukin 1 (IL-1), and tumor necrosis factor alpha (TNF- $\alpha$ ) has been extensively shown in serum and tissue of patients with AA compared to healthy controls (1-4).



**Figure 1.** Osteopontin plasma levels in patients with AA in comparison with healthy controls.

Osteopontin (OPN), also known as early T lymphocyte activation 1 (Eta-1), is a phosphorylated acid glycoprotein firstly identified as a bone component involved in bone formation and calcification. It is secreted by osteoblasts, lymphocytes, macrophages, keratinocytes, and vascular smooth cells (4,5). Osteopontin is also implicated in cell-mediated immunity, cell survival, inflammation, and tumor invasion and metastases (6-7).

High circulating OPN levels have been reported in several dermatological and non-dermatological diseases, but data on OPN expression in patients with alopecia areata are not available in the literature (8).

Therefore, given the role of osteopontin in Th1-mediated inflammation, we have postulated that OPN may be involved in the pathogenesis of AA.

The aim of our study was to investigate plasma OPN level in alopecia areata before and after DPCP treatment.

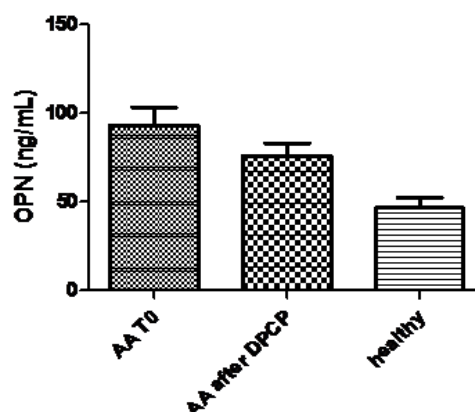
## PATIENTS AND METHODS

### Design of the study

The study is a retrospective case-control analysis approved by the Polytechnic Marche University Ethical Committee and conducted in accordance with the Declaration of Helsinki (9).

### Population

Among blood samples stored at  $-80^{\circ}\text{C}$  in our serum/plasma bank, we selected the following samples: 40 patients affected by alopecia areata (23 men and 17 women; mean age  $40.25 \pm 6.35$ ; range 20-55), both before (T0) and after twelve months (T12) of treatment with DPCP, and twenty controls obtained from healthy subjects matched for sex and age.



**Figure 2.** Osteopontin plasma levels in patients with AA before and after DPCP treatment in comparison with healthy controls.

Blood samples of patients who had had a clinical recurrence of disease after DPCP discontinuation were also retrieved.

Although not an exclusion criterium, neither familiar history of AA nor personal history of atopy or autoimmune disease, including thyroiditis, had been reported in the patient group.

### Diagnosis of alopecia areata

Diagnosis of alopecia areata had been made by a trained dermatologist based on the clinical evaluation of a diffuse or patchy alopecia and the presence of exclamation mark hairs. In patchy AA the severity of hair shedding had been evaluated by a pull test on three separate areas of the scalp: an extraction of six or more hairs was considered a positive pull test (10).

The images stored from a previous video-dermatoscopic evaluation were retrieved to evaluate the most common signs of alopecia areata: yellow dots (hair follicles filled with hyperkeratotic plugs), black dots (hair follicles containing cadaverized hairs), broken hairs, exclamation point hairs, clustered short vellus hairs, and their changes after treatment with DPCP (11).

All the enrolled patients with AA had not responded to any previous topical and intralesional corticosteroid therapy; thus after a four-weeks wash out period, they received DPCP following the protocol proposed by Happle *et al.* (12).

The DPCP concentrations had been progressively increased until erythema and/or pruritus appeared and was maintained for 36-48 hours after application. This dose was then considered the gold standard, and patients were asked to apply it until complete recovery.

### Laboratory assays

Venous blood samples had been drawn after an overnight fast at baseline (T0, before DPCP treatment) and after twelve months of DPCP application.

OPN quantitative determination was done through a solid phase sandwich ELISA kit on EDTA plasma samples. This assay kit pre-coats a monoclonal antibody specific for OPN onto a microplate to bind OPN in the samples. All blood samples had been preserved at  $-80^{\circ}\text{C}$ . Plasma samples were diluted and the immunoassay was performed according to the manufacturer's instructions.

### Statistical analysis

All data were analyzed using Graph-Pad Prism (version 5.0, El Camino REAL, San Diego, CA) and QuickCalcs software package. Data were expressed as means $\pm$ SD. The normal distribution of continuous variables was verified with the Kolmogorov-Smirnov test, and statistical analyses included the Mann-Whitney test for continuous variables. Linear regression was used to model the relationship between variables. For all the analyses, a *P*-value  $<0.05$  was considered to be statistically significant.

### RESULTS

In the group of patients with AA, thirty-one patients had patchy alopecia ( $<50\%$  scalp involvement) and nine alopecia totalis; the mean time of the onset of the disease was  $4.05\pm 2.37$  months.

In three patients treatment was discontinued for severe acute contact dermatitis after sensitization with DPCP 2%. Thirty-seven patients completed the treatment, showing initial hair regrowth after twelve weeks of DPCP and obtaining a complete recovery after a mean period of 12 months.

Thirty-three patients maintained these satisfactory results for almost twelve months following the discontinuation of DPCP treatment; four patients with patchy AA developed a recurrence three months after DPCP discontinuation.

At baseline, the mean plasma OPN value in patients with AA was significantly higher than in healthy controls ( $85.25\pm 46.48$  ng/mL vs.  $46.60\pm 26.33$  ng/mL; *P*=0.0077) (Figure 1); however, plasma levels of OPN did not correlate with severity and duration of AA.

There was no statistically significant decrease of mean plasma levels of OPN ( $73.59\pm 27.48$  vs  $85.25\pm 46.48$ , *P* $>0.05$ ) after DPCP treatment, although it was significantly higher than in healthy subjects ( $73.59\pm 27.48$  vs.  $46.60\pm 26.33$  ng/mL, *P*=0.0084) (Figure 2).

Additionally, in the subgroup of patients with recurrent AA, relapse was associated with increased plasma levels of OPN, levels of which tended towards those found at T0 (mean:  $76.00\pm 13.67$  ng/mL).

### DISCUSSION

Osteopontin is a multifunctional protein that plays an important role in inflammatory processes inhibiting Th2 response and promoting Th1 cytokine function, with a crucial role in leukocyte migration (7,8).

Our study shows that OPN plasma levels in patients with AA were higher than in healthy controls, and it could be hypothesized that osteopontin has a role in the pathogenesis of alopecia areata, amplifying the inflammatory cascade.

Alopecia areata is considered a Th1-mediated skin disease, for which topical immunotherapy with 2,3-diphenylcyclopropenone (DPCP) has shown to be one of the most effective treatments, even though therapeutic response differs from patient to patient. DPCP is a potent contact sensitizer, whose mechanism of action in AA is not yet completely understood; however, a hypothesis based on cytokine inhibitors proposes a possible interference of DPCP with pre-existing pro-inflammatory cytokines and their continued production by follicular keratinocytes (5,10).

In our case series, patients obtaining complete recovery after DPCP treatment did not show a statistically significant reduction of OPN plasma levels. It could be inferred that DPCP acts primarily on the skin without any significant interference on systemic levels.

However, it is interesting to note that OPN plasma level increases in patients with alopecia areata recurrence after DPCP discontinuation, whereas a statistical significant difference between OPN values has not been found before and after the DPCP treatment. Based on these data, it is not possible assuming OPN as a predictive marker of disease, taking into account the unpredictability and intensity of the relapse of AA (13).

Furthermore, OPN expression has been shown to be linked to vitamin D levels in bone and kidney-stone formation. Currently the primary deficit of vitamin D is considered crucial for the development of autoimmune disease, such as alopecia areata. Thus, we could hypothesize that increased serum levels of OPN could be a primitive facilitating factor in AA pathogenesis, possibly acting together with vitamin D deficiency (14,15).

## CONCLUSION

This is the first pilot study suggesting a possible involvement of osteopontin in AA pathogenesis; further and larger prospective studies are needed in order to achieve in-depth knowledge of the role of OPN in AA.

## References

1. Gregoriou S, Papafragkaki D, Kontochristopoulos G, Rallis E, Kalogeromitros D, Rigopoulos D. Cytokines and other mediators in alopecia areata. *Mediators Inflamm* 2010;2010:928030.
2. Ganzetti G, Campanati A, Offidani A. Alopecia Areata: a possible extraintestinal manifestation of Crohn's disease. *J Crohns Colitis* 2012;6:962-3.
3. Ferretti G, Bacchetti T, Campanati A, Simonetti O, Liberati G, Offidani A. Correlation between lipoprotein(a) and lipid peroxidation in psoriasis: role of the enzyme paraoxonase-1. *Br J Dermatol* 2012;166:204-7
4. Campanati A, Giuliodori K, Ganzetti G, Liberati G, Offidani A. A patient with psoriasis and vitiligo treated with etanercept. *Am J Clin Dermatol* 2010;11 suppl 1:46-8.
5. Alkhalifah A, Alsantali A, Wang E, McElwee KJ, Shapiro J. Alopecia areata update: part II. Treatment. *J Am Acad Dermatol* 2010;62:191-202.
6. Denhardt DT, Noda M, O'Regan AW, Pavlin D, Berman JS. Osteopontin as a means to cope with environmental insults: regulation of inflammation, tissue remodeling, and cell survival. *J Clin Invest* 2001;107:1055-61.
7. Ashkar S, Weber GF, Panoutsakopoulou V, Sanchirico ME, Jansson M, Zawaideh S, *et al.* Eta-1 (osteopontin): an early component of type-1 (cell-mediated) immunity. *Science* 2000;4:860-4.
8. Buback F, Renkl AC, Schulz G, Weiss JM. Osteopontin and the skin: multiple emerging roles in cutaneous biology and pathology. *Exp Dermatol* 2009;18:750-9.
9. World Medical Association Declaration of Helsinki: Ethical Principles for Medical Research Involving Human Patients. Adopted by the 18th WMA General Assembly 1964 and amended by the 29th, 35th, 41st and 48th WMA General Assemblies.
10. Gordon KA, Tosti A. Alopecia: evaluation and treatment. *Clin Cosmet Investig Dermatol* 2011;4:101-6.
11. Ganzetti G, Campanati A, Simonetti O, Cataldi I, Giuliodori K, Offidani AM. Videocapillaroscopic pattern of alopecia areata before and after diphenylcyclopropenone treatment. *Int J Immunopathol Pharmacol* 2011;24:1087-91.
12. Happle R, Hausen BM, Wiesner Menzel L. Diphenylcyclopropenone in the treatment of alopecia areata. *Acta Derm Venereol (Stockh)* 1983;63:49-52.
13. D'Ovidio R. Koebner phenomenon in alopecia areata: rapid appearance after Trichogram. Implications for the pathogenesis and therapy. *G Ital Dermatol Venereol* 2013;148: 225-9.
14. Schaubert J, Gallo RL. The vitamin D pathway: a new target for control of the skin's immune response? *Exp Dermatol* 2008;17: 633-9.
15. D'Ovidio R, Vessio M, d'Ovidio F. Reduced level of 25-hydroxyvitamin D in chronic/relapsing Alopecia Areata. *Dermatol Endocrinol* 2013;5:36-7.