

## BETA STIFFNESS INDEX BY THREE-DIMENSIONAL ULTRASOUND

Miljenka-Jelena Jurašić<sup>1</sup>, Arijana Lovrenčić-Huzjan<sup>1</sup>, Rada Šarac<sup>2</sup> and Vida Demarin<sup>1</sup>

<sup>1</sup>University Department of Neurology, Sestre milosrdnice University Hospital;

<sup>2</sup>Special Hospital for Pulmonary Diseases, Zagreb, Croatia

**SUMMARY** – Beta stiffness index is the most common marker for assessment of subclinical atherosclerosis. The aim of the study was to explore the new technique of three-dimensional ultrasound for carotid stiffness evaluation. This pilot investigation was conducted in ten healthy volunteers. Measurements were performed in common carotid artery (CCA) on an Aloka 5500-SSD Prosound ultrasound platform in B and M modes. Data were collected freehandedly over 10 seconds and postprocessing analysis was performed using TomTec Imaging software. Beta indexes were mathematically computed and statistically evaluated by use of nonparametric statistics for two related samples. There were nine women and one man aged  $39.3 \pm 9.2$  years. There was one borderline hypertensive subject and four subjects were active smokers. The mean body mass index was  $23.85 \pm 5.83$  kg/m<sup>2</sup>, and mean intima-media thickness on CCA bilaterally  $0.42 \pm 0.06$  mm. Statistically, comparison between conventional and three-dimensional ultrasound corroborated consistency in the left CCA ( $p > 0.05$ ). This investigation proved that three-dimensional ultrasound could be used as a complementary method for evaluation of subclinical carotid atherosclerosis, with a greater sensitivity in the left CCA.

**Key words:** *Arteries – physiology; Carotid arteries – ultrasonography; Carotid artery diseases – ultrasonography; Imaging, three-dimensional; Atherosclerosis – diagnosis; Elasticity*

### Introduction

Vascular disorders are the leading cause of death in Croatia<sup>1</sup>. Macroangiopathic ischemic stroke is rather common, especially in active men<sup>2</sup>. Therefore, it is important to identify early stages of vascular disease, even at subclinical level, before the pathologic changes have become definite and irreversible. A recent study indicates that exposure to vascular risk factors at an early age (teen-age) could be responsible for vascular changes that will predetermine development of atherosclerosis in adulthood<sup>3</sup>. New and improved vascular imaging techniques are needed to advance diagnostic sensitivity for subclinical stages of atherosclerosis. The most suitable technique for this type of analysis is vascular

ultrasound with its advantage of direct morphological vessel examination for overt or subclinical lesions. Ultrasound is noninvasive, inexpensive and suitable for bed-side evaluation<sup>4</sup>. Subclinical atherosclerosis on carotid arteries can be detected by measurement of the intima-media thickness (IMT), quantification of distensibility, and number of plaques<sup>5</sup>. Among the potential means for distensibility evaluation, beta stiffness index is one of the most commonly used markers<sup>6</sup>. The advantage of beta index exploration lies in its derivation from regional diameter and pulse pressure change that is thought to precede hypertension, pulse pressure also being identified as an independent risk factor for future vascular events<sup>7</sup>.

In the last decade, three-dimensional ultrasound has been developed and its potential use in clinical examination of carotid arteries is currently under evaluation in a number of studies<sup>8-11</sup>. So far, it has been used for quantifiable atherosclerotic changes, i.e. identification of plaque volume, plaque irregularity, and plaque pro-

Correspondence to: *Miljenka-Jelena Jurašić, MD, MS*, University Department of Neurology, Sestre milosrdnice University Hospital, Vinogradska c. 29, HR-10000 Zagreb, Croatia  
E-mail: mkesic@inet.hr

Received July 25, 2005, accepted august 16, 2005

gression<sup>8-10,12</sup>. However, recorded wall displacements during cardiac cycles in the common carotid artery (CCA) imply the possible subclinical application<sup>13</sup>.

The aim of this study was to explore the potential use of three-dimensional ultrasound using beta stiffness index for evaluation of CCA physiology.

## Subjects and Methods

### Methods

The study was performed in ten healthy volunteers. Inclusion criteria were normotension and normolipoproteinemia. Exclusion criteria were established heart disease, diabetes mellitus, evident early atherosclerotic changes (IMT in the distal wall of CCA >0.8 mm), prior stroke or transient ischemic attack (TIA), and alcoholism.

Upon taking history data, blood pressure measurements were repeated to confirm the allowed blood pressure values. Body mass index (BMI) was calculated. The subjects were asked whether they were smokers.

The subjects underwent ultrasound examination on an Aloka ProSound SSD-5500 (Aloka Co., Ltd., Tokyo, Japan) using high-resolution 10 MHz linear probe. All measurements were performed in supine position with head elevation by 45° and side tilt by 30° to the right and then to the left. Conventional B mode examination was performed first and IMT was measured at 1.5 cm proximally to the flow divider on the distal wall of the CCA bilaterally. Following B mode examination, M mode examination was performed on the CCA at 1.5 cm proximally to the flow divider on the best still screen image. This image is composed of systolic and diastolic wall displacements of about 5 cardiac cycles on an average. The near and far arterial walls are visualized as two

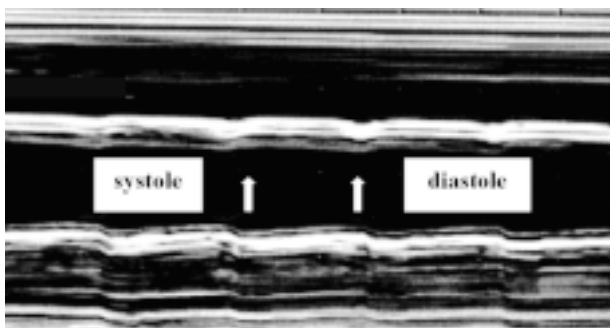


Fig. 1. M-mode presentation of the right common carotid artery.

hyperechoic lines, the inner line representing the border between the vessel lumen and the IMT, and the outer line representing the border between the IMT and the adventitia. IMT measurements on the far wall in systole and diastole were performed first, then luminal diameter in systole and diastole (distance between the two lumen-intima interfaces), and at last interadventitial diameter in systole and diastole (distance between the two media-adventitia interfaces) (Fig. 1). Each of the mentioned measurements was performed over three cardiac cycles by a single investigator, and results were expressed as arithmetic mean.

Upon completion of two-dimensional measurements, three-dimensional analysis was done by use of TomTec Imaging Systems software (Munich, Germany). For these measurements, the transmitter had to be fixed to the ultrasound probe and the receiver placed maximally 50 cm apart. The direct effect of cardiac motion on the distal CCA bilaterally is not plausible because distal carotid arteries are at least 30 cm away from the heart. Additionally, the principal cause of arterial diameter change is the action of pulse pressure applied to the arterial wall. Finally, the number of countable systolic/diastolic cycles on postprocessed three-dimensional images best fitted that of the subject's heart rate. Therefore, ECG synchronization was not performed. The position was the same as in two-dimensional evaluation and data were recorded with a

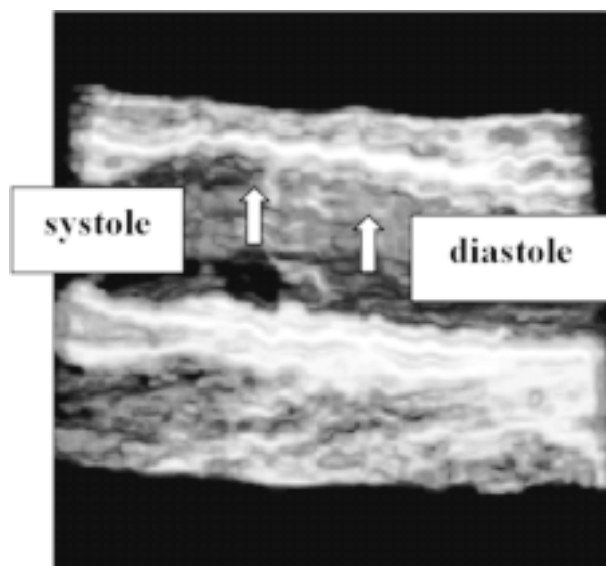


Fig. 2. Three-dimensional reconstruction of the right common carotid artery.

single freehanded transverse sweep lasting 10 seconds for 3 cm over the CCA in B mode. Postprocessed images were examined on screen as rotated three-dimensional structures in order to obtain the best view. Flow divider was determined and measurements were performed: luminal diameter in systole and diastole, and interadventitial diameter in systole and diastole. Each of the measurements was performed over three consecutive cardiac cycles by a single investigator and the results were expressed as arithmetic mean (Fig. 2).

Exploration of diameter change in systole and diastole is explained by luminal and interadventitial circumferential arterial strain (CAS) and beta indexes. Two types of beta indexes were used: luminal beta index was based on luminal diameter measurements and interadventitial beta index (IS) on interadventitial diameter measurements (IS).

### Ethics

Informed consent was obtained before entering the study and approved by the Hospital Ethics Committee. All procedures were performed in accordance with institutional guidelines.

### Statistics

Nonparametric statistics for two related samples was used for evaluation. For statistical analysis a SPSS package (version 8.0 for Windows) was used; alpha <0.05.

*Table 1. Descriptive statistics of beta indexes measured by conventional ultrasound and three-dimensional ultrasound proving all investigated values were within the normal range for the general population*

Beta index	CCA	Mean	SD	Minimum	Maximum
Conventional ultrasound					
Luminal	right	3.47	0.85	2.30	4.78
	left	5.37	1.61	2.36	7.23
Interadventitial	right	4.78	1.47	2.92	8.05
	left	5.91	2.77	2.18	10.73
Three-dimensional ultrasound					
Luminal	right	6.29	2.78	2.30	12.55
	left	6.48	4.54	2.67	15.30
Interadventitial	right	8.53	4.88	1.82	18.4
	left	6.53	2.79	3.33	11.73

CCA=common carotid artery

## Results

There were nine women and one man, mean age  $36.3 \pm 9.2$  years. There was one subject with borderline hypertension. The mean systolic and diastolic blood pressure values were  $113 \pm 11.83$  mm Hg and  $71 \pm 8.34$  mm Hg, respectively, with a mean pulse pressure value of  $42 \pm 6.32$  mm Hg. Four subjects were active smokers, with a pack-year range of 5-30. The mean BMI value was  $23.85 \pm 5.83$  kg/m<sup>2</sup>. The mean IMT value was  $0.41 \pm 0.06$  mm in the right CCA and  $0.41 \pm 0.06$  mm in the left CCA. Luminal CAS values were 0.11-0.20, and

*Table 2. p-values (nonparametric statistics) of CAS and beta index explored with conventional ultrasound and three-dimensional ultrasound showing group differences in the right CCA*

	Luminal		Interadventitial	
	right	left	right	left
CAS and 3D	0.04	0.96	0.15	0.36
Beta index and 3D	0.01	0.58	0.02	0.45

CAS = circumferential arterial strain; CCA = common carotid artery

interadventitial CAS values 0.04-0.21 using conventional B mode ultrasound. Luminal CAS values were 0.04-0.21 and interadventitial CAS values 0.02-0.25 using three-dimensional ultrasound. Beta indexes are shown in Table 1. The values show some differences between conventional ultrasound and three-dimensional ultrasound; p-value comparison between the pair of results is presented in Table 2. Statistically, comparison between conventional and three-dimensional ultrasound proved difference in almost all values observed in the right CCA but corroborated consistency in the left CCA.

## Discussion

Our study demonstrated consistency in measurement using both types of ultrasound examination placing all individuals into the group with normal values of beta indexes. In the left CCA, there was no statistical difference between the groups, whereas in the right CCA a statistical difference was noted in three measurements. The possible explanation of such results might lie in the manner of ultrasound ex-

amination: the subject is supine and facing the examiner so the proper angle of insonation is easier on the left CCA. However, it may be that there is a difference of beta indexes between some population subgroups, and such evaluation would require additional studies.

The advantage of three-dimensional vessel analysis is the possibility of the respective arterial segment examination from different angles and from within the lumen providing greater spatial resolution. The sensitivity and specificity comparison between the conventional mode of examination and three-dimensional reconstruction on carotid arteries has so far proved a high level of consistency ( $r=0.982$ )<sup>8,9</sup>. Comparison with magnetic resonance imaging was also satisfactory offering transaxial resolution of 5 mm, longitudinal resolution of up to 10 mm, and rotational resolution of up to 40°<sup>14</sup>. Freehanded arterial sweep is simple for use and allows perpendicular tracking of the desired arterial segment. Current problems in arterial wall analysis are the lack of possibility to properly differentiate between periarterial and intra-arterial tissue, so additional efforts in image defining might in the future decrease the variability of reading and present subjectivity.

Disadvantages of three-dimensional ultrasound data collection are the need of high operator's skill and motion artifacts caused by cardiac motion, hand movement, or respiration. Using probe holders can diminish hand movement. Respiration artifacts are probably not important since over a 10-second period (data acquisition time) there is usually less than two complete breathing cycles. Our conclusion was that ECG synchronization was not important in vessel wall analysis since the number of recorded complete cardiac cycles best fitted the number of the subjects' heart rates.

Three-dimensional arterial wall analysis was until now performed in biotechnical laboratories instead of modeling studies, and proved to be reproducible providing satisfactory results<sup>15</sup>. A study performed in this laboratory showing wall displacement during cardiac cycles in the CCA induced further investigation using beta index evaluation<sup>13</sup>. This was supported by the need to utilize the measurement of IMT, already proven as an atherosclerotic marker and possible predictor of cerebral vessel involvement<sup>16</sup>. However, IMT measurement alone does not determine subclinical atherosclerosis; therefore, additional evaluation of arterial distensibility involving wall thickness or the number of plaques is needed. Additionally, the recommendation for arterial stiffness exploration advises measuring of

purely physical dimensions<sup>6</sup>. The most prominent risk factor for arterial structural change is age; age increases diameter change and systolic blood pressure values, and decreases diastolic blood pressure values. Distensibility decrease is associated with the loss of self-correcting mechanisms that protect arterial integrity. Thus, recognizing the change in distensibility could offer a window to reversible arterial damage where proper correction of specific risk factors would instigate reintegration of the arterial system. Measurements of CAS are inversely related to distensibility change, i.e. the greater the strain, the smaller the distensibility<sup>6</sup>. The results of CAS and interadventitial beta indexes in this study are consistent with previous literature data<sup>17</sup>. To our knowledge, there are no studies using luminal beta index, and no standards have yet been set. The results from this study prove that LS is less sensitive for atherosclerosis, most likely because of diameter change with IMT exclusion. Greater concordance between the conventional ultrasound and three-dimensional ultrasound investigation was observed in IS, as expected. Greater precision in interface selection and/or the importance of carotid wall work might be explanatory.

Three-dimensional ultrasound beta index calculation was proved to be a valid method in the evaluation of arterial wall physiology. Studies in a greater number of subjects are needed to evaluate vessel wall pathology and to set respective standards.

### Acknowledgments

*This study was performed as part of the scientific project No. 0134015 Three-Dimensional Ultrasound and Functional TCD in Evaluation of Cerebral Circulation, supported by the Croatian Ministry of Science, Education and Sports. We thank all the colleagues who have contributed to this work in many different areas, especially all staff of the Neurovascular Laboratory of our Department, and the volunteers who participated in the study.*

### References

1. DEMARIN V. Stroke – a challenge in the diagnosis and therapy. *Acta Med Croatica* 2001;55:145-8.
2. LOVRENČIĆ-HUZJAN A, BOSNAR M, HUZJAN R, DEMARIN V. Frequency of different risk factors for ischemic stroke. *Acta Clin Croat* 1999;38:159-63.
3. RAITAKARI OT, JOUNALA M, KAHONEN M, TAITTONEN L, LAITINEN T, MAKI-TORKKO N, JARVISALO MJ, UHARI M, JOKINEN E, RONNEMAA T, AKERBLUM HK, VIKARI JS.

- Cardiovascular risk factors in childhood and carotid artery intima-media thickness in adulthood: the Cardiovascular Risk in Young Finns Study. *JAMA* 2003;290:2277-83.
4. WESSELS T, HARRER JU, SETTER S, MULL M, KLOTZSCH C. Three-dimensional assessment of extracranial Doppler sonography in carotid artery stenosis compared with digital subtraction angiography. *Stroke* 2004;35:1847-51.
  5. XAVIERAR, QURESHI A, KIRMANI JF, YAHIAAM, BAKSHI R. Neuroimaging of stroke: a review. *South Med J* 2003;96:367-79.
  6. O'ROURKE MF, STAESSEN JA, VLACHOPULOS C, DUPREZ D, PLANTE GE. Clinical applications of arterial stiffness; definitions and reference values. *Am J Hypertens* 2002;15:426-44.
  7. LAKATTA EG, LEVY D. Arterial and cardiac aging: major shareholders in cardiovascular disease enterprises. Part I: Aging arteries: "set up" for vascular disease. *Circulation* 2003;107:139-46.
  8. FENSTERA, LANDRYA, DOWNEY DB, HEGELE RA, SPENCE JD. 3D ultrasound imaging of the carotid arteries. *Curr Drug Targets Cardiovasc Haematol Disord* 2004;4:161-75.
  9. KEBERLE M, JANETT M, BEISSERT M, JAHNS R, HEARTEN R, HAHN D. Three-dimensional power Doppler sonography in screening for carotid artery disease. *J Clin Ultrasound* 2000;28:441-51.
  10. KESIĆ MJ, LOVRENČIĆ-HUZJAN A, ZAVOREO HUSTA I, DEMARIN V. Three dimensional ultrasound of the plaque ulceration. *Cerebrovasc Dis* 2002;13 (Suppl 4):42.
  11. LOVRENČIĆ-HUZJAN A, KESIĆ MJ, ROJE-BEDEKOVIĆ M, LISAK M, ZAVOREO-HUSTA I, DEMARIN V. Three-dimensional ultrasound of the Willis circle and the vertebrobasilar system. *Eur J Neurol* 2002;9 (Suppl 2):217.
  12. LANDRY A, SPENCE JD, FENSTER A. Measurement of carotid plaque volume by 3-dimensional ultrasound. *Stroke* 2004;35:864-9.
  13. KESIĆ M, LOVRENČIĆ-HUZJAN A, VUKOVIĆ V, MOROVIĆ S, ZAVOREO I, LISAK M, DEMARIN V. Comparison of arterial stiffness: results obtained with M mode ultrasound analysis and three-dimensional ultrasound. *Cerebrovasc Dis* 2003;16 (Suppl 2):1.
  14. SLOMKA PJ, MANDEL J, DOWNEY D, FENSTERA. Evaluation of voxel based registration of 3D power Doppler ultrasound and 3-D magnetic resonance angiographic images of carotid arteries. *Ultrasound Med Biol* 2001;27:945-55.
  15. AUGST AD, BARRATT DC, HUGHES AD, GLOR FP, McG THOM SA, XU XY. Accuracy and reproducibility of CDF predicted wall shear stress using 3D ultrasound images. *J Biomech Eng* 2003;125:218-22.
  16. TOUBOUL P-J, ELBAZ A, KOLLER C, LUCAS K, ADRAI V, CHEDRU F, AMARENCO P. Common carotid artery intima-media thickness and brain infarction. *Circulation* 2000;102:313-8.
  17. NIKI K, SUGAWARA M, CHANG D, HARADA A, OKADA T, SAKAI R, UCHIDA K, TANAKA R, MUMFORD CE. A new noninvasive measurement system for wave intensity: evaluation of carotid arterial wave intensity and reproducibility. *Heart Vessels* 2002;17:12-21.

#### Sažetak

### BETA INDEKS ŽILNE KRUTOSTI POMOĆU TRODIMENZIJSKOG ULTRAZVUKA

*M-J. Jurašić, A. Lovrenčić-Huzjan, R. Šarac i V. Demarin*

Beta indeks krutosti jedan je od najčešće upotrebljivanih za opisivanje pretkliničke ateroskleroze. Cilj ovoga istraživanja bio je utvrditi je li moguće upotrijebiti novu metodu trodimenzijskog ultrazvuka karotidnih arterija za ispitivanje žilne krutosti. Ovo probno istraživanje provedeno je u 10 zdravih dobrovoljaca na ultrazvučnom uređaju Aloka 5500-SSD Prosound uporabom B i M prikaza na zajedničkoj karotidnoj arteriji (ACC). Za trodimenzijsku analizu rabila se je metoda "slobodne ruke" tijekom 10 sekunda uz pomoć programske potpore TomTec Imaging. Beta indeksi žilne krutosti izračunati su matematičkim putem, za analizu se je rabila neparametrijska statistika s dva povezana uzorka. U ispitivanje je bilo uključeno 9 žena i 1 muškarac prosječne dobi  $39,3 \pm 9,2$  godine. Jedan ispitanik je imao granično povišene vrijednosti krvnoga tlaka, a 4 ispitanika su bili aktivni pušači. Srednji indeks tjelesne težine bio je  $23,85 \pm 5,83$  kg/m<sup>2</sup>, a srednja vrijednost intimalnog dijela stijenke ACC obostrano  $0,42 \pm 0,06$  mm. Statističkom usporedbom vrijednosti beta indeksa krutosti dobiveni su podudarajući rezultati u lijevoj ACC ( $p > 0,05$ ). Istraživanje je potvrdilo da se trodimenzijski ultrazvuk može rabiti kao komplementarna metoda za ispitivanje pretkliničke karotidne ateroskleroze s većom osjetljivošću na lijevoj ACC.

*Ključne riječi: Arterije – fiziologija; Karotidne arterije – ultrasonografija; Bolesti karotidnih arterija – ultrasonografija; Slikovno prikazivanje, trodimenzijsko; Ateroskleroza – dijagnostika; Elastičnost*