

UNIPORTAL VIDEO-ASSISTED THORACIC SURGERY FOR PULMONARY HAMARTOMA: CASE REPORT

Željko Djaković and Zoran Janevski

Jordanovac University Department of Thoracic Surgery, Zagreb University Hospital Center, Zagreb, Croatia

SUMMARY – Pulmonary hamartoma is the most common benign tumor of the lung. It accounts for 77% of all benign lung tumors but less than 1% of all lung tumors. Malignant alteration is extremely rare. Surgical removal is therapy of choice. Uniportal video-assisted thoracic surgery is an easy-to-learn variant of video-assisted thoracic surgery. The approach is very similar to classic thoracotomy. Instruments for both classic and video-assisted thoracic surgery can be combined. A case is presented of a 44-year-old female patient with pulmonary hamartoma treated by uniportal video-assisted thoracic surgery as a new method used for the first time at our department.

Key words: *Lung neoplasms; Lung; Thoracic surgery, video-assisted; Thoracotomy; Minimally invasive surgical procedures*

Introduction

Less than 1% of lung tumors are benign. They can originate from any type of cells of the tracheobronchial tree. The most common benign tumor of the lung is hamartoma. It accounts for 77% of all benign lung tumors. Hamartoma grows slowly, affects more often male (3:1) and older age individuals. Origin of the tumor is peribronchial mesenchymal tissue. Typical localization is periphery of the lung. In 3%-20% of patients, location of the tumor can be endobronchial. In most cases, the tumor causes no symptoms. On radiography, it is presented as a peripheral nodule of less than 4 cm in diameter, rarely larger. The treatment of choice is surgical extirpation, usually by thoracotomy¹.

Uniportal video-assisted thoracic surgery (VATS) is an alternative to classic thoracic surgery but also to multiple-port VATS. Multiple-port VATS forces the surgeons to an unnatural eye to hand coordination compared to what they are used to in open surgery. This is the major advantage of this method².

Correspondence to: Željko Djaković, PhD, Jordanovac University Department of Thoracic Surgery, Zagreb University Hospital Center, Jordanovac 104, HR-10000 Zagreb, Croatia
E-mail: zeljkodjakovic@yahoo.com

Received September 24, 2014, accepted November 20, 2015

Case Report

We present a case of a 44-year-old female patient with pulmonary hamartoma treated by uniportal VATS. A pulmonary nodule in the upper right lobe was detected incidentally on routine chest x-ray (Fig. 1). All the characteristics of this nodule were typical for hamartoma and localization was in the fissure. Less

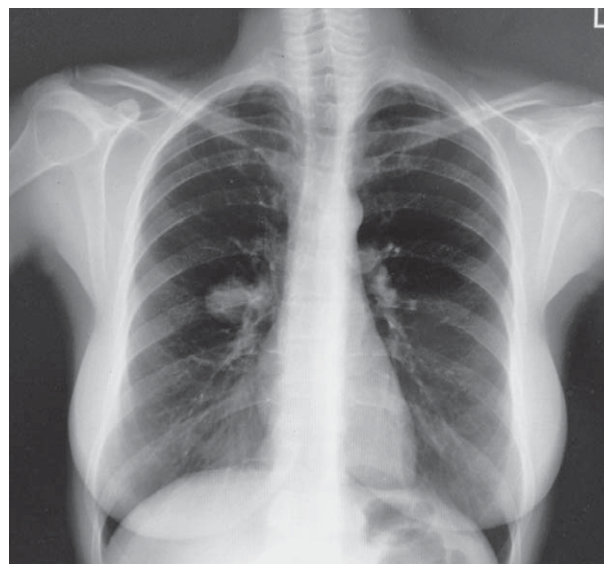

Fig. 1. Chest x-ray showing hamartoma of the right lung.

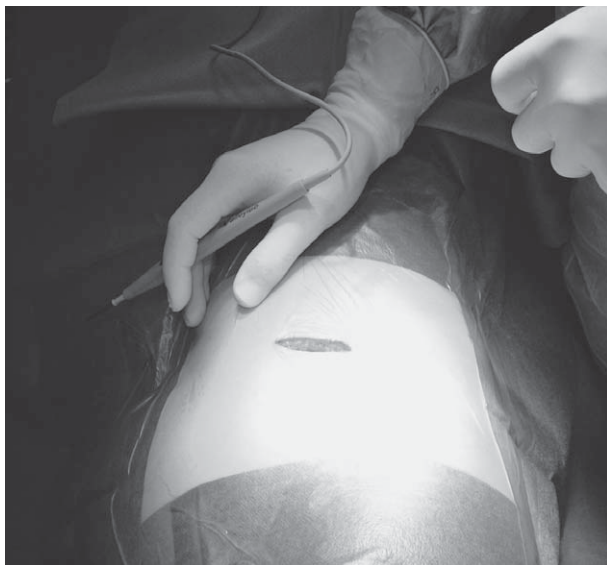

Fig. 2. Incision on the right thorax.

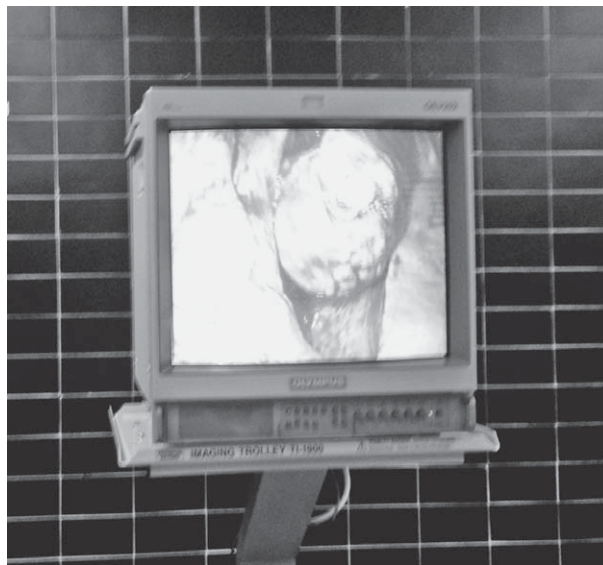

Fig. 4. Visualization of the tumor.

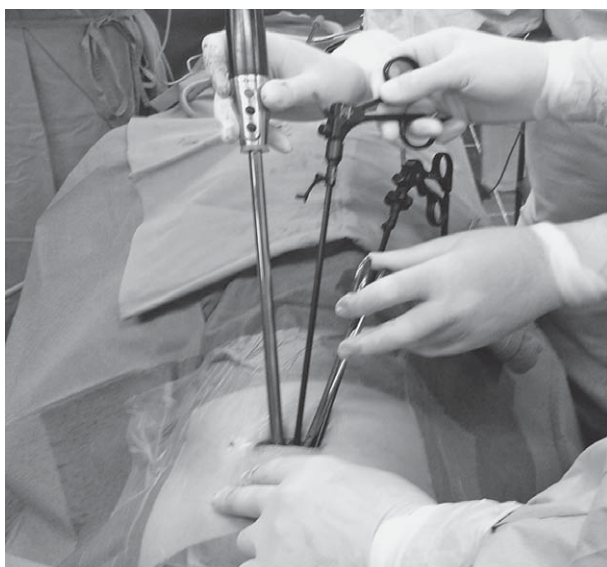


Fig. 3. Placement of the thoracoscope and instruments.

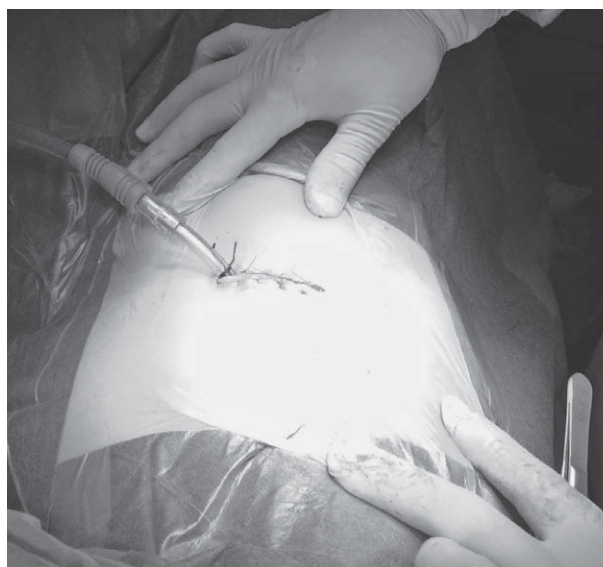


Fig. 5. Placement of the chest tube in the incision.

than 5 cm incision was performed (Fig. 2) and used for placement of the videothoracoscope and all instruments (Fig. 3). The tumor was visualized and extirpated using classical instruments and instruments for VATS (Fig. 4). The chest tube was placed through the incision, so there was no need for additional incisions (Fig. 5). Postoperative chest x-ray showed good reexpansion of the lungs (Fig. 6). The chest tube was removed after two days. Follow up at three weeks revealed normal chest x-ray and very good aesthetics with a scar less than 5 cm in length (Fig. 7).

Discussion

Multiple-port VATS forces the surgeons to an unnatural eye to hand coordination compared to what they are used to in open surgery². Uniportal VATS offers the same perspective as in open surgery but on the screen. As shown in this case report, it is feasible for small peripheral lesions without the need for long training and adjustment. Nowadays, uniportal VATS is used for lung biopsies and as the gold standard to achieve diagnosis in undetermined interstitial lung

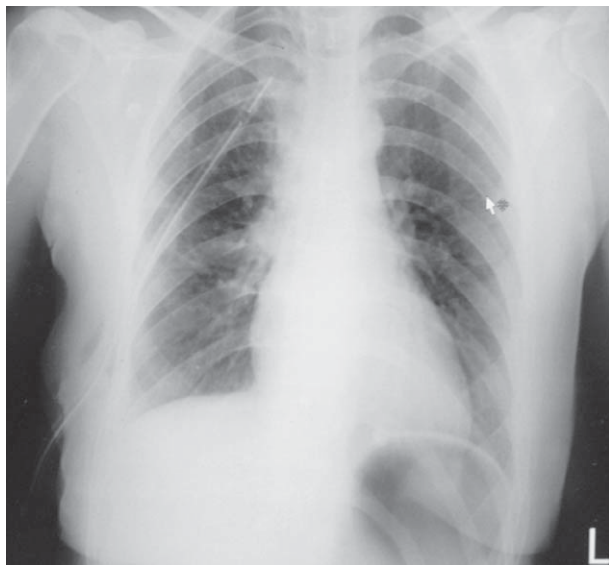

Fig. 6. Postoperative chest x-ray.

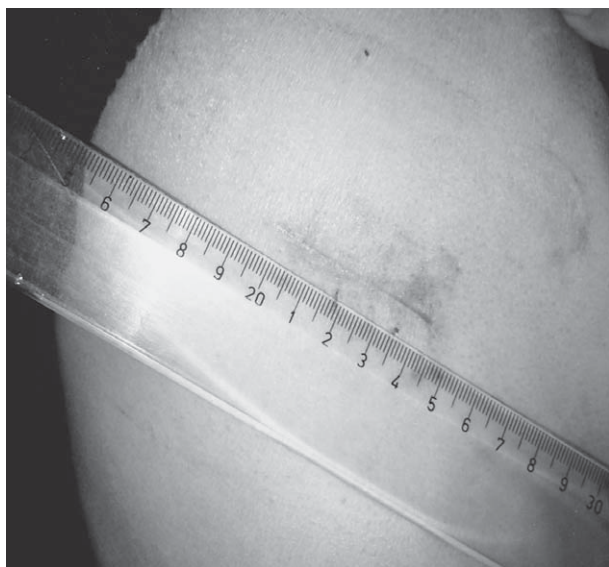


Fig. 7. Postoperative scar after 4 weeks.

disease³. Micro-invasive thoracic surgery, especially VATS, has become the mainstream of lung cancer resections^{4,5}. Even more complicated procedures in thoracic surgery such as bronchovascular reconstructions and resections of the advanced stages of non-small cell lung cancer can be done by uniportal VATS⁶⁻¹¹. This method is easy-to-learn, offers known conditions to any thoracic surgeon, and has no limitations for extensive surgical procedures. The less invasive approach

is well accepted by the patient and shortens hospitalization.

References

1. Slobodnjak Z. Pluća [Lungs]. In: Šoša T, Sutlić Ž, Stanec Z, Tonković I, *et al.*, editors. Kirurgija [Surgery]. Zagreb: Naklada Ljevak; 2007. p. 622-36. (in Croatian)
2. Rocco G. VATS and uniportal VATS: a glimpse into the future. *J Thorac Dis.* 2013;5(S3):S174. <http://dx.doi.org/10.3978/j.issn.2072-1439.2013.07.05>.
3. Ambrogi V, Mineo TC. VATS biopsy for undetermined interstitial lung disease under non-general anesthesia: comparison between uniportal approach under intercostal block *vs.* three-ports in epidural anesthesia. *J Thorac Dis.* 2014;6(7):888-95. <http://dx.doi.org/10.3978/j.issn.2072-1439.2014.07.06>.
4. Liu C, Lui L. [Uniportal VATS: a sublimation of micro-invasive lung cancer resection]. *Zhongguo Fei Ai Za Zhi.* 2014;17(7):527-30. (in Chinese) <http://dx.doi.org/10.3779/j.issn.1009-3419.2014.07.04>.
5. Gonzales-Rivas D, Fernandez R, de la Torre M, Rodriguez JL, Fontan L, Molina F. Single-port thoracoscopic lobectomy in a nonintubated patient: the least invasive procedure for major lung resection? *Interact Cardiovasc Thorac Surg.* 2014;19(4):552-5. <http://dx.doi.org/10.1093/icvts/ivu209>.
6. Gonzales-Rivas D, Fieira E, de la Torre M, Delgado M. Bronchovascular right upper lobe reconstruction by uniportal video-assisted thoracoscopic surgery. *J Thorac Dis.* 2014;6(6):861-3. <http://dx.doi.org/10.3978/j.issn.2072-1439.2014.06.27>.
7. Gonzales-Rivas D, Fieira E, Delgado M, Mendez L, Fernandez R, de la Torre M. Is uniportal thoracoscopic surgery a feasible approach for advanced stages of non-small cell lung cancer? *J Thorac Dis.* 2014;6(6):641-8. <http://dx.doi.org/10.3978/j.issn.2072-1439.2014.05.17>.
8. Holbek BL, Horsleben Petersen R, Kehlet H, Hansen HJ. Fast-track video-assisted thoracoscopic surgery: Future challenges. *Scand Cardiovasc J.* 2016;50(2):78-82. <http://dx.doi.org/10.3109/14017431.2015.1114665>.
9. Wu CF, Diego GR, Wen CT, Liu YH, Wu YC, Chao YK, Heish MJ, Wu CY, Chen WH. Single-port video-assisted thoracoscopic mediastinal tumour resection. *Interact Cardiovasc Thorac Surg.* 2015;21(5):644-9. <http://dx.doi.org/10.1093/icvts/ivv224>.
10. Ismail NA, Elsaegh M, Dunning J. Novel techniques in Video-assisted thoracic surgery (VATS) lobectomy. *Surg Technol Int.* 2015;26:206-9.
11. Gonzalez-Rivas D, Bonome C2, Fieira E, Aymerich H4, Fernandez R, Delgado M, Mendez L, de la Torre M. Non-intubated video-assisted thoracoscopic lung resections: the future of thoracic surgery? *Eur J Cardiothorac Surg.* 2016;49(3):721-31. <http://dx.doi.org/10.1093/ejcts/ezv136>.

Sažetak

UNIportalna VIDEO-POTPOMOgnuta TORAKALNA OPERACIJA PLUĆNOG HAMARTOMA:
PRIKAZ SLUČAJA

Ž. Djaković i Z. Janevski

Hamartom pluća je najčešći benigni tumor pluća. Predstavlja 77% svih dobroćudnih tumora pluća, ali manje od 1% svih plućnih tumora. Maligna alteracija je izrazito rijetka. Metoda izbora za liječenje hamartoma pluća je kirurška ekstirpacija. Uniportalna video-potpomognuta torakalna kirurgija je varijanta video-potpomognute torakalne kirurgije koja se brže svladava te omogućava kombiniranje postojećih klasičnih torakokirurških instrumenata i instrumenata za video-potpomognutu torakalnu kirurgiju. Prikazuje se slučaj bolesnice u dobi od 44 godine s hamartomom pluća koja je operirana metodom uniportalne video-potpomognute torakalne kirurgije, prvi put primijenjene u našoj klinici.

Ključne riječi: *Plućni tumori; Pluća; Torakalna kirurgija, video-potpomognuta; Torakotomija; Minimalno invazivni kirurški zahvati*