

# SPINAL DUMBBELL EPIDURAL HEMANGIOMA: TWO STAGE/SAME SITTING/SAME POSITION POSTERIOR MICROSURGICAL AND TRANSTHORACIC ENDOSCOPIC RESECTION – CASE REPORT AND REVIEW OF THE LITERATURE

Mirza Pojskić<sup>1</sup>, Blazej Zbytek<sup>2</sup>, Christopher J. Mutrie<sup>3</sup> and Kenan I. Arnautović<sup>4</sup>

<sup>1</sup>Department of Neurosurgery, University of Marburg, Marburg, Germany;

<sup>2</sup>Pathology Group of Midsouth, Memphis, TN, USA; <sup>3</sup>Baptist Memorial Group Thoracic Surgery, Memphis, TN, USA; <sup>4</sup>Semmes Murphey Neurologic & Spine Institute and Department of Neurosurgery, University of Tennessee Health Science Center, Memphis, TN, USA

**SUMMARY** – Spinal dumbbell tumors are defined by a narrowing at the point where they penetrate the intervertebral foramina or dura mater, assuming an hourglass or dumbbell shape. Dumbbell-shaped spinal hemangiomas are extremely rare. We describe a dumbbell spinal tumor (epidural cavernous hemangioma) resected by a 2-stage single-sitting combined approach. We also conduct a substantial literature review of the subject. We present a case of a 78-year-old male who was found to have a homogeneously enhancing, dumbbell-shaped, intraspinal, extradural tumor mass extending into the left chest cavity. The tumor was resected with a single-sitting 2-stage posterior technique: a microsurgical approach, followed by endoscopic resection *via* a thoracoscopic approach. There are several reports in the literature on the combined approach for dumbbell tumors of the spinal cord. Our case is the first to describe 2-stage combined surgery in 1 sitting for dumbbell hemangioma with the patient in the lateral decubitus position for the thoracoscopic part of the surgery; and the use of a fat pad, which was applied in the neuroforamen *via* the posterior route, as a marker for resection during the transthoracic procedure.

**Key words:** *Spine; Dumbbell tumor, epidural; Hemangioma; Microsurgery; Endoscopy; Thoracoscopic approach*

## Introduction

Spinal dumbbell tumors were first defined by Heuer in 1929 as a group of tumors arising along the spine that are constricted at the point where they penetrate the intervertebral foramina or dura mater, assuming an hourglass or dumbbell shape<sup>1</sup>. Non-schwannoma/non-neurofibroma dumbbell tumors of the spinal cord

include 28 different pathological entities, such as vascular lesions (hemangiomas and hemangioblastomas), meningiomas, and various rare lesions described in the literature as single case reports<sup>2-30</sup>.

Hemangiomas are congenital vascular malformations whose pathologies are considered to be hamartomatous malformations<sup>15</sup>. Spinal epidural hemangiomas (SEHs) can be divided into 2 types: epidural hemangiomas of vertebral origin, and primary epidural space hemangiomas<sup>17,24,27</sup>. SEHs account for 4% of all spinal epidural tumors, mostly occurring as primary lesions in the vertebral bone<sup>2</sup>. According to a study by Esene *et al.*<sup>14</sup>, there are approximately 100 reported

Correspondence to: Kenan Arnautović, MD, PhD, Semmes Murphey Neurologic & Spine Institute, Department of Neurosurgery, University of Tennessee Health Science Center, 6325 Humphreys Blvd, Memphis, TN 38120, USA  
E-mail: kenanarnaut@yahoo.com

Received June 18, 2018, accepted November 20, 2018

Table 1. Literature review of dumbbell spinal epidural hemangiomas

Author and year	Age (yrs) /Sex	Location level	Presentation	Surgical technique
Rovira <i>et al.</i> 1999 <sup>84</sup>	51/F	L3/4	Sciatica, no deficits	Posterior approach (laminectomy)
Padovani <i>et al.</i> 1982 <sup>85</sup>	75/M	T3-6	Gait disturbances	Posterior approach (laminectomy, partial removal)
Franz <i>et al.</i> 1987 <sup>86</sup>	23/M	T3/4	Spastic paraplegia	Posterior approach (laminectomy, total removal)
Feider <i>et al.</i> 1991 <sup>15</sup>	50 /M	L3/4	Sciatica, no deficits	Posterior approach (laminectomy, total removal)
Morioka <i>et al.</i> 1986 <sup>24</sup>	50/M	T2/3	Hypoesthesia below chest	Combined posterior approach (laminectomy) with thoracotomy
Fukushima <i>et al.</i> 1987 <sup>87</sup>	54/M	T7/8	Spastic paraparesis	Posterior approach (laminectomy, total removal)
Haimes <i>et al.</i> 1991 <sup>88</sup>	46/M	T3/4	Hypoesthesia of bilateral feet	Combined posterior approach (laminectomy) with thoracotomy
Lanotte <i>et al.</i> 1994 <sup>89</sup>	27/F	T1/2	Paresthesia of lower extremities	Posterior approach (arthrolaminectomy)
Harrington <i>et al.</i> 1995 <sup>90</sup>	37/F	L3/4	Leg numbness and pain	Posterior approach (hemilaminectomy, total removal)
Bavbek <i>et al.</i> 1997 <sup>91</sup>	Not specified	C8	Not specified	Not specified
Carlier <i>et al.</i> 2000 <sup>92</sup>	36/M	Cervical spine	Acute weakness in right upper limb	Posterior approach
Saringer <i>et al.</i> 2001 <sup>27</sup>	56/M	T3/4	Chronic neuralgia	Posterior approach
Badinand <i>et al.</i> 2003 <sup>59</sup>	40/F	T3/4	Gait disturbances, sphincter problems	Posterior approach (laminectomy), subtotal removal
Hara <i>et al.</i> 2006 <sup>93</sup>	19/M	T12/L1	Low back pain	Posterior approach
Kang <i>et al.</i> 2006 <sup>52</sup>	56/M	T3/4	Chest wall pain	Posterior approach (laminectomy), partial resection
Iglesias <i>et al.</i> 2008 <sup>94</sup>	57/F	C7/T1	Pain	Posterior approach
Doyle <i>et al.</i> 2008 <sup>12</sup>	57/F	T4/5	Progressive weakness and altered sensation of the lower limbs	Posterior approach (hemilaminectomy, costotransversectomy), total resection
Maeda <i>et al.</i> 2011 <sup>21</sup>	67/M	T2/3	Incidental finding	Combined single-stage surgery with thoracotomy and laminectomy with facetectomy
Suzuki <i>et al.</i> 2011 <sup>95</sup>	73/M	T1/2	Incidental finding	Posterior approach (hemilaminectomy with costotransversectomy)
Vassal <i>et al.</i> 2011 <sup>58</sup>	59/F	T5-7	Back pain, ataxia, paraparesis	Posterior approach (hemilaminectomy with costotransversectomy)
Uchida <i>et al.</i> 2010 <sup>96</sup>	75/M	T11/12	Progressive paraparesis	Posterior approach (laminectomy, total removal)
Yunoki <i>et al.</i> 2015 <sup>30</sup>	77/F	L2/3	Lumbago, L3 Hypoesthesia	Posterior approach (laminectomy, total removal)
Garcia-Pallero <i>et al.</i> 2015 <sup>57</sup>	67/F	T4/5	Pleural effusion, no deficits	Posterior approach (hemilaminectomy, facetectomy and costotransversectomy), total resection

Table 1. Continued

Jeong <i>et al.</i> 2015 <sup>54</sup>	64/M	T2/3	Right infrascapular pain, no deficits	One session two-staged surgery with combined posterior approach (laminectomy Th2-4) in prone position with video-assisted thoracoscopic resection in lateral decubitus position
Wang <i>et al.</i> 2016 <sup>97</sup>	23/F	T1/2	Hypoesthesia of left upper back	Posterior approach, subtotal resection
Egu <i>et al.</i> 2016 <sup>60</sup>	60/M	L5/S1	S1 radiculopathy	Posterior approach
Gao <i>et al.</i> 2017 <sup>17</sup>	Two cases: 41/F 61/F	T2/3 T2-4	Right upper limb weakness Dorsal pain	Posterior approach Subtotal resection Subtotal resection
Sheikhbahaei <i>et al.</i> 2017 <sup>98</sup>	33/M	T4/5	Numbness in lower limbs	Posterior approach, laminectomy+stabilization
Pojskić <i>et al.</i> (this case)	78/M	T3-5	Progressive, bilateral leg weakness and numbness	One session two-staged surgery with combined posterior approach (partial hemilaminectomy and facetectomy with partial costotransversectomy) with video-assisted thoracoscopic resection in lateral decubitus position, total resection

M = male; F = female

cases of pure SEHs. Because of its embryological origin, the most common tumor site is the dorsal or dorsolateral spinal canal where the venous plexus is abundant<sup>16</sup>. Most of epidural hemangiomas are the cavernous type; there are fewer than 10 cases of epidural capillary hemangiomas in the literature<sup>15,30</sup>. Dumbbell-shaped spinal hemangiomas are extremely rare with only 29 cases in the literature described so far (Table 1)<sup>30</sup>.

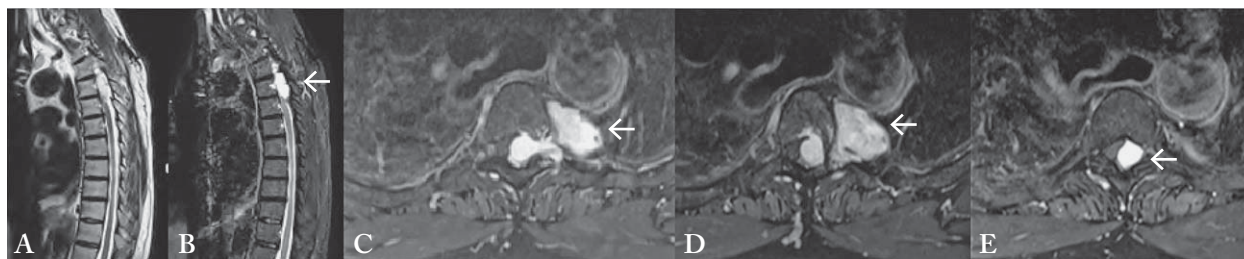
There are several surgical techniques for the resection of thoracic spine dumbbell spinal tumors. Lately, the combined posterior microsurgical approach has been used to resect the intraspinal part of the tumor, followed by subsequent video-assisted thoracoscopic surgery for the intrathoracic part of the tumor, and has gained popularity<sup>7,11,25,26,29</sup>. Other approaches include a posterior-only approach<sup>10</sup>, a posterior approach combined with thoracotomy<sup>9,21</sup>, an extended lateral cavity approach<sup>23</sup>, and a thoracoscopic-only approach<sup>18</sup>. Most cases of spinal dumbbell hemangiomas described in the literature so far were resected using a posterior-only approach or a combined approach with thoracotomy.

Herein we describe a case of a rare dumbbell spinal tumor, an epidural cavernous hemangioma, resected by

a 2-stage single-sitting combined approach (i.e. a posterior microsurgical approach with resection, followed by thoracoscopic approach and endoscopic resection). In addition, we provide a literature review of this rare lesion, including differential diagnosis of dumbbell spinal tumors and surgical techniques performed for their management, as well as a review of all spinal dumbbell hemangiomas published so far.

## Case Report

A 78-year-old male with no significant medical history presented with progressive bilateral leg weakness and numbness during the previous week. Physical examination revealed deep paraparesis (motor strength 3/5 bilaterally) and inability to walk. Magnetic resonance imaging (MRI) with and without contrast revealed a homogeneously enhancing dumbbell-shaped intraspinal extradural tumor mass extending into the left chest cavity. It had displaced the thoracic spinal cord to the right. The tumor extended from the 3<sup>rd</sup> thoracic vertebral body to the upper margin of the 5<sup>th</sup> vertebral body, continuing dumbbell-like through the intervertebral foramen of T4 into the left middle thorax (Fig. 1). The differential diagnosis included neurofi-



*Fig. 1. MRI of the thoracic spine: (A) T2-weighted sagittal sequence showing the intraspinal tumor T3-5 with hyperintense signal (arrow); (B) post-contrast T1-weighted sagittal sequences showed homogeneous enhancement of the tumor; (C, D, E) post-contrast T1-weighted axial sequences revealing dumbbell-shaped tumor with lobular contour extending intraspinally with displacement of the spinal cord to the right and growth through the intervertebral foramen of T4 into the left middle thorax.*

broma or schwannoma, as well as other rare dumbbell-shaped tumors of the spine (such as meningiomas and hemangiomas), malignant peripheral nerve sheath tumors, hemangioblastomas, or metastases. Due to paraparesis and compression of the spinal cord, indication for surgery was made.

The patient underwent a single sitting 2-stage surgery, consisting of both posterior microsurgical and transthoracic endoscopic resection of the tumor. For the posterior approach, partial hemilaminectomy of T3-T5 was performed, which revealed a highly vascularized epidural tumor with spinal cord compression extending into the neuroforamen. Gelfoam powder (Pfizer, New York, NY) and bipolar coagulation were used for hemostasis of the tumor. The intraspinal epidural portion of the tumor was completely resected. A fat pad, harvested at the beginning of surgery *via* a paraumbilical incision<sup>5</sup>, was placed into the foramen as a marker for the extent of resection during the later thoracoscopic procedure. The second stage surgery included video-assisted left thoracoscopic resection of the extraforaminal intrathoracic part of the tumor. For this procedure, the patient was repositioned in the right lateral decubitus position. The fat pad was visualized endoscopically in the neuroforamen at the end of the resection, providing important orientation. Chest tubes were placed at the end of the procedure. The duration of the entire procedure was 4:52 hours. Blood loss was 400 cc. Intraoperative neuromonitoring with somatosensory evoked potentials (SSEPs) and motor evoked potentials (MEPs) was performed and showed no signs of pathological electrophysiological activity.

The patient recovered from surgery and his paraparesis resolved completely. Chest tubes were removed on

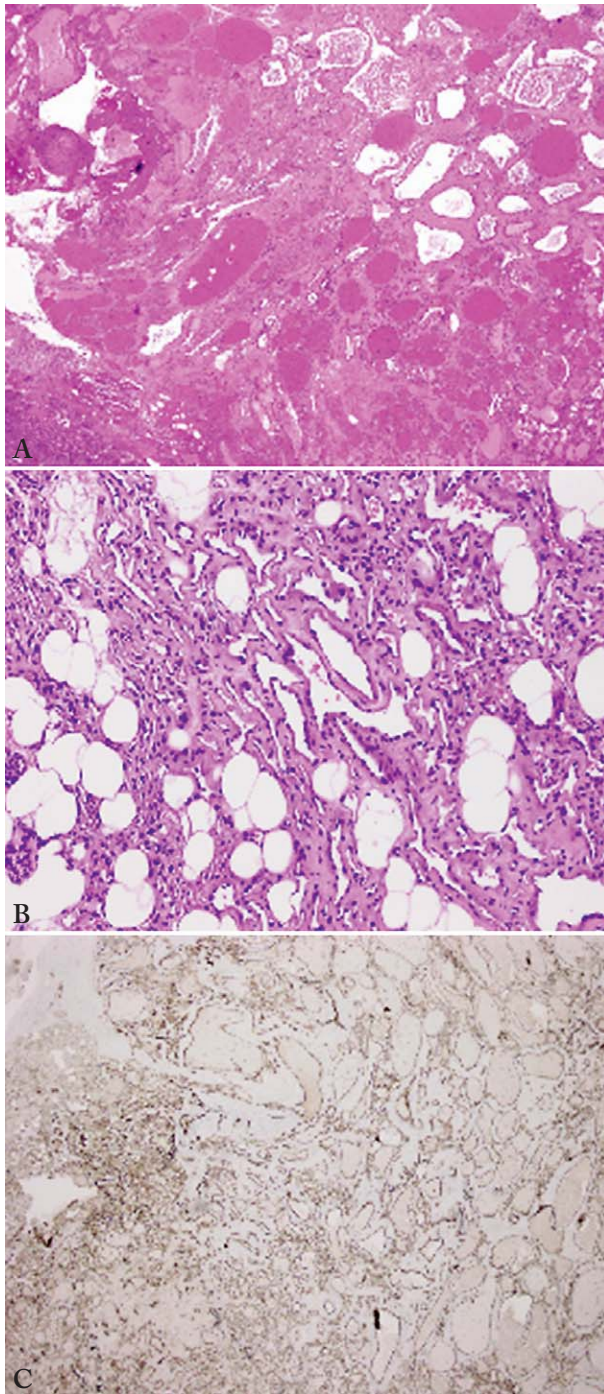
the sixth day following surgery. Complete resolution of paraparesis to normal lower extremity strength was noted along with the absence of bowel or bladder disturbances. Histopathologic evaluation revealed cavernous hemangioma (Fig. 2). Follow-up MRI with and without contrast showed no residual tumor (Fig. 3).

## Discussion

The Eden Classification was the first classification system used for dumbbell tumors, which served as a gold standard for decades<sup>13</sup>. Ninety percent of spinal dumbbell tumors are schwannomas, and up to 33% of schwannomas have a dumbbell form<sup>19,23</sup>. Other dumbbell-shaped tumors include hemangiomas<sup>6,12</sup>, meningiomas<sup>28</sup>, malignant peripheral nerve sheath tumors<sup>22</sup>, neurogenic paravertebral tumors with origin from neurogenic elements within the thorax<sup>7</sup> (including neuroblastoma<sup>20</sup>), ganglioneuroblastoma<sup>20</sup>, ganglioglioma<sup>3</sup>, hemangioblastomas<sup>8</sup>, liposarcomas<sup>31</sup>, lipoblastoma<sup>32</sup>, angiomas<sup>33</sup>, angioliopoma<sup>34</sup>, rhabdomyosarcoma<sup>35</sup>, spine extraosseous chordoma (SEC)<sup>36</sup>, mesenchymal chondrosarcoma<sup>37</sup>, soft tissue chondroma<sup>38</sup>, osteochondroma<sup>39</sup>, malignant glomus tumor<sup>40</sup>, malignant solitary fibrous tumor<sup>41</sup>, plasmocytoma<sup>42</sup>, metastasis<sup>43</sup>, Ewing sarcoma<sup>44</sup>, atypical teratoid rhabdoid tumor<sup>45</sup>, lymphoma<sup>46</sup>, lymphangioma<sup>47</sup>, meningeal melanocytoma<sup>48</sup>, small cell malignant tumor<sup>49</sup>, and peripheral primitive neuroectodermal tumor (PNET)<sup>50</sup>.

## Hemangioma histology

Hemangiomas are benign vascular malformations and are most often found in the skin or soft tissues of



*Fig. 2. Tumor composition of variably-sized vessels and capillaries that permeate adipose tissue: (A) low power; (B) high power. Immunostaining showed that vessels were positive for CD31 (C-term), supporting vascular origin. S100 protein immunostaining was negative for neoplasm/tumor. Given the size and extent of the process, this lesion was classified as hemangioma.*

younger patients. They are characterized histologically by nodules of capillary-sized vessels lined by flattened endothelium and often regress spontaneously<sup>51</sup>. Unlike their cutaneous capillary hemangioma counterparts, spinal hemangiomas are solitary lesions and unassociated with systemic or cutaneous hemangiomas or congenital hemangiomatosis. These tumors occur in adults, and require surgery, as they do not regress<sup>52</sup>. They are found most commonly in intradural extramedullary and intramedullary locations of the thoracic spine and cauda region<sup>52</sup>.

Spinal epidural hemangiomas account for 4% of all spinal epidural tumors, mostly occurring as a primary lesion of the vertebral bone<sup>2</sup>, and can be divided into 2 types: epidural hemangiomas of vertebral origin and primary epidural-space hemangiomas<sup>33-35</sup>. The majority of extradural cavernous hemangiomas extend from a vertebral hemangioma into the spinal canal with purely extradural locations. They represent only 1%-2% of all reported spinal hemangiomas<sup>53</sup>. According to a study by Esene *et al.*<sup>14</sup>, there are approximately 100 reported cases of pure SEHs. Most epidural hemangiomas are of the cavernous type. There are fewer than 10 cases of epidural capillary hemangiomas in the literature<sup>31,38</sup>. Only extradural cases with spinal cord compression have been described<sup>12,54</sup>, as well as cavernous hemangiomas with intradural and extradural growth<sup>6</sup>. There is one case report of juxtaposition of intradural schwannoma and extradural cavernous hemangioma of the thoracic spine<sup>55</sup>.

Histologically, hemangiomas can be divided into capillary and cavernous types, depending on the dominant vessel size under microscopy<sup>52</sup>. Generally, the cavernous type presents with a large number of sinusoidal channels in collagenous tissue, whereas capillary hemangiomas present capsulated lesions characterized by lobules of thin irregular capillary-sized vessels lined by endothelial cells, which are separated by septa of fibrous connective tissue<sup>56</sup>. In addition, the cavernous type of hemangioma often presents with acute symptomatology, mainly related to intratumoral bleeding<sup>57</sup>. On the contrary, capillary hemangiomas usually present in a chronic and progressive manner because of mass effect and nerve root irritation<sup>57</sup>. Table 1 provides an overview of the cases of dumbbell SEHs described in the literature thus far. Most of the described cases were cavernous hemangiomas; there are only 5 capillary hemangiomas reported<sup>52,57-60</sup>.

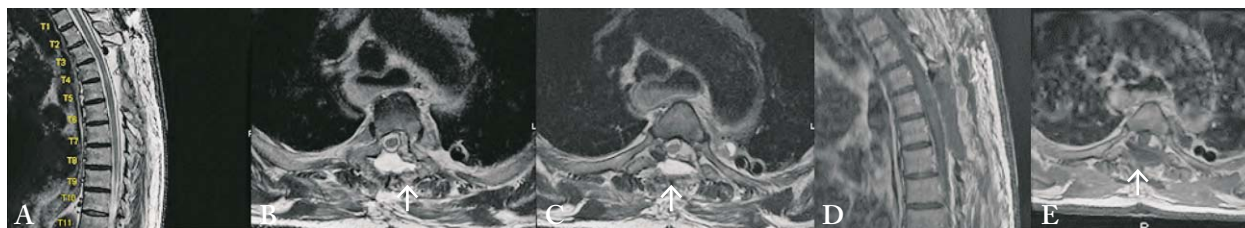


Fig. 3. Postoperative MRI of the thoracic spine: (A) T2-weighted sagittal sequence showing complete resection of the tumor; (B, C) T2-weighted axial sequences; (D) post-contrast T1-weighted axial sequence showing no signs of contrast enhancement; (E) post-contrast T1-weighted axial sequence. Note the fat pad (arrow) applied dorsally to the dural suture.

### Radiological presentation

More than half of all reported dumbbell tumors were completely restricted to the extradural space, although preoperative MRI suggested the presence of intradural/extradural tumors in some cases<sup>61,62</sup>. A wide variety of unusual lesions that can cause neural foraminal widening need to be taken into consideration, including the following: (1) neoplastic lesions, such as benign/malignant peripheral nerve sheath tumors (PNSTs), solitary bone plasmacytoma (SBP), chondroid chordoma, superior sulcus tumor; and (2) metastatic and non-neoplastic lesions, such as infectious process (tuberculosis, hydatid cyst), aneurysmal bone cyst (ABC), synovial cyst, traumatic pseudomeningocele, arachnoid cyst or vertebral artery tortuosity<sup>63</sup>.

Vascular lesions are particularly important in differential diagnosis as they can present with bleeding<sup>64</sup>. It is also important to consider vascular tumors during surgical planning. It is often impossible to differentiate between dumbbell-shaped schwannomas, meningiomas, or vascular lesions. Cavernous hemangiomas should be included in the differential diagnosis of dumbbell-shaped spinal tumors when the intervertebral foramina is not highly dilated, and a non-enhanced nerve root is identified in the tumor<sup>30</sup>.

Magnetic resonance imaging usually yields no definitive findings; both neurogenic tumors and hemangiomas are isointense-to-hypointense on T1 images, and homogeneously hyperintense on T2 images<sup>52</sup>. As a general rule, a diagnosis of schwannoma should be made when a spinal intradural extramedullary tumor shows hyperintensity on T2-weighted images or intense enhancement without dural tail sign; otherwise, a meningioma diagnosis is more probable<sup>65</sup>. One characteristic of spinal meningiomas is the so called 'ginkgo leaf sign' seen on axial post contrast T1 imaging

(the leaf represents a distorted spinal cord pushed to one side of the theca by the meningioma, and the stem is seen as a non-enhancing 'streak' representing the stretched dentate ligament)<sup>66</sup>. One of the signs most indicative of hemangioblastoma is the presence of blood-flow voids on T2-weighted MRI<sup>67</sup>.

Cavernous SEH has a different MRI appearance due to the presence or absence of degenerative phenomena, and the presence of hemosiderin pigments. As in cerebral locations, mixed signal intensity in all MRI sequences might be indicative of cavernous hemangioma<sup>68</sup>. The most common MRI features of cavernous SEHs are solid hypervascular masses with lobular contour<sup>16,69</sup>. A rim of low T2 signal intensity could be present due to deposition of hemosiderin; fibrotic capsule and epidural fat are relatively common findings, too<sup>69</sup>. Additional MRI characteristics for making a differential diagnosis are solid hypervascularity, T1 hyperintensity, or multisegmental involvement<sup>69</sup>. The MRI presentation of SEHs with isointense signal on T1-weighted imaging and hyperintense signal on T2-weighted imaging with homogeneously strong enhancement has been described as a 'sign of wafting silk'. The widening of the intervertebral neural foramen and erosion of the adjacent bones are not uncommon<sup>16</sup>. Typical computed tomography (CT) findings for hemangioma are reported to be lobulation, heterogeneous enhancement with contrast media, multiple ring-like calcifications, and the presence of an intact intervertebral foramen when the tumor extends to the spinal canal; however, these findings are not always observed<sup>70</sup>.

### Surgical technique

Most of the dumbbell spinal hemangiomas described in the literature were resected using a posterior

microsurgical approach with laminectomy or hemilaminectomy, and with or without facetectomy and costotransversectomy (Table 1). A single-stage removal of thoracic dumbbell tumors from a posterior approach with costotransversectomy only<sup>71,72</sup>, and with subsequent instrumentation has been described for schwannomas, neurofibromas, and ganglioneuromas. For resection of the extraspinal component, simple enucleation without thoracotomy can be performed. Although the extraspinal component, including the aorta, cannot be fully seen, it has been argued that enucleation is a safer method since ablation with aorta is unnecessary<sup>71</sup>. A posterior approach may necessitate additional stabilization – its main disadvantage – and reduced visibility of the extraforaminal part of the tumor and adjacent vessels, including the aorta.

Our report describes dumbbell hemangioma resection using a combined approach: unilateral hemilaminectomy with microsurgical resection of the intraspinal part of the tumor, and thoracoscopic resection of the extraforaminal left thoracic tumor extension. Herein, we describe for the first time the following: (1) a 2-stage combined surgery in a single sitting for dumbbell hemangioma with the patient in the lateral decubitus position for the first thoracoscopic part of the surgery; and (2) the use of a fat pad, which was applied in the neuroforamen *via* the posterior route, which served as a marker for resection during the second transthoracic procedure.

#### *Combined 2-stage single session surgery with a posterior microsurgical and thoracoscopic approach*

The combined posterior microsurgical and endoscopic approach for benign mediastinal dumbbell tumors was first described in a case series by Vallieres *et al.* in 1995<sup>29</sup>. So far, there are several reports in the literature on the combined approach for dumbbell tumors of the spinal cord<sup>7,11,26,29,73-75</sup>, but only 1 case report using the combined approach for spinal epidural dumbbell hemangioma<sup>54</sup>. In most reports, the pathology included schwannomas and neurofibromas, and there were rare cases of meningioma, granular cell tumor, and ganglioneuroma. In one patient with neurofibromatosis, Chen *et al.* describe a combined resection of 2 dumbbell tumors – a meningioma and schwannoma at C1/2 and T5/6, respectively<sup>76</sup>.

The posterior approach is restricted to a vertical midline incision centered over the tumor and a transthoracic transpleural approach, which requires removal of fewer facet joints, transverse processes, and ribs. For these reasons, several authors have hypothesized that segmental stability may be less compromised with a combined approach than with a purely posterior approach coupled with costotransversectomy<sup>11,29</sup>.

The combined approach has several disadvantages, though. It is difficult to precisely use thoracoscopic instruments with unexpected bleeding or other emergencies<sup>29</sup>. Postoperative chest tubes may have potential complications, such as postoperative pain, pulmonary dysfunction, and infection<sup>77</sup>. For most video-assisted thoracic surgery, patients are usually placed in the lateral decubitus position with safe resection of posterior mediastinal dumbbell tumors using video-assisted thoracoscopy<sup>29</sup>. However, the only case report of dumbbell spinal hemangioma resected *via* this combined approach included turning the patient in lateral decubitus position<sup>54</sup>.

#### *Other combined approaches for resection of spinal dumbbell tumors in the thoracic spine*

The combined approach with posterior microsurgical resection *via* laminectomy followed by thoracotomy has been performed for spinal dumbbell meningiomas<sup>9</sup>. Other authors have favored thoracotomy prior to laminectomy for the resection of dumbbell-shaped tumors of the mediastinum, especially with marked vascularity, such as that seen with hemangiomas because the initial thoracotomy facilitates subsequent laminectomy procedures, enables ligation of the tumor arteries, and precludes extensive bleeding in spinal canal<sup>21</sup>. Image-guided thoracoscopic-only resection of dumbbell mediastinal tumors with a small intraspinal portion have been previously described<sup>18</sup>. Uehara *et al.* describe a case of dumbbell Ewing sarcoma where transthoracic biopsy was performed and the tumor was consequently treated with chemotherapy<sup>44</sup>. Another report by Yamaguchi *et al.* describes combined thoracoscopic and supraclavicular approach for a cervico-mediastinal neurogenic tumor with an intraforaminal portion at C7/T1<sup>78</sup>. Hakuba *et al.* performed a transuncodiscal approach to dumbbell tumors of the cervical spinal canal, which included anterior discectomy and ipsilateral unectomy, and removal of the posterolateral corners and posterior transverse ridges of the

upper and lower vertebral bodies at the level of the tumor<sup>79</sup>.

Resection of thoracic and lumbar spinal schwannomas can be performed using the unilateral posterior approach only<sup>10</sup>. The lateral extracavitary approach (LECA) can be used for resection of dumbbell tumors of the thoracolumbar spine, especially when extensive or difficult and paraspinous exposure is required<sup>23</sup>. Vecil *et al.* report multi-level rib resections with extended lateral parascapular approach for giant thoracic schwannoma and laminectomy necessitating posterior spinal stabilization<sup>80</sup>.

### Alternative treatments

When totally removed, these tumors do not recur during follow-up periods of at least 5 years. Even when complete removal is accomplished, some symptoms may persist, possibly due to scarring around the dural sac or the involved nerve root but this does not necessarily indicate lesion recurrence. However, in cases of subtotal resection, radiation therapy has been advised<sup>17,81</sup>. Endovascular embolization has been recently used to remove a hemangioma, successfully minimizing blood loss during the operation<sup>82</sup>. However, this management approach carries the risk of spinal infarction. There is also a report on image-guided stereotactic radiosurgery of epidural hemangiomas with hypofractionated dose of 32 Gy in 4 fractions in a patient having undergone open decompression and biopsy; follow-up showed gradual reduction of the tumor mass<sup>83</sup>.

### Conclusion

Vascular dumbbell lesions of the spinal cord, such as hemangiomas, are rare and may be clinically or radiologically indistinguishable from other lesions, but they should be considered when making a differential diagnosis. The combined single-sitting, 2-stage posterior microsurgical approach *via* hemilaminectomy followed by thoracoscopic resection is a safe, time-saving, stable, and conformable surgical treatment option for these lesions, resulting in excellent clinical outcome with complete resolution of deep paraparesis.

### Acknowledgment

The authors wish to thank Andrew J. Gienapp (Neuroscience Institute, Le Bonheur Children's Hos-

pital, Memphis, TN and Department of Neurosurgery, University of Tennessee Health Science Center, Memphis, TN) for copy editing, preparation of the manuscript, figures, and table for publishing, and publication assistance.

### References

1. Heuer GJ. The so-called hour-glass tumors of the spine. *Arch Surg*; 1929; p. 935-81.
2. Aoyagi N, Kojima K, Kasai H. Review of spinal epidural cavernous hemangioma. *Neurol Med Chir (Tokyo)*. 2003;43(10):471-5; discussion 6. doi: 10.2176/nmc.43.471.
3. Arapis C, Gossot D, Debrosse D, Arper L, Mazel C, Grunewald D. Thoracoscopic removal of neurogenic mediastinal tumors: technical aspects. *Surg Endosc*. 2004;18(9):1380-3. Epub 2004/06/23. doi: 10.1007/s00464-003-9329-9.
4. Arnautovic K, Arnautovic A. Extramedullary intradural spinal tumors: a review of modern diagnostic and treatment options and a report of a series. *Bosn J Basic Med Sci*. 2009;9 Suppl 1:40-5. doi: 10.17305/bjbms.2009.2755.
5. Arnautovic KI, Kovacevic M. CSF-Related complications after intradural spinal tumor surgery: utility of an autologous fat graft. *Med Arch*. 2016;70(6):460-5. doi: 10.5455/medarh.2016.70.460-465.
6. Baldvinsdóttir B, Erlingsdóttir G, Kjartansson Ó, Ólafsson IH. Extramedullary cavernous hemangioma with intradural and extradural growth and clinical symptoms of Brown-Séquard syndrome: case report and review of the literature. *World Neurosurg*. 2017;98:881.e5-.e8. Epub 2016/11/17. doi: 10.1016/j.wneu.2016.11.026.
7. Barrenechea JJ, Fukumoto R, Lesser JB, Ewing DR, Connery CP, Perin NI. Endoscopic resection of thoracic paravertebral and dumbbell tumors. *Neurosurgery*. 2006;59(6):1195-201; discussion 201-2. doi: 10.1227/01.NEU.0000245617.39850.C9.
8. Barrey C, Kalamarides M, Polivka M, George B. Cervical dumbbell intra-extradural hemangioblastoma: total removal through the lateral approach: technical case report. *Neurosurgery*. 2005;56(3):E625. doi: 10.1227/01.NEU.0000154134.83900.05.
9. Buchfelder M, Nomikos P, Paulus W, Rupprecht H. Spinal-thoracic dumbbell meningioma: a case report. *Spine (Phila Pa 1976)*. 2001;26(13):1500-4.
10. Canbay S, Hasturk AE, Basmaci M, Erten F, Harman F. Management of thoracic and lumbar schwannomas using a unilateral approach without instability: an analysis of 15 cases. *Asian Spine J*. 2012;6(1):43-9. Epub 2012/03/09. doi: 10.4184/asj.2012.6.1.43.
11. Citow JS, Macdonald RL, Ferguson MK. Combined laminectomy and thoracoscopic resection of a dumbbell neurofibroma: technical case report. *Neurosurgery*. 1999;45(5):1263-5; discussion 5-6.



12. Doyle PM, Abou-Zeid A, Du Plessis D, Herwadkar A, Gnanaalingham KK. Dumbbell-shaped intrathoracic-extradural haemangioma of the thoracic spine. *Br J Neurosurg.* 2008; 22(2):299-300. doi: 10.1080/02688690701678610.
13. Eden K. The dumb-bell tumors of the spine. *Br J Surg.* 1941;28:549-70.
14. Esene IN, Ashour AM, Marvin E, Nosseir M, Fayed ZY, Seoud K, *et al.* Pure spinal epidural cavernous hemangioma: a case series of seven cases. *J Craniovertebr Junction Spine.* 2016;7(3):176-83. doi: 10.4103/0974-8237.188419.
15. Feider HK, Yuille DL. An epidural cavernous hemangioma of the spine. *AJNR Am J Neuroradiol.* 1991;12(2):243-4.
16. Feng J, Xu YK, Li L, Yang RM, Ye XH, Zhang N, *et al.* MRI diagnosis and preoperative evaluation for pure epidural cavernous hemangiomas. *Neuroradiology.* 2009;51(11):741-7. Epub 2009/07/09. doi: 10.1007/s00234-009-0555-2.
17. Gao C, Xu W, Qing Lian J, Feng D, Cui JF, Liu H. Spinal epidural cavernous hemangioma: a clinical series of seven patients. *World Neurosurg.* 2017. Epub 2017/12/14. doi: 10.1016/j.wneu.2017.12.006.
18. Ghostine S, Vaynman S, Schoeb JS, Cambron H, King WA, Samudrala S, *et al.* Image-guided thoracoscopic resection of thoracic dumbbell nerve sheath tumors. *Neurosurgery.* 2012; 70(2):461-7; discussion 8. doi: 10.1227/NEU.0b013e318235ba96.
19. Hirano K, Imagama S, Sato K, Kato F, Yukawa Y, Yoshihara H, *et al.* Primary spinal cord tumors: review of 678 surgically treated patients in Japan. A multicenter study. *Eur Spine J.* 2012;21(10):2019-26. Epub 2012/05/12. doi: 10.1007/s00586-012-2345-5.
20. Hussein HA, Goda HA. Paravertebral neurogenic tumors with intraspinal extension: preoperative evaluation and surgical approach. *J Egypt Natl Canc Inst.* 2009;21(1):12-22.
21. Maeda S, Takahashi S, Koike K, Sato M. Preferred surgical approach for dumbbell-shaped tumors in the posterior mediastinum. *Ann Thorac Cardiovasc Surg.* 2011;17(4):394-6.
22. Matsumoto Y, Endo M, Harimaya K, Hayashida M, Doi T, Iwamoto Y. Malignant peripheral nerve sheath tumors presenting as spinal dumbbell tumors: clinical outcomes and characteristic imaging features. *Eur Spine J.* 2015;24(10):2119-25. doi: 10.1007/s00586-014-3467-8.
23. McCormick PC. Surgical management of dumbbell and paraspinous tumors of the thoracic and lumbar spine. *Neurosurgery.* 1996;38(1):67-74; discussion -5.
24. Morioka T, Nakagaki H, Matsushima T, Hasuo K. Dumbbell-shaped spinal epidural cavernous angioma. *Surg Neurol.* 1986; 25(2):142-4.
25. Negri G, Regolo P, Gerevini S, Arrigoni G, Zannini P. Mediastinal dumbbell angioliopoma. *Ann Thorac Surg.* 2000;70(3): 957-8.
26. Okada D, Koizumi K, Haraguchi S, Hirata T, Hirai K, Mikami I, *et al.* A case of dumbbell tumor of the superior mediastinum removed by combined thoracoscopic surgery. *J Nippon Med Sch.* 2002;69(1):58-61.
27. Saringer W, Nöbauer I, Haberler C, Ungersböck K. Extraforaminal, thoracic, epidural cavernous haemangioma: case report with analysis of magnetic resonance imaging characteristics and review of the literature. *Acta Neurochir (Wien).* 2001; 143(12):1293-7. doi: 10.1007/s007010100028.
28. Suzuki A, Nakamura H, Konishi S, Yamano Y. Dumbbell-shaped meningioma with cystic degeneration in the thoracic spine: a case report. *Spine (Phila Pa 1976).* 2002;27(7):E193-6.
29. Vallières E, Findlay JM, Fraser RE. Combined microneurosurgical and thoracoscopic removal of neurogenic dumbbell tumors. *Ann Thorac Surg.* 1995;59(2):469-72.
30. Yunoki M, Suzuki K, Uneda A, Yoshino K. A case of dumbbell-shaped epidural cavernous angioma in the lumbar spine. *Surg Neurol Int.* 2015;6(Suppl 10):S309-12. Epub 2015/06/25. doi: 10.4103/2152-7806.159378.
31. Kaneuchi Y, Hakozaiki M, Yamada H, Tajino T, Watanabe K, Otani K, *et al.* Primary dumbbell-shaped epidural myxoid liposarcoma of the thoracic spine: a case report and review of the literature. *Oncol Lett.* 2016;11(2):1421-4. Epub 2016/01/08. doi: 10.3892/ol.2016.4089.
32. Spazzapan P, Srpčić M, Prestor B. Spinal dumbbell lipoblastoma: a case-based update. *Childs Nerv Syst.* 2016;32(11): 2069-73. Epub 2016/07/21. doi: 10.1007/s00381-016-3184-1.
33. Tang EK, Chu PT, Goan YG, Hsieh PP, Lin JC. Dumbbell-mimicked mediastinal angiomatosis. *Ann Thorac Surg.* 2016; 102(6):e555-e6. doi: 10.1016/j.athoracsur.2016.05.051.
34. Gámez García P, de Pablo Gafas A, Salas Antón C, Santolaya Cohen R, Madrigal Royo L, Varela de Ugarte A. [Mediastinal dumbbell angioliopoma]. *Arch Bronconeumol.* 2002;38(11): 545-6. (in Spanish)
35. Ozawa H, Kokubun S, Aizawa T, Hoshikawa T, Kawahara C. Spinal dumbbell tumors: an analysis of a series of 118 cases. *J Neurosurg Spine.* 2007;7(6):587-93. doi: 10.3171/SPI-07/12/587.
36. Yang J, Yang X, Miao W, Jia Q, Wan W, Meng T, *et al.* Spine extra-osseous chordoma mimicking neurogenic tumors: report of three cases and review of the literatures. *World J Surg Oncol.* 2016;14(1):206. Epub 2016/08/04. doi: 10.1186/s12957-016-0951-0.
37. Chen S, Wang Y, Su G, Chen B, Lin D. Primary intraspinal dumbbell-shaped mesenchymal chondrosarcoma with massive calcifications: a case report and review of the literature. *World J Surg Oncol.* 2016;14(1):203. Epub 2016/08/03. doi: 10.1186/s12957-016-0963-9.
38. Thien A, Teo CH, Lim CC, Karandikar A, Dinesh SK. Soft tissue chondroma mimicking "dumbbell" neurogenic tumour: a rare cause of lumbar radiculopathy. *J Clin Neurosci.* 2014;21 (6):1073-4. Epub 2013/11/13. doi: 10.1016/j.jocn.2013.09.011.
39. Lee JH, Oh SH, Cho PG, Han EM, Hong JB. Solitary osteochondroma presenting as a dumbbell tumor compressing the cervical spinal cord. *Korean J Spine.* 2017;14(3):99-102. Epub 2017/09/30. doi: 10.14245/kjs.2017.14.3.99.
40. Nagata K, Hashizume H, Yamada H, Yoshida M. Long-term survival case of malignant glomus tumor mimicking "dumb-

- bell-shaped" neurogenic tumor. *Eur Spine J.* 2017;26(Suppl 1): 42-6. Epub 2016/07/15. doi: 10.1007/s00586-016-4703-1.
41. Nagano A, Ohno T, Nishimoto Y, Oshima K, Shimizu K. Malignant solitary fibrous tumor of the lumbar spinal root mimicking schwannoma: a case report. *Spine J.* 2014;14(1):e17-20. Epub 2013/10/09. doi: 10.1016/j.spinee.2013.07.463.
  42. Matsumoto Y, Harimaya K, Kawaguchi K, Hayashida M, Okada S, Doi T, *et al.* Dumbbell scoring system: a new method for the differential diagnosis of malignant and benign spinal dumbbell tumors. *Spine (Phila Pa 1976).* 2016;41(20): E1230-E6. doi: 10.1097/BRS.0000000000001582.
  43. Boese CK, Lechler P, Bredow J, Al Muhaisen N, Eysel P, Koy T. Atypical presentation of a cervical breast-cancer metastasis mimicking a dumbbell-shaped neurinoma. *Int J Surg Case Rep.* 2014;5(10):689-93. Epub 2014/08/11. doi: 10.1016/j.ijscr.2014.06.019.
  44. Uehara S, Oue T, Yoneda A, Hashii Y, Ohta H, Fukuzawa M. Dumbbell-shaped Ewing's sarcoma family of tumor of thoracic spine in a child. *Pediatr Surg Int.* 2008;24(8):953-5. Epub 2008/06/10. doi: 10.1007/s00383-008-2183-z.
  45. Hong S, Ogiwara H. Dumbbell-shaped atypical teratoid rhabdoid tumor in the cervical spine mimicking schwannoma. *Childs Nerv Syst.* 2017. Epub 2017/10/10. doi: 10.1007/s00381-017-3603-y.
  46. Gezen F, Akay KM, Tayfun C, Günhan O, Bedük A, Seber N. Dumbbell lymphoma of the cervical spine in a child. *Case report. J Neurosurg Sci.* 1998;42(4):239-44.
  47. Saito T, Terada K, Tsuchiya K, Oda Y, Tsuneyoshi M, Iwamoto Y. Lymphangioma presenting as a dumbbell tumor in the epidural space of the lumbar spine. *Spine (Phila Pa 1976).* 1999; 24(1):74-6.
  48. Yang C, Fang J, Li G, Jia W, Liu H, Qi W, *et al.* Spinal meningeal melanocytomas: clinical manifestations, radiological and pathological characteristics, and surgical outcomes. *J Neurooncol.* 2016;127(2):279-86. Epub 2016/03/03. doi: 10.1007/s11060-015-2006-8.
  49. Liu T, Liu H, Zhang JN, Zhu T. Surgical strategy for spinal dumbbell tumors: a new classification and surgical outcomes. *Spine (Phila Pa 1976).* 2017;42(12):E748-E54. doi: 10.1097/BRS.0000000000001945.
  50. Khmou M, Malihi A, Lamalmi N, Rouas L, Alhamany Z. Peripheral primitive neuroectodermal tumors of the spine: a case report and review of the literature. *BMC Res Notes.* 2016;9(1):438. Epub 2016/09/09. doi: 10.1186/s13104-016-2246-5.
  51. Nowak DA, Widenka DC. Spinal intradural capillary haemangioma: a review. *Eur Spine J.* 2001;10(6):464-72.
  52. Kang JS, Lillehei KO, Kleinschmidt-Demasters BK. Proximal nerve root capillary hemangioma presenting as a lung mass with bandlike chest pain: case report and review of literature. *Surg Neurol.* 2006;65(6):584-9; discussion 9. doi: 10.1016/j.surneu.2005.07.070.
  53. Shin JH, Lee HK, Rhim SC, Park SH, Choi CG, Suh DC. Spinal epidural cavernous hemangioma: MR findings. *J Comput Assist Tomogr.* 2001;25(2):257-61.
  54. Jeong WJ, Choi I, Seong HY, Roh SW. Thoracic extradural cavernous hemangioma mimicking a dumbbell-shaped tumor. *J Korean Neurosurg Soc.* 2015;58(1):72-5. Epub 2015/07/31. doi: 10.3340/jkns.2015.58.1.72.
  55. Thomé C, Zevgaridis D, Matejic D, Sommer C, Krauss JK. Juxtaposition of an epidural intraforaminal cavernous hemangioma and an intradural schwannoma. *Spine (Phila Pa 1976).* 2004;29(22):E524-7.
  56. Hasan A, Guiot MC, Torres C, Marcoux J. A case of a spinal epidural capillary hemangioma: case report. *Neurosurgery.* 2011;68(3):E850-3. doi: 10.1227/NEU.0b013e3182093320.
  57. García-Pallero MA, Torres CV, García-Navarrete E, Gordillo C, Delgado J, Penanes JR, *et al.* Dumbbell-shaped epidural capillary hemangioma presenting as a lung mass: case report and review of the literature. *Spine (Phila Pa 1976).* 2015; 40(14):E849-53. doi: 10.1097/BRS.0000000000000970.
  58. Vassal F, Péoc'h M, Nuti C. Epidural capillary hemangioma of the thoracic spine with proximal nerve root involvement and extraforaminal extension. *Acta Neurochir (Wien).* 2011;153 (11):2279-81. Epub 2011/08/06. doi: 10.1007/s00701-011-1121-3.
  59. Badinand B, Morel C, Kopp N, Tran Min VA, Cotton F. Dumbbell-shaped epidural capillary hemangioma. *AJNR Am J Neuroradiol.* 2003;24(2):190-2.
  60. Egu K, Kinata-Bambino S, Mounadi M, Rachid El Maaqili M, El Abbadi N. [Lombosacral epidural capillary hemangioma mimicking a dumbbell-shaped neurinoma: a case report and review of the literature]. *Neurochirurgie.* 2016;62(2):113-7. Epub 2015/12/21. doi: 10.1016/j.neuchi.2015.08.002. (in French)
  61. George B, Lot G. Surgical treatment of dumbbell neurinomas of the cervical spine. *Crit Rev Neurosurg.* 1999;9(3):156-60.
  62. Isoda H, Takahashi M, Mochizuki T, Ramsey RG, Masui T, Takehara Y, *et al.* MRI of dumbbell-shaped spinal tumors. *J Comput Assist Tomogr.* 1996;20(4):573-82.
  63. Kivrak AS, Koc O, Emlik D, Kiresi D, Odev K, Kalkan E. Differential diagnosis of dumbbell lesions associated with spinal neural foraminal widening: imaging features. *Eur J Radiol.* 2009;71(1):29-41. Epub 2008/05/16. doi: 10.1016/j.ejrad.2008.03.020.
  64. Panero Perez I, Eiriz Fernandez C, Lagares Gomez-Abascal A, Toldos González O, Panero López A, Paredes Sansinenea I. Intradural-extramedullary capillary hemangioma with acute bleeding, case report and literature review. *World Neurosurg.* 2017. Epub 2017/08/17. doi: 10.1016/j.wneu.2017.08.030.
  65. De Verdelhan O, Haegelen C, Carsin-Nicol B, Riffaud L, Am-lashi SF, Brassier G, *et al.* MR imaging features of spinal schwannomas and meningiomas. *J Neuroradiol.* 2005;32(1): 42-9.
  66. Yamaguchi S, Takeda M, Takahashi T, Yamahata H, Mitsu-hara T, Niuro T, *et al.* Ginkgo leaf sign: a highly predictive imaging feature of spinal meningioma. *J Neurosurg Spine.* 2015;1:5. Epub 2015/07/31. doi: 10.3171/2015.3.SPINE1598.

67. Wu L, Yang T, Deng X, Xu Y. Intra-extradural dumbbell-shaped hemangioblastoma of the cauda equina mimicking schwannoma. *Neurol India*. 2013;61(3):338-9. doi: 10.4103/0028-3886.115103.
68. Padolecchia R, Acerbi G, Puglioli M, Collavoli PL, Ravelli V, Caciagli P. Epidural spinal cavernous hemangioma. *Spine (Phila Pa 1976)*. 1998;23(10):1136-40.
69. Lee JW, Cho EY, Hong SH, Chung HW, Kim JH, Chang KH, *et al.* Spinal epidural hemangiomas: various types of MR imaging features with histopathologic correlation. *AJNR Am J Neuroradiol*. 2007;28(7):1242-8. doi: 10.3174/ajnr.A0563.
70. McAdams HP, Rosado-de-Christenson ML, Moran CA. Mediastinal hemangioma: radiographic and CT features in 14 patients. *Radiology*. 1994;193(2):399-402. doi: 10.1148/radiology.193.2.7972751.
71. Ando K, Imagama S, Wakao N, Hirano K, Tauchi R, Muramoto A, *et al.* Single-stage removal of thoracic dumbbell tumors from a posterior approach only with costotransversectomy. *Yonsei Med J*. 2012;53(3):611-7. doi: 10.3349/ymj.2012.53.3.611.
72. Ando K, Imagama S, Ito Z, Tauchi R, Muramoto A, Matsui H, *et al.* Removal of thoracic dumbbell tumors through a single-stage posterior approach: its usefulness and limitations. *J Orthop Sci*. 2013;18(3):380-7. Epub 2013/03/20. doi: 10.1007/s00776-013-0370-9.
73. Negri G, Puglisi A, Gerevini S, Voci C, Zannini P. Thoracoscopic techniques in the management of benign mediastinal dumbbell tumors. *Surg Endosc*. 2001;15(8):897. Epub 2001/05/07. doi: 10.1007/s004640042001.
74. Findlay JM. Combined laminectomy and thoracoscopic resection of a dumbbell neurofibroma: technical case report. *Neurosurgery*. 2000;46(5):1270-1.
75. Wang ZY, Liang Z, Liu B, Cheng XD, Zhang J. Combined microneurosurgical and thoracoscopic resection for thoracic spine dumbbell tumors. *Chin Med J (Engl)*. 2008;121(12):1137-9.
76. Chen JC, Tseng SH, Chen Y, Tzeng JE, Lin SM. Cervical dumbbell meningioma and thoracic dumbbell schwannoma in a patient with neurofibromatosis. *Clin Neurol Neurosurg*. 2005;107(3):253-7. doi: 10.1016/j.clineuro.2004.06.012.
77. Payer M, Radovanovic I, Jost G. Resection of thoracic dumbbell neurinomas: single postero-lateral approach or combined posterior and transthoracic approach? *J Clin Neurosci*. 2006;13(6):690-3. Epub 2006/06/23. doi: 10.1016/j.jocn.2005.09.010.
78. Yamaguchi M, Yoshino I, Kameyama T, Osoegawa A, Tagawa T, Maehara Y. Thoracoscopic surgery combined with a supraclavicular approach for removing a cervico-mediastinal neurogenic tumor: a case report. *Ann Thorac Cardiovasc Surg*. 2006;12(3):194-6.
79. Hakuba A, Komiyama M, Tsujimoto T, Ahn MS, Nishimura S, Ohta T, *et al.* Transcondiscal approach to dumbbell tumors of the cervical spinal canal. *J Neurosurg*. 1984;61(6):1100-6. doi: 10.3171/jns.1984.61.6.1100.
80. Vecil GG, McCutcheon IE, Mendel E. Extended lateral parascapular approach for resection of a giant multi-compartment thoracic schwannoma. *Acta Neurochir (Wien)*. 2008;150(12):1295-300; discussion 300. Epub 2008/11/18. doi: 10.1007/s00701-008-0154-8.
81. McEvoy SH, Farrell M, Brett F, Looby S. Haemangioma, an uncommon cause of an extradural or intradural extramedullary mass: case series with radiological pathological correlation. *Insights Imaging*. 2016;7(1):87-98. Epub 2015/09/18. doi: 10.1007/s13244-015-0432-y.
82. Lee SY, Lee JH, Hur GY, Kim JH, In KH, Kang KH, *et al.* Successful removal of a slowly growing mediastinal cavernous haemangioma after vascular embolization. *Respirology*. 2006;11(4):493-5. doi: 10.1111/j.1440-1843.2006.00877.x.
83. Sohn MJ, Lee DJ, Jeon SR, Khang SK. Spinal radiosurgical treatment for thoracic epidural cavernous hemangioma presenting as radiculomyelopathy: technical case report. *Neurosurgery*. 2009;64(6):E1202-3; discussion E3. doi: 10.1227/01.NEU.0000345940.21674.AE.
84. Rovira A, Rovira A, Capellades J, Zauner M, Bella R, Rovira M. Lumbar extradural hemangiomas: report of three cases. *AJNR Am J Neuroradiol*. 1999;20(1):27-31. Epub 1999/02/12.
85. Padovani R, Tognetti F, Proietti D, Pozzati E, Servadei F. Extrathecal cavernous hemangioma. *Surg Neurol*. 1982;18(6):463-5.
86. Franz K, Lesoin F, Leys D, Krivosic I, Jomin M. [Spinal epidural dumbbell-shaped cavernous angioma]. *Rev Neurol (Paris)*. 1987;143(4):298-300. (in French)
87. Fukushima M, Nabeshima Y, Shimazaki K, Hirohata K. Dumbbell-shaped spinal extradural hemangioma. *Arch Orthop Trauma Surg*. 1987;106(6):394-6.
88. Haimes AB, Krol G. Dumbbell-shaped spinal cavernous hemangioma: a case report. *AJNR Am J Neuroradiol*. 1991;12(5):1021-2.
89. Lanotte M, Massaro F, Faccani G, Forni M, Valentini MC. Dumbbell-shaped spinal epidural cavernous angioma. Case report. *Ital J Neurol Sci*. 1994;15(8):429-32.
90. Harrington JF, Khan A, Grunnet M. Spinal epidural cavernous angioma presenting as a lumbar radiculopathy with analysis of magnetic resonance imaging characteristics: case report. *Neurosurgery*. 1995;36(3):581-4.
91. Bavbek M, Yurt A, Caner H, Altinörs N. An unusual dumbbell form of cavernous hemangioma of the cervical spine. *Kobe J Med Sci*. 1997;43(2):57-63.
92. Carlier R, Engerand S, Lamer S, Vallee C, Bussel B, Polivka M. Foramina epidural extra osseous cavernous hemangioma of the cervical spine: a case report. *Spine (Phila Pa 1976)*. 2000;25(5):629-31.
93. Hara K, Hidaka K. [Cavernous hemangioma growing continuously from the spinal epidural space into the paravertebral muscles: case report]. *No Shinkei Geka*. 2006;34(5):521-5. (in Japanese)
94. Iglesias S, Ayerbe J, Sarasa JL, Sousa P, Torres C, Ruiz-Barnés P. [Dumbbell-shaped spinal epidural cavernous angioma. Case

- report and review of the literature]. *Neurocirugia (Astur)*. 2008;19(3):248-53. (in Spanish)
95. Suzuki H, Sekine Y, Yamamoto N, Hiroshima K. Hemilaminectomy for a dumbbell-shaped vertebral hemangioma. *Thorac Cardiovasc Surg*. 2011;59(6):383-4. Epub 2011/03/22. doi: 10.1055/s-0030-1250652.
96. Uchida K, Yayama T, Nakajima H, Hirai T, Kobayashi S, Chen K, *et al.* Microsurgical resection of cavernous haemangioma around the thoracic neuroforamen: a case report. *J Orthop Surg (Hong Kong)*. 2010;18(3):370-3. doi: 10.1177/230949901001800324.
97. Wang S, Wang M, Wang F, Yuan X, Xiao H, Bai Y, *et al.* Dumbbell-shaped epidural cavernous hemangioma in the thoracic spine mimicking schwannoma. *J Craniofac Surg*. 2016; 27(7):e619-e20. doi: 10.1097/SCS.0000000000002953.
98. Sheikhbahaei E, Andalib A. A Dumbbell-shaped extradural intracanal cavernous hemangioma: a rare case report and review of literature. *J Orthop Oncol*. 2017.2017;3:1. doi: 10.4172/2472-016X.1000116.

## Sažetak

SPINALNI EPIDURALNI HEMANGIOM PJEŠČANOG SATA:  
JEDNOKRATNA 2-STUPANJSKA POSTERIORNA MIKROKIRURŠKA  
I TRANSTORAKALNA ENDOSKOPSKA RESEKCIJA  
– PRIKAZ SLUČAJA I PREGLED LITERATURE

*M. Pojskić, B. Zbytek, Ch. J. Mutrie i K. I. Arnautović*

Spinalni tumori pješčanog sata definirani su suženjem na mjestu gdje prodiru u intervertebralni foramen ili dura mater, uz pretpostavku da imaju oblik pješčanog sata ili bučice. Spinalni hemangiomi u obliku bučice su iznimno rijetki. Opisuje se spinalni tumor pješčanog sata (epiduralni kavernozi hemangiomi) resecirani dvostupanjskim kombiniranim pristupom, uz opsežan pregled literature. Prikazuje se slučaj 78-godišnjeg muškarca za kojeg je utvrđeno da ima homogeno pojačanu intraspinalnu, ekstraduralnu masu u obliku bučice koja se širi u lijevu prsnu šupljinu. Tumor je resecirani jednokratnom 2-stupanjskom posteriornom tehnikom: mikrokirurški pristup, nakon čega slijedi endoskopska resekcija putem torakoskopskog pristupa. U literaturi postoji nekoliko izvješća o kombiniranom pristupu za tumore bučice kralježnične moždine. Naš je slučaj prvi koji opisuje 2-stupanjsku kombiniranu kirurgiju u 1 sjedenju za hemangiomi pješčanog sata u bolesnika u lateralnom deku-bitusnom položaju za torakoskopski dio operacije; i uporabu masnog jastučića koji je primijenjen u neuroforamenu preko stražnjeg puta, kao marker za resekciju tijekom transtorakalnog postupka.

Ključne riječi: *Kralježnica; Tumor pješčanog sata, epiduralni; Hemangiomi; Mikrokirurgija; Endoskopija; Torakoskopski pristup*