

# Histopathology of the Pterygium in Population on Croatian Island Rab

Božidar Vojniković<sup>1</sup>, Sanja Njirić<sup>2</sup>, Gordana Zamolo<sup>3</sup>, Ivan Toth<sup>4</sup>, Josip Španjol<sup>5</sup> and Miran Čoklo<sup>6</sup>

<sup>1</sup> Eye Polyclinic »Dr. B. Vojniković«, Rijeka, Croatia

<sup>2</sup> Eye Polyclinic »Dr. L. Pavičević«, Rijeka, Croatia

<sup>3</sup> Department of Pathology, Rijeka University School of Medicine, Rijeka, Croatia

<sup>4</sup> Polytechnic College »Velika Gorica«, Velika Gorica, Croatia

<sup>5</sup> Department of Urology, Rijeka University Hospital, Rijeka, Croatia

<sup>6</sup> Department of Forensic Medicine, Rijeka University School of Medicine, Rijeka, Croatia

## ABSTRACT

*In the 1975–2004 period, 130 cases of pterygium were estimated, 83 males and 47 females, on a small island Rab. Island Rab is located in the north part of the Adriatic sea, which has very high index of sun radiation. Pterygium is usually histopathologically defined as a hyperplasia of conjunctival tissue, elastoid degeneration of subepithelium and fragmentation of Bowman's membrane. Our histopathological findings in 73 eyes are following: conjunctiva with neovascularisation, leukocyte margination and subepithelial basophilic degeneration, proliferation of conjunctival tissue, acanthosis and squamous metaplasia, and mucinous elements, focally present plasma cells, focuses of increased pigmentation in basal epithelial layers, tenon capsule with edema, diffuse neovascularisation and fragmentation of fibrils. These findings suggest that in severe cases of pterygium histopathologically exists precancerosis. In conclusion, on the basis of these histopathological findings, especially in the Tenon capsule, we suggest that for surgical procedure of pterygium the excision of the Tenon capsule, extensively under pterygium, is necessary.*

**Key words:** pterygium, histopathology, surgery

## Introduction

One of the most important risk factors in developing pterygium is chronic exposure of the eyes to sunlight<sup>1–5</sup>, especially UV radiation<sup>2,5</sup>. In the last 20 years because of the depletion of the ozone layer, UV radiation on the Earth surface is significantly increased, with the consequent increase of erythemal UV Index<sup>6–8</sup>.

Histopathologically, pterygium is an arrangement with hyperplasia of conjunctival tissue, elastoid degeneration of subepithelium structure and fragmentation of Bowman's membrane<sup>9,10</sup>.

Considering the fact, that on the island Rab the number of pterygium cases is increasing, and usually surgery technic is unsuccessful, we decided for the histopathological study in those cases.

## Patients and Methods

In 130 patients pterygium was diagnosed on island Rab, during systematical examination of 1530 population. 83 were males and 47 were females. 60 patients (73 eyes) were operated and we made histopathological analyses.

## Results and Discussion

The results of histopathological analysis of the pterygium in population of island Rab is presented on figure 1. In several countries and regions, especially depending on geographical latitude, the pterygium is severe medical problem. This appearance is very significant on Mediterranean island Rab, with very high solar radiation, and significant increase of erythemal UV-Index.

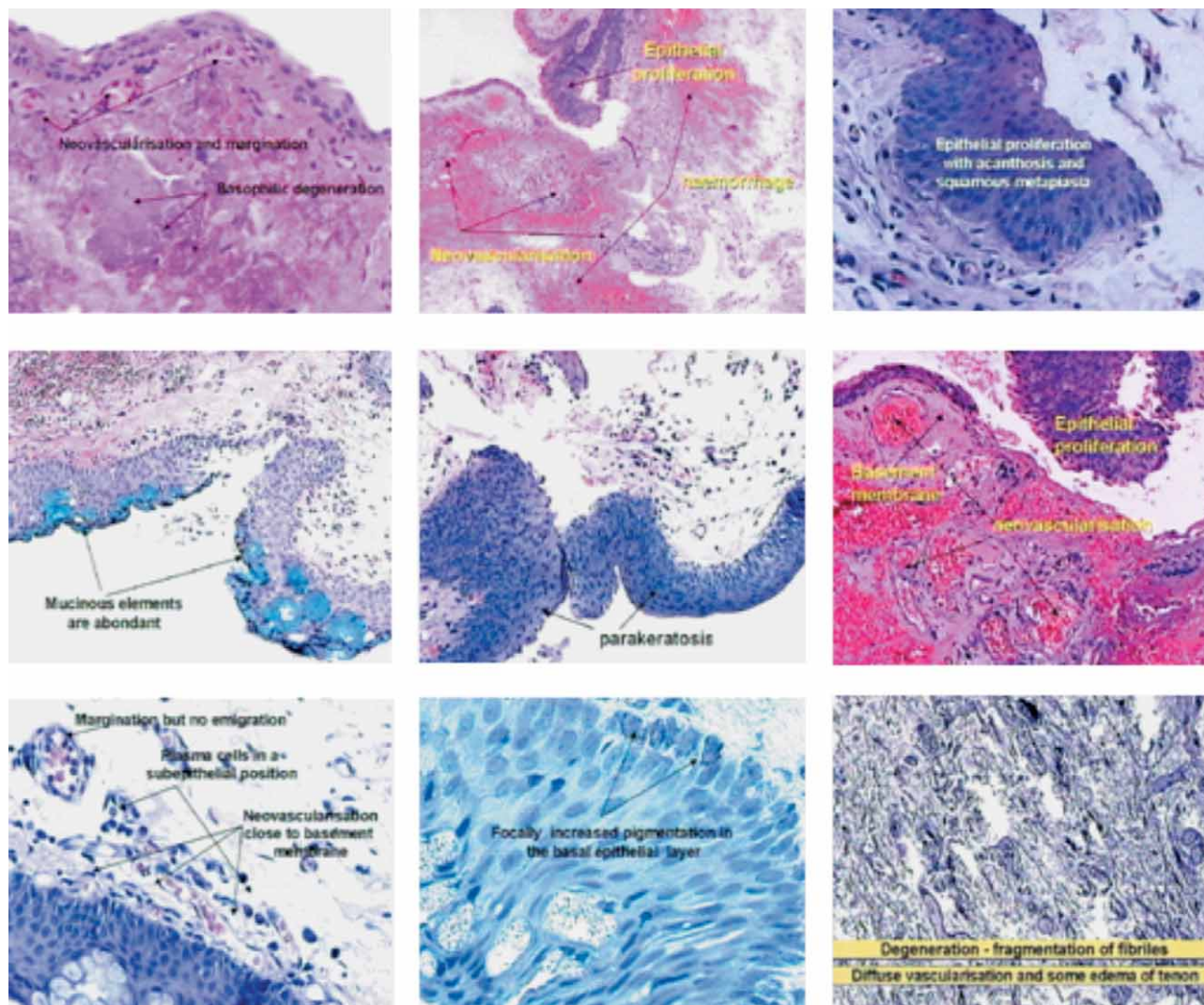


Fig. 1. Histopathological analysis of the pterygium in population of island Rab.

01. Conjunctiva with neovascularization and leukocyte margination and subepithelial basophilic degeneration. 02. Conjunctiva with epithelial proliferation, neovascularization and extravasation foci. 03. Conjunctiva with epithelial proliferation, acanthosis and squamous metaplasia. 04. Conjunctiva with epithelial proliferation and mucinous elements in the upper epithelial layers. 05. Conjunctiva with hyperkeratotic and parakeratotic epithelium. 06. Conjunctiva with epithelial proliferation, hyalinous thickening of basement membrane and subepithelial neovascularization. 07. Conjunctiva with epithelial proliferation and mucinous elements, subepithelial neovascularization, leukocyte margination and focally present plasma cells. 08. Conjunctiva with epithelial proliferation and foci of increased pigmentation in basal epithelial layers. 09. Tenon capsule with edema, diffuse neovascularization and fragmentation of fibrils.

In histopathological analysis in this examination of population on island Rab, significant are: neovascularisation, subepithelial basophilic degeneration, proliferation of conjunctival tissue, squamous metaplasia and acanthosis, focally present plasma cells, increased fo-

cuses of pigmentation in basal epithelial layers. Findings in Tenon's capsule: edema, diffuse neovascularisation and fragmentation of fibrils, we take very serious and they are very important for operating procedure technique.

## REFERENCES

1. URBACH F: The biologic Effects of Ultraviolet Radiation (Pergamon Press Ltd, London, 1969). — 2. VOJNIKović B: Einsteinov zakon elementarne fotokemijske reakcije (Veleučilište Velika Gorica, Zagreb, 2005.). — 3. LERMAN S: Radiant energy and the eye (MacMillan, New York, 1980). — 4. FORSIUS H, FORSMAN E, FELLMAN J, ERIKSSON AW, Acta Ophthalmol Scand 80 (2002) 478. — 5. RODNEY B: Concepts in Biochemistry (JohnWiley & Sons, Inc., Toronto, 2002). — 6. PENZAR B, PENZAR I, ORLIĆ M: Vrijeme i klima hrvatskog Jadrana («Dr. Feletar«, Koprivnica, 2001). — 7. LISAC I, Gospodarstvo i okoliš, 33 (1998) 381. — 8. KANC RP, Int J Climat 18 (1998) 457. — 9. MYRON Y, BEN SF: Ocular Pathology (J. B. Lippincott Company, Philadelphia, 1989). — 10. KWOK LS, CORONEO MT, Cornea, 13 (1994) 219.

*B. Vojniković*

*Eye Polyclinic »Dr. B. Vojniković«, Antuna Barca 3B, 51000 Rijeka, Croatia  
e-mail: decv@decv.com*

## HISTOPATOLOŠKA ANALIZA PTERIGIJA U PUČANSTVU OTOKA RABA

### SAŽETAK

U vremenu od 1975–2004. dijagnosticirano je na otoku Rabu 130 slučajeva pterigija, 83 u muškaraca i 47 u žena. Operativno je tretiran 41 pacijent, odnosno 73 očiju, s obzirom na obostrani proces. Kod svih slučajeva učinjen je histopatološki nalaz. Pored uobičajenog shvaćanja da se radi o elastoidnoj degeneraciji subepitelijuma i Bowmanove membrane, naši nalazi govore slijedeće: konjunktiva sa subepitelnom bazofilnom degeneracijom, proliferacija, akantoza sa skvamoznom metaplazijom. Zatim mucinozni elementi u gornjim slojevima epitela, hiperkeratoza i parakeratoza epitela, hijaloidno zadebljanje bazalne membrane, epitelna proliferacija s mucinoznim elementima, subepitelijalna neovaskularizacija, migracija leukocita i fokalna prisutnost plazma stanica. Proliferacija epitela konjunktive s fokusnom hiperpigmentacijom bazalnog sloja epitela. I na kraju, što je vrlo bitno, edem, difuzna neovaskularizacija i fragmentacija fibrila Tenonove kapsule. Upravo ovaj nalaz u Tenonovoj kapsuli vrlo je bitan za operativni pristup, jer naše iskustvo pokazuje da je neophodno uraditi i resekciju Tenona u širinu i osobito straga, da bi se bitno smanjio recidiv.