

Expression of Bone Morphogenetic Protein-7, It's Receptors and Smad1/5/8 in Normal Human Kidney and Renal Cell Cancer

Dean Markić¹, Tanja Čelić², Josip Španjol¹, Antun Gršković¹, Dragica Bobinac² and Željko Fučkar¹

¹ Department of Urology, University Hospital of Rijeka, Rijeka, Croatia

² Department of Anatomy, School of Medicine, University of Rijeka, Rijeka, Croatia

ABSTRACT

Bone morphogenetic proteins (BMPs) are cytokines which are important for kidney homeostasis but also have role in the some renal diseases and renal cell carcinoma (RCC)¹⁻⁵. In the last three decades incidence of RCC was constantly increased and the role of different molecular biomarkers in RCC is explored¹. We analyzed expression of BMP-7, their receptors (BMPR-IA, BMPR-IB, BMPR-II) and proteins of their signaling pathway (pSmad1/5/8) in sixteen renal cancer samples and paired normal tissue. Tissue samples were analyzed by immunohistochemistry and Western blot. BMP-7, BMP receptors and pSmad1/5/8 were expressed in all structures of normal kidney but dominantly in the proximal tubular cells. In the cancer samples their expression was also noticed. Comparison of BMPs between different tissue showed increased expression of BMPR-IB and pSmad 1/5/8 and decreased expression of BMP-7 and BMPR-II in RCC compared to normal kidney. BMPR-IA was detected with immunohistochemistry but with Western blot attenuated signal was presented. BMP-7, BMP receptors and pSmad1/5/8 were showed in normal kidney and RCC. Detected alterations of BMP-7, BMP receptors and pSmad expression in RCC suggested their possible role in tumorigenesis of kidney cancer.

Key words: kidney, bone morphogenetic proteins, renal cell carcinoma, epidemiology, pathology

Introduction

Bone morphogenetic proteins (BMPs) are members of transforming growth factor β (TGF- β) superfamily¹. They are classified according to their amino acid sequences into the following groups: 1) BMP-2 and BMP-4; 2) BMP-3 and BMP-3b; 3) BMP-5, BMP-6, BMP-7, BMP-8; 4) BMP-9, BMP-10; 5) BMP12, BMP-13 and BMP-14; and 6) BMP-11 and GDF-8². Like others members of TGF- β superfamily they transfer signal in the cell by two type of receptors: type I and type II. Type I receptors can be divided on the ALK-2 (Act-RI), ALK-3 (BMPR-IA), ALK-6 (BMPR-IB) and type II on the BMPR-II, ActR-II and ActR-IIB³. Inside the cell signal travels by Smad signaling pathway (dominant) and through mitogene activated protein-kinases (MAPKs), which include p38⁴. Activated receptor complexes recruit and phosphorylate Smad 1, 5 and 8, which also binds costimulatory protein Smad 4. Smad complexes then translocate into the nucleus where they act as transcription factors¹.

BMPs have important role in cellular differentiation, proliferation, apoptosis and morphogenesis⁵. In the prenatal life BMPs are involved in the development of many organs and tissues like skeleton, kidney, eyes, heart⁵. BMP-7 have essential role in kidney development⁵. After the birth BMPs are involved in maintaining of homeostasis in some organs like kidneys and have a role in pathophysiology of several diseases including osteoporosis, arthritis, kidney diseases, pulmonary hypertension, cerebrovascular diseases and cancer^{6,7}.

Renal cell carcinoma (RCC) accounting for about 3% of all adult cancers with the highest incidence in the more developed countries⁸. Kidney cancer is important urologic cancer because of its relative high lethality and increasing incidence. RCC is one of the most aggressive cancers among urologic malignancies and approximately 30% patients undergoing radical nephrectomy will de-

velop metastases⁹. The earlier discovery and increased detection has occurred since the advent of ultrasonography, computed tomography and magnetic resonance imaging (MRI)¹⁰. According to the 2004 WHO classification there are three main histopathologic subtypes with distinct clinical behavior: conventional (clear cell), papillary and chromophobe RCC¹¹. Prognosis of patients with RCC is predicted by TNM stage, Fuhrman nuclear grading system and histological subtype¹².

Recent researches of BMPs showed their important role in carcinogenesis of different cancers like prostate, breast, lung and colon^{13–15}. The role of BMP in the kidney cancer is still under the investigation^{16–26}.

Since, BMPs have role in tumorigenesis of different carcinomas, we investigated the expression pattern of BMP-7, BMPRI-IA, BMPRI-IB, BMPRI-II and phosphorylated Smad 1/5/8 (pSmad1/5/8) in healthy human renal tissue and RCC.

Patients and Methods

Tissue samples

Sixteen renal cancer samples and matched controls of normal tissue (taken far from the tumor site) were taken immediately after nephrectomy and frozen in liquid nitrogen at -80°C . For immunohistochemistry same tissue samples were fixed in 4% buffered formalin. Tissue samples were acquired from the Department of Urology, University Hospital Center in Rijeka, Croatia. Hospital and university local ethical committee approved the study. Written informed consent and approval were obtained from all patients. Out of 16 patients 8 were diagnosed with clear cell carcinoma, other 8 had non-clear cell types and among them 6 had papillary and 2 chromophobe type. Pathological stage and tumor grade were diagnosed according to TNM classification and the Fuhrman nuclear grading status.

Tissue microarrays construction

Tissue microarrays containing samples of 16 tumors and paired normal tissue were constructed. Five core biopsies with a diameter of 2 mm were obtained from each tumor from a histologically representative area.

Immunohistochemistry

Immunohistochemistry was carried out on $3\ \mu\text{m}$ formalin-fixed and paraffin-embedded kidney tissue sections. Sections were deparaffinized and treated with 0.3% hydrogen peroxidase for 10 minutes at room temperature to block endogenous peroxidase. Slides were incubated with phosphate-buffered saline (PBS) containing 10% bovine serum albumin for 30 minutes at room temperature to avoid nonspecific binding. In the following step the sections were incubated with goat polyclonal antibody raised against human BMP-7, BMPRI-A, BMPRI-B and BMPRI-II (all diluted to 1:100, from Santa Cruz Biotechnology, California, USA), left overnight at 4°C . For pSmad 1/5/8 (Cell Signaling, Massachusetts, USA)

staining we performed antigen retrieval in 0.1M citric acid, pH 7.2, for 15 minutes in microwave and then applied antibody 1:100 dilution overnight at 4°C . All slides were incubated with horseradish peroxidase (HRP)-conjugated rabbit anti-goat secondary antibody (DakoCytomation, Glostrup, Denmark) and ABC reagent for 30 minutes at room temperature. The specimens were washed with PBS three times for 10 minutes after each step and signal was detected using diaminobenzidine (DAB). Finally, sections were counterstained with hematoxylin. As a control, PBS was used in place of the primary antibody.

Western blot analysis

Tissue was homogenized in lysis buffer (1% Triton x-100, 0.5 Sodium deoxycholate, 0.1% SDS, 0.1 mM phenylmethylsulfonyl fluoride) and stored at 4°C for 30 minutes. After centrifugation at 13.000 rpm at 4°C for 30 minutes, supernatant was collected and protein concentration determined by Bradford method. Samples were boiled for 5 minutes and equal amount of total protein from each sample ($40\ \mu\text{g}$) were loaded and electrophoresed on 12 % SDS polyacrilamide gel (200 V, 35 minutes). After electrophoresis, the proteins were transferred to nitrocellulose membrane and incubated with 5% skim milk in TBS containing 0.05% Tween-20 for 60 minutes at room temperature. The primary antibody for BMP-7, BMPRI-A, BMPRI-B, BMPRI-II (Santa Cruz Biotechnology, California, USA) and pSmad 1/5/8 (Cell Signaling, Massachusetts, USA) was prepared at 1:200 dilution at 4°C overnight, followed by a horseradish peroxidase conjugated secondary antibody for 60 minutes at room temperature. The membranes were washed with TBS-T three times for 15 minutes after each step. Immunoreactive bands were detected using enhanced chemiluminescence reagents (ECL; Amersham, Buckinghamshire, UK) and visualized using Kodak BioMax MS film (Sigma-Aldrich Corporation, Missouri, USA). As internal loading control the blots were re-probed for β -actin (Santa Cruz Biotechnology, California, USA). The signal intensity of the protein product was quantified by densitometry (Kodak Image Station 440, LabImage, Halle, Germany). The relative expression level of the BMP-7, BMP receptors and pSmad1/5/8 was calculated as the ratio between their expression and expression of β -actin and multiplied by one hundred.

Statistics

Statistical analysis was conducted using software, Statistica 6.1 (StatSoft Inc., Tulsa, USA). Results were presented as mean (X) \pm standard error of mean (SEM). Student t-test was used to compare relative expression of different proteins between normal kidney and RCC. Difference were considered statistically significant with $p < 0.05$.

Results

In normal kidney tissue BMP-7 had strong expression in the cytoplasm of proximal tubular cells. Distal tubular cells had much lower expression of BMP-7 and glomeruli had scarce expression of BMP-7. The same localization of immunoreactive staining was noticed when we applied BMPR-IA, BMPR-IB and BMPR-II antibody. BMPR-IA intensity of staining was very weak. BMP signaling pathway was also confirmed in normal kidney tissue through pSmad 1/5/8 positive reaction observed as cytoplasmatic and nuclear staining. Distribution of expression was similar as for BMP-7.

In renal carcinoma BMP-7 and receptors were detected as diffuse staining in cytoplasm of cells, both in clear cell carcinoma and non clear cell types. Also, pSmad 1/5/8 positivity in carcinoma was localized in cytoplasm and nucleus, confirming that BMP signaling pathway is active both in normal and carcinoma affected tissue.

Western blot analysis detected BMP-7, BMPR-IB, BMPR-II and pSmad 1/5/8 in normal kidney and in RCC (Figure 1). Their expression was present in all types of RCC (data not shown). In tumor samples expression of BMPR-IB and pSmad 1/5/8 were increased compared to normal tissue (Table 1). BMP-7 and BMPR-II were increased in healthy renal parenchyma. BMPR-IA was not presented with adequate signal in both type of tissue and their analysis was not possible. BMP-7 has lower expression in cancer tissue (regarding subtype) than in healthy kidney. Differences in relative expression between BMP-

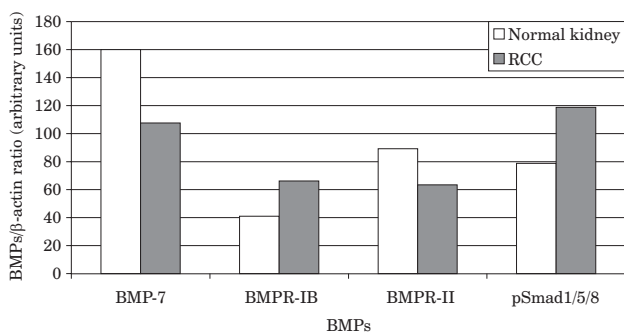


Fig. 1. Expression of BMP-7, BMPR-IB, BMPR-II and pSmad1/5/8 in normal kidney and renal cell cancer (RCC). Term BMPs included BMP-7, BMPR-IB, BMPR-II and pSmad1/5/8.

TABLE 1
AVERAGE EXPRESSION (IN ARBITRARY UNITS) OF BMP-7, BMPR-IB, BMPR-II AND PSMAD1/5/8 IN NORMAL KIDNEY AND RENAL CELL CANCER

	BMP-7 (X±SEM)	BMPR-IB (X±SEM)	BMPR-II (X±SEM)	pSmad1/5/8 (X±SEM)
Normal kidney	160.0±48.9	41.0±16.1	89.2±16.7	78.8±20.1
RCC	107.6±53.2	66.1±30.3	63.4±20.4	118.8±30.2
p-value	0.482 (NS)	0.486 (NS)	0.350 (NS)	0.297 (NS)

RCC – renal cell cancer, NS – non significant, X±SEM – mean±standard error of mean

-7, BMPR-IB, BMPR-II and pSmad 1/5/8 in normal kidney and RCC were not statistically significant (Table 1).

Discussion and Conclusion

BMP-7 is a member of the TGF- β superfamily and plays important role during kidney development but also in adult kidney physiology and pathophysiology of renal diseases. In fetal period BMP-7 is expressed multifocally within the embryonic metanephric mesenchyme and ureteric bud epithelia⁵. BMP-7 knockout mice die owing to renal failure perinatally as a result of severe kidney dysplasia⁵. In normal rat kidney the highest expression of BMP-7 mRNA is found in tubular epithelial cells of the outer medulla and in glomerular epithelial cells. Other parts of nephron had lower expression¹⁸. Also, high BMP-7 mRNA expression is located in adventitia of renal arteries as in epithelial cell layer of renal pelvis and the ureter¹⁸. The expression of BMP receptors is found in the cortex area (glomeruli, convoluted tubule epithelium) and in medulla (collecting ducts)^{18,19}. Receptor expression was higher in the kidney cortex than in medulla¹⁹. Wetzel et al. found that in the human adult normal kidney BMP-7 is predominantly localized to the distal nephron: epithelia of distal tubule and collecting ducts²⁰. Expression of phospho-Smads1/5/8 was colocalized with expression of BMP-7²⁰.

Our data indicated that in the normal human kidney tissue BMP-7 was mainly localized in cytoplasm of proximal tubular cells. The same localization was found for BMPR-IA, BMPR-IB, BMPR-II and pSmad1/5/8. The results of our investigations are partly different from the work of Wetzel et al. where BMP-7 and their receptors are found mostly in the distal nephron²⁰. Kwak et al. confirmed, as in our study, dominant expression of BMP-7 in the proximal tubular cells¹⁷. The possible explanation is that expression of BMP-7 can vary in the kidney specimens because of influence of different factors: environmental, genetics or disease. We must mention that our normal kidney specimens were from the kidney with RCC (same as in the other studies). Also investigation on greater number of kidney specimens is mandatory (we examined sixteen and Wetzel et al. only six normal specimens)²⁰. In only one study immunohistochemistry was used with microdissection of renal tissue to establish exact localization²⁰. Multi-institutional study with greater

number of healthy renal parenchyma samples and with microdissection of tissue will potentially show localization of BMPs and their receptors in the normal kidney.

When we analyzed relative expressions of BMPs it is obvious that BMP-7 have highest expression, especially in the normal kidney. This is in concordance with observation that BMP-7 plays important role in the human kidney^{1,2,5}.

In the recent years dysregulation of BMP signaling in carcinogenesis has been linked to different types of cancers. Both up- and down-regulation of BMPs and their receptors have been reported in association with the progression of a variety of solid tumors. For example BMP-4 is increased in colonic adenocarcinoma, BMP-2 is highly overexpressed in lung cancers, BMP-2, BMPR-IA and BMPR-II are all up-regulated in pancreatic cancer samples, BMP-4 and BMP-7 are overexpressed in myeloma cells, Noggin (BMP antagonist) is down regulated and BMP-4 is up-regulated in prolactinoma, BMPR-II is up-regulated in bladder transitional cell carcinoma, BMP-2 is down regulated in the microadenomas of familial adenomatous polyposis patients, BMP-4 is down-regulated in ACTH-secreting pituitary adenoma, BMP-3b and BMP-6 are silenced in lung cancers²¹. Also studies which have been carried out to test the possible effects of BMPs on tumor cell proliferation and apoptosis showed both growth inhibitory and stimulatory effects. For example BMP-2 have stimulatory effect on lung cancer cells but inhibitory effect on breast cancer cells¹⁴. Such inconsistencies probably stem from the complex network of interactions in the BMP signaling cascades and possibly from the tissue specific differences.

Kwak et al. analyzed 185 kidney tumor specimens and showed their positive expression for BMP-4 in 44.3% specimens, BMP-6 in 20% and BMP-7 in 34.1%¹⁷. When the clinical data were examined there was no statistically significant association between BMP and age, ECOG performance status and tumor stage. Disease-free survival was higher in patients with chromophobe subtype of kidney cancer and BMP-7 positive expression. In this subgroup of patients BMP-7 may be considered as a new prognostic factor.

REFERENCES

1. CHEN D, ZHAO M, MUNDY GR, Growth factors, 22 (2004) 233. —
2. SAMARTZIS D, KHANNA N, SHEN FH, AN HS, J Am Coll Surg, 200 (2005) 236. —
3. WOZNEY JM, Spine, 27 (2002) 2. —
4. HASSEL S, SCHMITT S, HARTUNG A, ROTH M, NOHE A, PETERSEN N, EHRlich M, HENIS YI, SEBALD W, KNAUS P, J Bone Joint Surg Am, 85 (2003) 44. —
5. SIMIC P, VUKICEVIC S, Cytokine Growth Factor Rev, 16 (2005) 299. —
6. YANAGITA M, Cytokine Growth Factor Rev, 16 (2005) 309. —
7. BOBINAC D, SPANJOL J, MARINOVIC M, ZORICIC C, VUK S, MARIC I, CVCARIC T, FUCKAR D, MARKIC D, VOJNIKOVIC B, Coll Antropol, 32 (2008) 83. —
8. JEMAL A, TIWARI RC, MURRAY T, GHAFOR A, SAMUEL A, WARD E, FEUER EJ, THUN MJ, CA Cancer J Clin, 54 (2004) 8. —
9. JANZEN NK, KIM HL, FIGLIN RA, BELLDEGRUN AS, Urol Clin Nort Am, 30 (2003) 843. —
10. TSUI KH, SHVART O, SMITH RB, FIGLIN R, DE KERNION JB, BELLDEGRUN A, J Urol, 163 (2000) 426. —
11. EBLE JN, TOGASHI K, PISANI P, Renal cell carcinoma. In: EBLE JN, SAUTER G, EPSTEIN JI, SESTERHENN IA (Eds): Pathology and genetics of tumors of the urinary system and male genital organs.

To our knowledge, our study was first which investigated expression differences of BMP-7 and pSmad1/5/8 between normal kidney and RCC. Analysis showed that kidney cancer tissue has lower expression of BMP-7 and higher expression of pSmad1/5/8 than normal adult human kidney. The possible influence of BMP-7 in different cancers was noticed. It was shown that BMP-7 have dose dependent growth inhibition in thyroid carcinoma and myeloma cell lines^{22,23}. Also BMP-7 was highly expressed in a breast cancer sample but not in normal breast tissue¹³. Since in examined samples of RCC BMP-7 expression was decreased, but not statistically significant, some effect of BMP-7 on RCC tumorigenesis probably exist but more proofs are needed. The further analysis with RCC cancer lines can lighten possible stimulatory or inhibitory influence of BMP-7 on the cancer cells. It was already shown that Smad signaling enhances invasion and bone metastasis of breast cancer²⁴. Increased activity of pSmad1/5/8 in our samples showed that BMP/Smad signaling pathway is active in RCC.

Kim et al. investigated the role of BMP receptors in renal cell carcinoma cells¹⁶. Results from his study showed that kidney cancer cells have decreased levels of BMPR-II expression. This result was confirmed in our study where decreased expression of BMPR-II in RCC was noticed. Another detected receptor, BMPR-IB was higher expressed in the RCC samples. Also BMP-6 has *in vitro*, inhibitory effect on growth of tumor cells of RCC but only in cancer cells with present BMPR-II¹⁶. Probably, decreased expression of BMPR-II have important role in the carcinogenesis of kidney cancer. Alterations in expression of BMP receptors and pSmad suggested that BMP signaling pathway is affected in RCC.

In conclusion, our results showed that BMP-7, their receptors and pSmad1/5/8 are present in the proximal and distal part of nephron in the normal human kidney. RCC have lower expression of BMP-7 and BMPR-II and higher expression of BMPR-IB and pSmad1/5/8 than normal kidney. Obviously BMP and their signaling pathway is involved in the kidney cancer carcinogenesis.

- World Health Organization Classification of Tumors (IARC Press, Lyon, 2004). —
12. PATARD JJ, LERAY E, RIOUX-LECLERCQ N, CINDOLO L, FICARRA V, ZISMAN A, DE LATAILLE A, TOSTAIN J, ARTIBANI W, ABOU CC, LOBEL B, GUILLE F, CHOPIN DK, MULDER PF, WOOD CG, SWANSON DA, FIGLIN RA, BELLDEGRUN AS, PANTUCK AJ, J Clin Oncol, 23 (2005) 2763. —
13. BOBINAC D, MARIC I, ZORICIC S, SPANJOL J, DORDEVIC G, MUSTAC E, FUCKAR Z, Croat Med J, 46 (2005) 389. —
14. LANGENFELD EM, BOJNOWSKI J, PERONE J, LANGENFELD J, Ann Thorac Surg, 80 (2005) 1028. —
15. DENG H, MAKIZUMI R, RAVIKUMAR TS, DONG H, YANG W, YANG WL, Exp Cell Res, 313 (2007) 1033. —
16. KIM IY, LEE DH, LEE DK, KIM BC, KIM HT, LEACH FS, LINEHAN WM, MORTON RA, KIM SJ, Clin Cancer Res, 9 (2003) 6046. —
17. KWAK C, PARK YH, KIM IY, MOON KC, KU JH, J Urol, 178 (2007) 1062. —
18. SIMON M, MARESH JG, HARRIS SE, HERNANDEZ JD, ARAR M, OLSON MS, ABOUD HE, Am J Physiol, 276 (1999) 382. —
19. BOSUKONDA D, SHIH MS, SAMPATH KT, VUKICEVIC S, Kidney Int 58 (2000) 1902. —
20. WETZEL P, HAAG J,

CÁMPEAN V, GOLDSCHMEDING R, ATTALA A, AMANN K, AIGNER T, *Kidney Int*, 70 (2006) 717. — 21. LI B, *Endocr Metab Immune Disord Drug Targets*, 8 (2008) 208. — 22. FRANZÉN A, HELDIN NE, *Biochem Biophys Res Commun*, 285 (2001) 773. — 23. RO TB, HOLT RU, BRENNER AT, HJORTH-HANSEN H, WAAGE A, HJERTNER O, SUNDAN A, BORSET M, *Oncogene*, 23 (2004) 3024. — 24. KATSUNO Y, HANYU A, KANDA H, ISHIKAWA Y, AKIYAMA F, IWASE T, OGATA E, EHATA

S, MIYAZONO K, IMAMURA T, *Oncogene*, 27 (2008) 6322. — 25. MO-KOS I, BERNAT MM, MAREKOVIC Z, PASINI J, *Coll Antropol*, 29(2) (2005) 753. — 26. SMOLJANOVIC T, GRGUREVIC L, JELIC M, KRESZINGER M, HASPL M, MATICIC D, VUKICEVIC S, PECINA M, *Coll Antropol*, 31(3) (2007) 923.

D. Markić

Department of Urology, University Hospital »Rijeka«, Tome Strižića 3, 51 000 Rijeka, Croatia
e-mail: dean.markic@ri.htnet.hr

IZRAŽAJ KOŠTANOG MORFOGENETSKOG PROTEINA-7, NJегоVIH RECEPTORA I SMAD1/5/8 U NORMALNOM BUBREGU I KARCINOMU BUBREŽNIH STANICA U ČOVJEKA

SAŽETAK

Koštani morfofenetski proteini (BMPs) su citokini koji su važni za održavanje homeostaze bubrega ali također imaju ulogu u bubrežnim bolestima i karcinomu bubrežnih stanica (RCC)^{1–5}. U posljednja tri desetljeća učestalost RCC neprestano raste a ujedno se istražuje i uloga različitih tumorskih biomarkera u RCC¹. Analizirali smo izražaj BMP-7, BMP receptora (BMPR-IA, BMPR-IB, BMPR-II) kao i izražaj proteina koji sudjeluju u signalnom putu (pSmad1/5/8). Analizirali smo šesnaest uzoraka karcinoma i normalnog tkiva bubrega koristeći se imunohistokemijom i Western blot metodom. BMP-7, BMP receptori i pSmad1/5/8 bili su ekspimirani u svim dijelovima nefrona normalnog bubrega ali najviše u stanicama proksimalnog tubula. U uzorcima karcinoma bubrega također je zabilježena njihova ekspresija. Usporedbom ekspresije između raličitih tkiva prikazali smo povećanu ekspresiju BMPR-IB i pSmad 1/5/8 te smanjenu ekspresiju BMP-7 i BMPR-II u RCC u odnosu na normalni bubreg. BMPR-IA je prikazan imunohistokemijskom metodom ali je oslabljen signal bio nedovoljan za analizu Western blotom. BMP-7, BMP receptori i pSmad1/5/8 su ekspimirani u normalnom bubregu i u RCC. Prikazane promjene u izražaju BMP-7, BMP receptora i pSmad1/5/8 u RCC govore u prilog njihove moguće uloge u tumorigenezi karcinoma bubrega.