

Delayed presentation of a traumatic diaphragmatic hernia

CHI-TUN TANG • MING-YING LIU • CHI-TUN TANG

MING-YING LIU (✉)
Department of Emergency Medicine
Tri-Service General Hospital
#325, Cheng-Kung Road, Section 2
Taipei 114, Taiwan, Republic of China
Phone: +886-2-8792-7177
Fax: +886-2-8792-7178
E-mail: omeprazon8@hotmail.com

CHI-TUN TANG •
MING-YING LIU •
CHI-TUN TANG
Department of Neurological Surgery

MING-YING LIU
Department of Emergency Medicine
Tri-Service General Hospital, National
Defense Medical Center, Taipei, Taiwan
Republic of China

ABSTRACT

Delayed presentation of a traumatic diaphragmatic hernia is an infrequent condition with a high mortality and morbidity rate. This case describes a 26-year-old man presenting with a 2-day history of cramping abdominal pain, dyspnea, nausea, and vomiting. The patient reported a penetrating thoracic injury one year prior to the development of clinical signs. Computed tomography revealed the presence of empyema or parapneumonic effusion of the left hemithorax. Based on the clinical history and physical findings, a diaphragmatic hernia was considered and an emergency laparotomy with segmental resection of strangulated jejunum and reduction of remaining bowel was performed. A 1.5 cm tendinous defect was identified and repaired. The patient recovered and was discharged uneventfully.

Conclusion: the early recognition of a delayed diaphragmatic hernia contributed to the uneventful recovery of this critically ill patient.

Key words: traumatic diaphragmatic hernia, penetrating thoracic injury, helical computed tomography, emergent laparotomy, tendon defect

Introduction

A traumatic diaphragmatic hernia was first reported by Ambrose Pare in 1579 and the patient he described survived for only eight months due to the development of gangrenous loops of bowel. (1,2) As many as 0.8-1.6 % of blunt trauma cases result in diaphragmatic hernia; however, in cases of penetrating injury and thoracoabdominal trauma, the incidence of diaphragmatic hernia increases to 70-90%. (3) Unfortunately, the defects created by many penetrating injuries, particularly stab wounds,

are more difficult to diagnose immediately compared to large tears that typically occur following blunt ruptures of the diaphragm.

Spontaneous closure of a rupture does not occur, but temporary occlusion by muscular contraction or omental interposition has been reported. (4) The negative intrathoracic pressure during inspiration is presumed to result in the gradual herniation of intraabdominal organs into the thorax. A small defect can enlarge and increase the volume of herniation. If a traumatic diaphragmatic hernia is not treated early, the risk for organ herniation and strangulation is increased. (5) The delayed diagnosis of diaphragmatic injuries following a penetrating injury is relatively rare, but

remains a persistent problem in trauma centers. (6) For patients with a history of prior penetrating trauma, complaining of new epigastric pain, a delayed diaphragmatic hernia should always be considered, as evidenced by this case.

Case Report

A 26 year old man presented with a two day history of cramping abdominal pain, dyspnea, nausea, and vomiting. The patient reported a penetrating injury to the lower chest one year prior to this episode. On physical examination, modest epigastric tenderness, flat palpitation of the lower abdomen, rigidity, rebounding pain, and decreased bowel sounds were noted. Decreased

breath sounds were noted on the left side of the thorax. Laboratory findings revealed a neutrophilic leukocytosis and the arterial blood gases disclosed hypoxemia and desaturation despite oxygen supplementation via a nasal cannula. Thoracic radiographs (figure 1) showed increased opacity along the left lower hemithorax and blunting of the costophrenic angle, whereas computed tomography (figure 2) revealed fluid accumulation in the left lower thorax accompanied by a soft tissue component, implying consolidated pneumonia or empyema.

In light of the increasing abdominal pain, a diaphragmatic hernia was diagnosed and an emergency laparotomy was performed. Approximately 130 cm of jejunum was incarcerated in the left hemithorax via a 1.5 cm diaphragmatic defect at the boundary between the tendinous and muscular parts. A 103 cm non-viable section of jejunum was resected and reconstructed with an end-to-end anastomosis. A 32-Fr chest tube was placed parallel to the diaphragm and the incisional wound was left patent for two weeks, then repaired. The patient was discharged uneventfully three weeks post-operatively.

Discussion

Vigorous forces focused on the wide surface of the abdomen and thorax contribute to the majority of diaphragmatic hernias. (4) In blunt traumas, the abrupt change in intraabdominal pressure produces the injury, either as a laceration or an avulsion. The rupture typically originates at the central tendineum or musculotendinous junction. (5) Approximately 68.5% of these tears occur on the left side; however, 24.2% are on the right and 1.5% are bilateral. The left-sided predominance is presumed to be attributable to the relative weakness of the left hemidiaphragm and the protective effect of the liver on the right side. (7) Penetrating traumas behave more randomly and produce smaller holes (usually less than 1 cm in diameter), especially for stab injuries. Since most assailants are right handed,

left-sided diaphragmatic hernias are reported three to five times more frequently than the right side. (5) Presenting complaints include new or vague abdominal pain, nausea, vomiting, dyspnea, and shoulder or chest pain. Some patients may remain symptom-free even at the time of diagnosis. (8)

Diagnostic tools include plain thoracic radiographs, upper gastrointestinal contrast studies, diagnostic peritoneal lavage, fluoroscopy, ultrasound, computed tomography, magnetic resonance imaging, intraperitoneal injection of radioisotopes, laparotomy, and video-assisted thoracic surgery. (4,9-12) There is no single definite modality advocated for diagnosing traumatic diaphragmatic hernias; however, the most commonly employed imaging methods are thoracic radiographs and computer tomography. Interestingly, only 25-50% of initial chest films are diagnostic. (13,14) The sensitivity and specificity of computed tomography are 33-83% and 76-100%, respectively. (12,14) As such, computed tomography is the diagnostic test of choice in suspected hernia patients.

In the patient described above, no definite diagnosis was achieved until the time of surgery, despite the use of advanced imaging modalities. The presumptive diagnosis of a delayed diaphragmatic hernia was probably made thanks to the experience of the attending general surgeon. Suspicion of a diaphragmatic hernia is an indication for surgical repair. (4)

Most traumatic diaphragmatic hernias are symptomatic within two weeks of occurrence. The major reasons for delay in symptoms in the patient described herein may have occurred due to the temporary "plugging" of the diaphragmatic defect by the omentum, which was not able to prevent symptomatic visceral herniation from occurring months later. (15) A significant penetrating injury of the diaphragm is often undetected within 24 hours and thoracic radiographs of these patients are frequently normal. Strangulation of bowel occurs as much as 80% of the

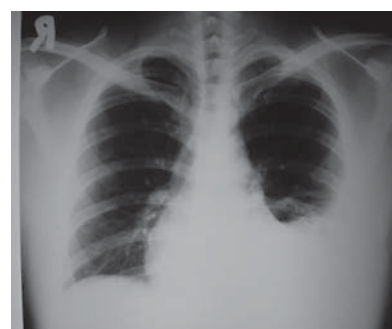

Figure 1. Plain chest radiograph with increased opacity along the left lower hemithorax and blunting of the costophrenic angle.

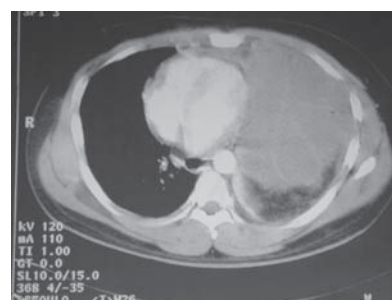


Figure 2. Thoracic computed tomography identified the collection of fluids in the left lower thorax in combination with soft tissue component. A consolidated pneumonia and empyema were considered as potential differential diagnoses.

time and responsible for the majority of deaths. The degree of gangrene intensifies with an increasing time interval between visceral herniation and diagnosis. Delayed presentation of a diaphragmatic hernia should be considered in patients with prior history of penetrating trauma involving either the lower chest or upper abdomen presenting with acute signs of intestinal obstruction. (7,11) The definite treatment of traumatic diaphragmatic hernia is surgical repair with optional resection of non-viable bowel segment and the transabdominal approach is now agreed by most to be superior to the transthoracic route. (4,8,11) Early consideration of a delayed diaphragmatic hernia, as a potential differential diagnosis, contributed to the successful and uneventful recovery of this patient.

REFERENCES

1. Hanby WB. *The Case Report and Autopsy Records of Ambroise Pare*. Springfield, Illinois: Charles C Thomas, 1968;50-1.
2. Troop B, Myers RM, Agarwal N. Early recognition of diaphragmatic injuries from blunt trauma. *Ann Emerg Med* 1985;14:97-101.
3. Moore JB, Moore EE, Thompson JE. Abdominal injuries in association with penetrating trauma to the lower chest. *Am J Surg* 1980;140:724-30.
4. Schumpelick V, Steinau G, Schlüper I, Prescher A. Surgical embryology and anatomy of the diaphragm with surgical applications. *Surg Clin North Am* 2000;80:213-39.
5. Shackleton KL, Stewart ET, Taylor AJ. Traumatic diaphragmatic injuries: spectrum of radiographic findings. *Radiographics* 1998;18:49-59.
6. Windsor HM. The delayed-action stab. *Br Med J* 1957;1:1344-5.
7. Mihos P, Potaris K, Gakidis J, Panagiotis V, Gougoutas B, Papadakis G, et al. Traumatic rupture of the diaphragm: experience with 65 patients. *Injury* 2003;34:169-72.
8. Kulstad EB, Pisano MV, Shirakbari AA. Delayed presentation of traumatic diaphragmatic hernia. *J Emerg Med* 2003;24:455-7.
9. Scaglione M, Grassi R, Pinto A, Ragozzino A, Romano S, Pinto F. Delayed presentation of traumatic left-sided diaphragmatic avulsion. A case report. *Acta Radiol* 2000;41:165-6.
10. Degiannis E, Levy RD, Sofianos C, Potokar T, Florizoone MG, Saadia R. Diaphragmatic herniation after penetrating trauma. *Br J Surg* 1996;83:88-91.
11. Feliciano DV, Cruse PA, Mattox KL, Bitondo CC, Burch JM, Noon CP, et al. Delayed diagnosis of injuries to the diaphragm after penetrating wounds. *J Trauma* 1988;28:1135-44.
12. Worthy SA, Kang EY, Hartmen TE, Kwong JS, Mayo JR, Muller NL. Diaphragmatic rupture: CT findings in 11 patients. *Radiology* 1995;194:885-8.
13. Reber PU, Schmied B, Seiler CA, Baer HU, Patel AG, Buchler MW. Missed diaphragmatic injuries and their long-term sequelae. *J Trauma* 1998;44:183-8.
14. Murray JG, Caoili E, Gruden JF, Evans SJ, Halvorsen RA Jr, Mackersie RC. Acute rupture of the diaphragm due to blunt trauma: diagnostic sensitivity and specificity of CT. *AJR* 1996;166:1035-9.
15. Grimes OF. Traumatic injuries of the diaphragm: diaphragmatic hernia. *Am J Surg* 1974;128:175-81.