

Department of Gynecology and Obstetrics, Clinical Hospital »Sveti Duh«;*
Department of Gynecology and Obstetrics, University Hospital Zagreb;**
Department of Surgery, Clinical Hospital Dubrava***, Zagreb, Croatia

LIFE THREATENING VASA PRAEVIA: THREE DIFFERENT CASES AND OUTCOMES

ŽIVOTNO UGROŽAVAJUĆA VAZA PREVIJA: TRI RAZLIČITA SLUČAJA I ISHODA

Vladimir Blagaić,* Ivana Erceg Ivkošić,* Nenad Veček,**
Mario Kopljar,*** Damir Žalac,* Berivoj Mišković**

Prikaz bolesnica

Key words: vasa praevia, velamentous cord insertion, pregnancy outcome, prenatal diagnosis, color doppler sonography

SUMMARY. Objective. To enlighten vasa praevia as a rare complication of pregnancy associated with a high rate of fetal and neonatal mortality. Early detection of this condition is crucial for planning the therapeutic approach to prevent fetal and neonatal risks. **Methods and results.** We report three different cases of vasa praevia: the one that was recognized during labor immediately after amniotomy, causing life threatening hemorrhage and emergency cesarean section with good neonatal outcome; second case where vasa praevia were diagnosed in prenatal period during amnioscopy confirmed by color doppler sonography, enabling elective cesarean section with no consequences; the third case were unrecognised vasa praevia followed by emergency cesarean section and neonatal death. **Conclusion.** Vasa praevia remains an unpredictable cause of fetal or neonatal death even though it can be relatively easily diagnosed in prenatal period either by color doppler sonography, amnioscopy or magnetic resonance.

Case report

Ključne riječi: vaza previa, velamentozna insercija pupkovine, ishod trudnoće, prenatalna dijagnostika, ultrazvučni pregled u boji

SAŽETAK. Cilj rada. Dodatno rasvijetliti vaza previja koja su rijetka komplikacija trudnoće povezana s visokom stopom fetalne ili neonatalne smrtnosti. Rano otkrivanje ovog stanja je od presudne važnosti za planiranje terapijskih postupaka kako bi se spriječili fetalni i neonatalni rizici. **Metode i rezultati.** Predstavljamo tri različita slučaja vaza previja: jedan koji je prepoznat za vrijeme poroda, neposredno nakon amniotomije, uzrokujući po život opasno krvarenje i hitan carski rez, s dobrim ishodom; drugi slučaj kod kojeg su vaza previja dijagnosticirana prenatalno amioskopijom i dijagnoza potvrđena ultrazvučnim pregledom u boji, omogućivši elektivni carski rez bez posljedica; i treći slučaj neprepoznatih vaza previja pri kojim je napravljen hitni carski rez, ali s vrlo skorom smrću novorođenčeta. **Zaključak.** Vaza previa ostaju uzrok fetalne i neonatalne smrti kojeg je teško predvidjeti iako ga je relativno lako dijagnosticirati u prenatalnom razdoblju bilo ultrazvučnim pregledom u boji, amioskopijom ili magnetskom rezonancijom.

Introduction

Vasa praevia are seldom seen. They are dangerous complication since the unprotected umbilical vessels pass through the fetal membranes in front of the presenting part of the fetus. The incidence of vasa praevia is around 1:3000 pregnancies.¹ Risk factors for vasa praevia include a placental edge over the internal os recorded by an earlier scan, multiple gestation, velamentous cord insertion, bilobate or succenturiate placenta² and aberrant vessels. Umbilical cord insertion to the lower uterine segment presents also a high risk for vasa praevia.³ Unrecognized vasa praevia may cause painless vaginal bleeding during labor followed by fetal hemorrhagic shock and fetal asphyxia. This condition has a high fetal mortality rate due to fetal exsanguination resulting from fetal vessels tearing when the membranes rupture,¹ spontaneously or after amniotomy. Mortality of unrecognized vasa praevia had remained high since was first described in 1831. It is reported the mortality to be as high as 75–100%.¹ However, when is diagnosed during prenatal examination mortality rate is very low.

Routine prenatal color doppler sonography⁴ and amnioscopy⁵ significantly improve the diagnosis of vasa praevia and allow planned cesarean section, avoiding obstetric complications. We described three different cases of vasa praevia with various management and outcome.

Case 1

A 30-year-old laboring woman, gravida 3, para 0, abortion 2, at 35 weeks of gestation, had an episode of intrapartum bleeding after amniotomy. Labor progressed slowly to 8-cm of cervical dilatation followed by protraction disorder of active labor. Amniotomy was performed for stimulation of labor, resulted in blood discharge of approximately 50 mL accompanied by variable decelerations of fetal heart rate with sinusoidal record to under 70 beats/min (*Figure 1*). Therefore, ruptured vasa praevia were right away suspected. Emergency cesarean section was immediately performed. Intraoperative findings include velamentous insertion of the umbilical vessels on the posterior wall of the uter-




Figure 1. Cardiotocography pattern before and after amniotomy
Slika 1. Kardiotokografski zapis prije i nakon amniotomije

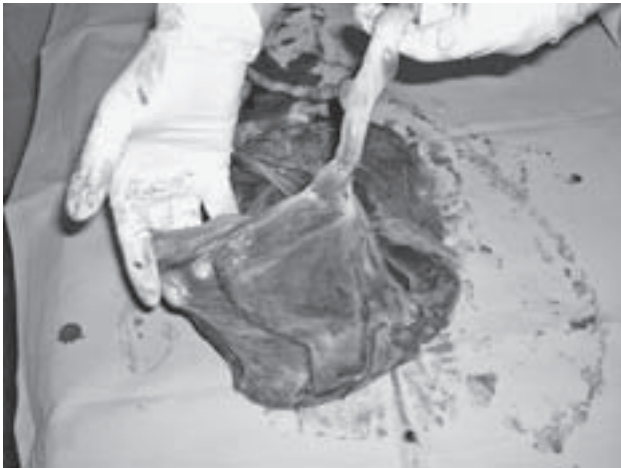


Figure 2. Placenta after delivery with evident velamentous vessels
Slika 2. Posteljica nakon poroda s jasnim krvnim žilama na ovojima

us and clearly visible five vessels passing over the lower uterine segment and cervix, and returning back to the placenta in the fundus. All listed confirmed diagnosis of vasa praevia (Figure 2). After extraction of fetus, the blood from the umbilical cord was allowed to return to the fetus before transection of the cord. A 2850 g boy was in the condition of hemorrhagic shock, with Apgar scores of 3 and 5 at 1 and 5 min, respectively. Child's RBC was 2.8×10^{12} , hemoglobin concentration was 106 g/L, hematocrit 0.33, thrombocyte count was 204×10^9 and arterial pH 7.407. The baby required immediate resuscitation, including intubation and blood transfusions. Postoperatively both mother and child were monitored for vital functions and discharged from hospital after 11 days with no further complications.

Case 2

A 36-year-old woman, gravida 2, para 1, abortion 0, presented at routine antenatal examination at gestational week 40. Routine amnioscopy was performed and blood vessels were observed through placental membranes.

Diagnosis of vasa praevia was confirmed by transabdominal and transvaginal color doppler sonography. An elective cesarean section was performed and baby boy 3800 g was delivered with Apgar scores 10 and 10 at 1 and 5 min. There were no neonatal complications.

Case 3

A 26-year-old laboring woman, gravida 1, para 0, abortion 0, at 38⁺⁵ weeks of gestation was admitted to hospital with symptoms of mild vaginal bleeding that had started at home 90 minutes earlier. The fetal heart rate had loss of variability and decelerations. Ten min. after admission there was no recorded fetal heart rate and emergency cesarean section followed. A 2890 g female newborn was delivered with Apgar scores 0 and 2 at 1 and 5 min. Evaluation of the placenta revealed velamentous cord insertion and vasa praevia that have been ruptured spontaneously. Seven hours after delivery the baby girl died even though aggressive neonatal care was applied.

Discussion

Vasa praevia have a high risk of fetal exsanguination and death from torn vessels due to membranes rupture. Although spontaneous rupture of vasa praevia has been reported in intact and ruptured membranes, that often occurs during amniotomy. The management and diagnosis of vasa praevia is usually complex since often the source of bleeding is uncertain. In August 2009 The Society of Obstetricians and Gynaecologists of Canada (SOGC) published Guidelines for the management of vasa praevia⁶ and in January 2010 International Journal of Gynaecology and Obstetrics republished those Guidelines⁷ showing how important this issue is in obstetrics and gynaecology practice.

Antepartum hemorrhage can be concomitant to placenta previa or low-lying placenta, abruptio of placenta, rupture of the marginal sinus, endocervical lesions during amniotomy, laceration or rupture of the cervix during forcing delivery, lesions of the low-lying umbili-

cal cord with amniotomy hook, cervical carcinoma or polyp. Differential diagnosis from fetal hemorrhage can be made by available tests for fetal hemoglobin to identify bleeding from vasa praevia.⁸ The Kleihauer Betke, Ogita, and Apt tests and hemoglobin electrophoresis can be used to detect the presence of fetal blood when patients present with vaginal bleeding, but unfortunately it is not yet in general use and time often does not allow for this to be completed in an emergent situation. The prenatal diagnosis of vasa praevia is mainly made by ultrasound,⁴ and amnioscopy,⁵ although other methods are also used: magnetic resonance imaging,⁹ palpation of the vessels by digital vaginal examination and identification of fetal blood in vaginal blood. Satisfied outcomes depend on prenatal diagnosis and cesarean delivery before the membranes rupture.¹⁰ In the literature there has been recently reported the successful in utero laser ablation of vasa praevia.^{11,12}

In conclusion, this three cases demonstrated that perinatal outcome of vasa praevia can be good to excellent when vasa praevia are recognized and followed by prompt and aggressive neonatal management (*case 1*) or prenatally diagnosed by simple use of color Doppler sonography and amnioscopy (*case 2*); despite advances in the diagnostic and therapeutic approaches in obstetrics vasa praevia still have a high risk of perinatal complications, even sudden unanticipated death of a healthy term fetus (*case 3*).

References

1. Oyelese KO, Turner M, Lees C, Campbell S. Vasa praevia: an avoidable obstetric tragedy. *Obstet Gynecol Surv* 1999;54:138–45.
2. Suzuki S, Igarashi M. Clinical significance of pregnancies with succenturiate lobes of placenta. *Arch Gynecol Obstet* 2008;277(4):299–301.
3. Hasegawa J, Matsuoka R, Ichizuka K, Fujikawa H, Sekizawa A, Okai T. Umbilical cord insertion to the lower uterine segment is a risk factor for vasa praevia. *Fetal Diagn Ther* 2007;22(5):358–60.
4. Baulies S, Maiz N, Muñoz A, Torrents M, Echevarría M, Serra B. Prenatal ultrasound diagnosis of vasa praevia and analysis of risk factors. *Prenat Diagn* 2007;27(7):595–9.
5. Cingotti M, Gandour A, Moxhon E. Diagnosis of vasa praevia by amnioscopy. Value of induced labor. A case report. *Rev Fr Gynecol Obstet* 1992;87:87–9.
6. Gagnon R, Morin L, Bly S, et al. Guidelines for the management of vasa previa. *J Obstet Gynaecol Can* 2009;31(8):748–60.
7. Gagnon R, Morin L, Bly S et al. Guidelines for the management of vasa previa. *Int J Gynaecol Obstet* 2010;108(1):85–9.
8. Lindqvist PG, Gren P. An easy-to-use method for detecting fetal hemoglobin – a test to identify bleeding from vasa praevia. *Eur J Obstet Gynecol Reprod Biol* 2007;131(2):151–3.
9. Oyelese Y, Jha RC, Moxley MD, Collea JV, Queenan JT. Magnetic resonance imaging of vasa praevia. *Br J Obstet Gynaecol* 2003;110(12):1127–8.
10. Oyelese Y, Smulian JC. Placenta previa, placenta accreta, and vasa praevia. *Obstet Gynecol* 2006;107(4):927–41.
11. Quintero RA, Kontopoulos EV, Bornick PW, Allen MH. In utero laser treatment of type II vasa praevia. *J Mat Fet Neonat Med* 2007;20(12):847–51.
12. Chmait RH, Chavira E, Kontopoulos EV, Quintero RA. Third trimester fetoscopic laser ablation of type II vasa praevia. *J Mat Fet Neonat Med* 2009;24:1–5.

Paper received: 27. 01. 2010; *accepted:* 18. 02. 2010.

Address for correspondence: Vladimir Blagaić, Department of Gynecology and Obstetrics, General Hospital »Sveti Duh«, Sveti Duh 64, 10 000 Zagreb. E-mail: vladimir.blagaic@gmail.com



**VIJESTI
NEWS**

XXXII ALPE ADRIA MEETING OF PERINATAL MEDICINE Bassano del Grappa, Italia, October 15–16, 2010

Topics:

- Pregnancy, delivery and newborn in obese women.
- Preterm premature rupture of membranes
- Free comunicatios
- Invited lecture (from Italy)