

Faculty of Medicine, Department of Obstetrics and Gynecology & Urogynaecology,  
Al Azhar University, Cairo, Egypt.

## **FECAL INCONTINENCE**

### **A novel concept: The role of the internal anal sphincter (IAS) in defecation and fecal incontinence**

### **FEKALNA INKONTINENCIJA**

#### **Nova koncepcija: Uloga unutarnjeg analnog sfinktera pri defekaciji i fekalnoj inkontinenciji**

*Abdel Karim M. El Hemaly, Laila A. Mousa, Ibrahim M. Kandil,  
Fatma S. El Sokkary, Ahmad G. Serour, Hossam Hussein*

*Original paper*

**Key words:** fecal incontinence, internal anal sphincter, external anal sphincter, central nervous system, alpha sympathetic nervous system

**SUMMARY. Introduction.** Fecal incontinence is involuntary escape of stool, mucus and/or flatus. Its causes are: anal sphincter damage (childbirth trauma, surgical trauma.); constipation; diarrhea; rectocele; rectal prolapse and rarely congenital causes. Fecal material entering the rectum is evacuated by defecation during which: 1. The smooth muscles of the distal colon and rectum contract, propelling the feces into the anal canal; 2. The anal sphincter relaxes allowing defecation to occur. We put forward a recent concept on the patho-physiology of defecation. The mechanism of defecation has two stages: first stage: (in early childhood) before training; second stage is after training. The mother starts to teach her child how to control himself. This is gained by maintaining high alpha sympathetic tone at the internal anal sphincter (IAS) keeping it closed all the time till appropriate place and time are available. Wherever appropriate place is available and there is a desire, six neuromuscular actions will occur: 1) the person will lower the acquired high alpha sympathetic tone at the IAS relaxing it opening the anal canal; 2) through the voluntary nervous system (NS) he will widen the ano-rectal angle to bring the anal canal and the rectum on one axis. This is done through the pelvic floor muscles; 3) through, voluntary NS he will also relax the external anal sphincter (EAS); then synergistic actions between the voluntary and autonomic nervous system occur; 4) the abdominal and diaphragmatic muscles contract, increasing the intra-abdominal pressure and forcing the feces through the anal canal (via the voluntary NS); 5) the smooth muscles of the distal colon and rectum contract, propelling the feces into the anal canal (through the autonomic NS); 6) followed by sequential contractions of the three parts of the EAS (deep then superficial and then the subcutaneous parts) that will squeeze the anal canal propelling any residual contents.

**Objectives.** Imaging of the anal canal by 3-dimension ultrasound (3DUS) in normal women and women suffering from fecal incontinence and from rectocele, to compare the state of the IAS and EAS. **Methods.** 40 patients with FI were assessed clinically and by imaging using 3DUS, and also 10 normal women not suffering from fecal incontinence (FI) as a control. **Results.** The anal canal is closed in normal women, with intact IAS. In women suffering from FI the anal canal is wide and open with torn IAS. **Conclusion.** The internal anal sphincter (IAS) is a collageno-muscular tissue cylinder that surrounds the anal canal innervated by alpha-sympathetic nerve supply from the hypogastric nerves. It is surrounded in its lower part by the EAS which is a striated muscle innervated by the pudendal nerve. Its damage during childbirth causes fecal *incontinence*, and mending its torn wall restores fecal *continence*.

*Izvorni članak*

**Ključne riječi:** fekalna inkontinencija, unutarnji analni sfinkter, vanjski analni sfinkter, središnji živčani sustav, alfa-simpatički živčani sustav

**SAŽETAK. Uvod.** Fekalna inkontinencija (insuficijencija stolice) znači nevoljno bježanje stolice, sluzi i/ili vjetrova. Uzroci su: oštećenje sfinktera (pri rođenju djeteta, kirurška trauma), zatvor stolice, proljev; rektokela, ispadanje rektuma, rijetko prirodno ispadanje. Stolica ulazi u završno crijevo te iz njega izlazi na sljedeći način: 1. Glatki mišići donjeg i završnog dijela debelog crijeva se stežu, potiskujući feces u analni kanal; 2. Analni sfinkter olabavi i omogućuje da uslijedi defekacija. Predstavljamo svježe shvaćanje o patofiziologiji defekacije. Mehanizam ima dva razdoblja: prvo razdoblje je rano djetinstvo, bez poduke; drugo razdoblje je nakon poduke. Majka podučava svoje dijete kako se kontrolirati. To se postiže visokim alfa simpatičkim tonusom unutarnjeg analnog sfinktera, držeći ga zatvorenim sve dok se ne ukaže odgovarajuće mjesto i vrijeme. Kad se nađe odgovarajuće mjesto, i ako postoji želja, počinje šest sinergističkih neuromuskularnih aktivnosti: 1) osoba će sniziti postojeći visoki alfa simpatički tonus unutarnjeg analnog sfinktera i time otvoriti analni kanal; 2) pomoću voljnog živčanog sustava smanjit će ano-rektalni kut i dovesti ih u istu osovinu; to postiže pomoću mišića dna zdjelice; 3) voljnim živčanim sustavom također će omlohaviti vanjski analni sfinkter; tada nastupa sinergistična djelatnost voljnog i autonomnog živčevlja; 4) trbušni i dijafragmalni mišići se stežu, povećavaju intraabdominalni tlak te potiskuju feces kroz analni kanal; 5) stežu se glatki mišići debelog crijeva i rektuma te potiskuju

feces u analni kanal (autonomnim živčevljem); 6) slijede segmentalna stezanja sva tri dijela vanjskog sfinktera (dubokog, površnog pa potkožnog), koja će iz analnog kanala istisnuti sve zaostatke.

**Svrha rada.** Trodimenzionalnim ultrazvukom prikazati analni kanal u zdravih žena te u onih koje pate od fekalne inkontinencije i rektokele, usporediti njihov unutrašnji i vanjski analni sfinkter. **Metode.** Analizirano je klinički i 3DUZ-om 40 pacijentica s fekalnom inkompetencijom i uspoređeno s 10 zdravih žena. **Rezultat.** Analni kanal je u zdravih žena zatvoren, njihov unutrašnji sfinkter je neoštećen. U žena s fekalnom inkompetencijom analni kanal je širok i otvoren te s razderanim sfinkterom. **Zaključak.** Unutarnji analni sfinkter je kolageno-mišićno tkivo oblika cilindra koje okružuje analni kanal, inerviran je alfa-simpatičkim živcima iz hipogastričkog plexusa. Unutarnji sfinkter je okružen donjim dijelom vanjskog analnog sfinktera, koji je građen od prugastog mišićja inerviranog pudendalnim živcem. Njegovo oštećenje tijekom radanja uzrokuje fekalnu inkontinenciju. Prepravak njegove razderane stijenke uspostavlja fekalnu kontinenciju.

## Introduction

Fecal incontinence (FI) is a very embarrassing and distressing condition psychologically and socially, in any individual. It can lead to depression, social isolation, loss of self-esteem, loss of self-confidence and poor quality of life. Fecal incontinence is involuntary escape of stool (solid and/or loose), flatus, and/or mucus. In other words, fecal incontinence is unwanted or untimely release of feces, mucus and/or flatus.

### Causes.

I. *Anal sphincter damage by trauma.* The most common trauma is childbirth trauma during vaginal delivery, but it can result from surgical trauma, e.g. during hemorrhoidectomy, surgery for a pelvic or perineal tumors; radiological trauma.

II. *Pelvic floor dysfunction.* 1. Rectocele; 2. Rectal prolapse; 3. Generalized weakness and sagging of the pelvic floor; 4. Pelvic floor neuromuscular damage e.g. decreased perception of rectal sensation, impaired anal sensation, decreased anal canal pressures and decreased squeeze pressure of the anal canal.

III. *Constipation.* Constipation is a common cause of fecal incontinence (it is analogue to retention with overflow in urinary incontinence). Constipation is the result of and/or can cause neuro-muscular ano-rectal injury. Constipation causes prolonged muscle and nerve stretching and leads to weakness of the intestinal muscles and nerves resulting in fecal incontinence.

IV. *Diarrhea* (analogue to urge incontinence). Loose stool is more difficult to control than solid one. Diarrhea can be: 1. Acute e.g. gastro-intestinal infections, food poisoning; 2. Chronic e.g. ulcerative colitis, Crohn's disease, diverticulitis or neoplasm, gastrectomy, vagotomy; malabsorption, thyrotoxicosis. When the cause of diarrhea is by temporary problems such as gastrointestinal infections or food reactions incontinence tends to last for a short period. Chronic conditions, such as irritable bowel syndrome, or Crohn's disease can cause severe diarrhea lasting for weeks or months until successful treatment can be found.

V. *Nerve damage.* Damage to the autonomic, voluntary nervous systems, or to the central nervous system. The sensation of rectal distension travels along the pelvic parasympathetic system to S-2, S-3, and S-4 segment. Fecal incontinence can be caused by damage to:

the sensory nerves, and/or motor nerves; or to the central nervous system. If the sensory nerves are damaged, detection of stool in the rectum is disabled, and one will not feel the need to defecate until it is too late. Nerve damage can be caused by: childbirth trauma, long-term constipation, stroke, and diseases that cause neuropathy, such as diabetes mellitus, disseminated sclerosis and systemic lupus erythematoses.

VI. *Loss of storage capacity of the rectum.* Normally, the rectum stretches to hold stool until it is voluntarily released. But rectal surgery, radiation treatment, and inflammatory bowel disease can cause scarring, which may result in stiff and less elastic rectal walls. The rectal walls are unable to stretch as much and are unable to accommodate as much stool. Inflammatory bowel disease also can make rectal walls very irritated and therefore unable to contain stool.

VII. *Other causes.* Fecal incontinence can have other causes including one or a combination of the following: 1. Congenital. In cases of imperforate anus, partial or complete lack of the sphincter mechanism (rare). Patulous anus associated with mental deficiency. 2. Diseases, drugs, and indigestible dietary fats that interfere with the intestinal absorption e.g. cystic fibrosis. 3. Lateral internal sphincterotomy (surgery for anal fissures). 4. Seizure. 5. Postoperative e.g. surgery for high anal fistula. 6. Perineal resection of the rectum for carcinoma (rare).

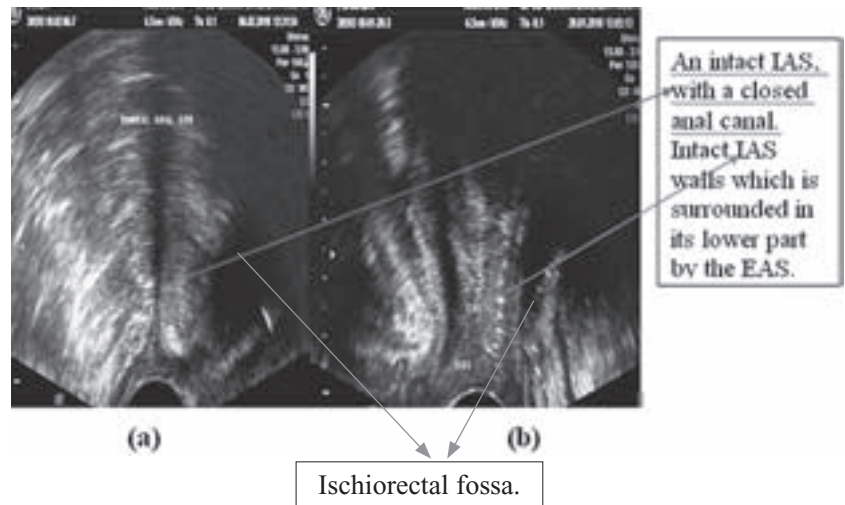
A major cause of fecal incontinence in young healthy women is anal sphincter damage during vaginal delivery, which occurs in as many as 18% in the USA. Studies from other countries indicate that 5–10% of women report incontinence of stool 3–6 months after sphincter damage, and 29–53% of women report incontinence of flatus, despite having the rupture repaired at delivery.<sup>1</sup>

## Defecation

Fecal material entering the rectum is evacuated by defecation during which the smooth muscles of the distal colon and rectum contract, propelling the feces into the anal canal. Thereafter anal sphincter relaxes allowing defecation to occur.

We put forward a novel concept on the pathophysiology of defecation. The mechanism of defecation has two stages: *First stage* (in infancy and early childhood) before training: as described above; *Second stage* after

Figure 1. Transvaginal 3DUS picture: a) coronal section showing a normal IAS with intact sphincter walls and closed lumen. The IAS is surrounded in its lower part by the EAS; (b) showing the presence of an angle between the rectum above and the closed anal canal below. Slika 1. Transvaginalni 3DUZ slika: a) koronarni presjek normalnoga unutarnjeg analnog sfinktera s intaktnim stijenkama i zatvorenim lumenom; b) postoji kut rektuma (gore) prema zatvorenom analnom kanalu /dolje).



Normal IAS, with Intact walls and a closed lumen. It is surrounded by the EAS.

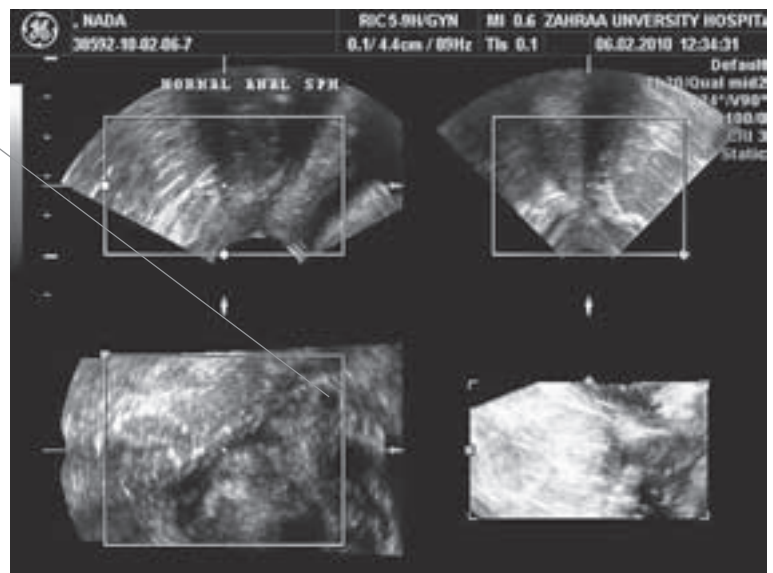


Figure 2. Transvaginal 3DUS pictures, coronal and cross section, showing a normal IAS with a closed lumen and intact walls. It is surrounded in its lower part by the EAS.

Slika 2. Transvaginalne 3DUZ slike, koronarni i kosi presjeci prikazuju normalni unutarnji analni sfinkter sa zatvorenim lumenom i intaktnim stijenkama. U donjem dijelu unutarnji sfinkter uklapa se u vanjski sfinkter.

training: the mother starts to teach her child how to control himself. This is gained by maintaining high alpha sympathetic tone at the internal anal sphincter (IAS) keeping it closed all the time till appropriate place and time are available. Wherever appropriate place is available and there is a desire, under the control of the high CNS centers, through synergistic nervous actions between the autonomic and the voluntary nervous systems, six neuromuscular actions will occur:

1. The person will lower the acquired high alpha sympathetic tone at the IAS relaxing it, opening the anal canal.
2. Through the voluntary nervous system he will widen the ano-rectal angle, to bring the anal canal and the rectum on one axis. This is done through the pelvic floor muscles.
3. Through the voluntary nervous system he will also relax the eternal anal sphincter (EAS), which is a skeletal muscle innervated by the pudendal nerve. Then two synergistic actions between the voluntary and autonomic nervous system occur. The abdominal and diaphragmatic muscles contract (through the voluntary nervous system) increasing the intra-abdomi-

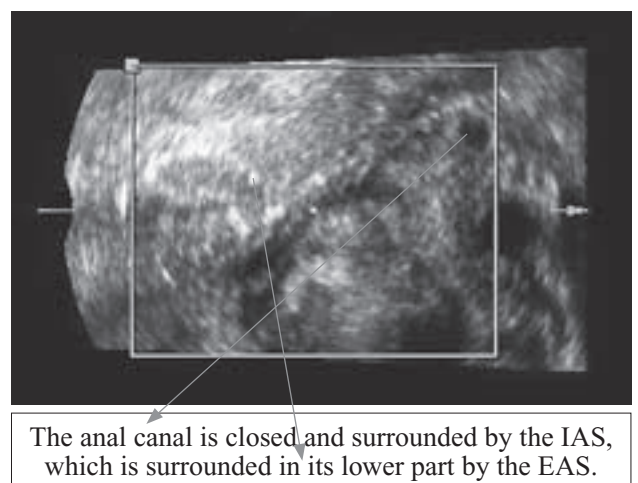


Figure 3. Cross section of 3DUS picture of normal IAS, showing the anal canal closed and surrounded by the IAS, which is surrounded in its lower part by the EAS.

Slika 3. Kosi presjek 3DUZ slike normalnog unutarnjeg analnog sfinktera sa zatvorenim analnim kanalom, okruženog unutrašnjim sfinkterom koji se u svom donjem dijelu uklapa u vanjski sfinkter.

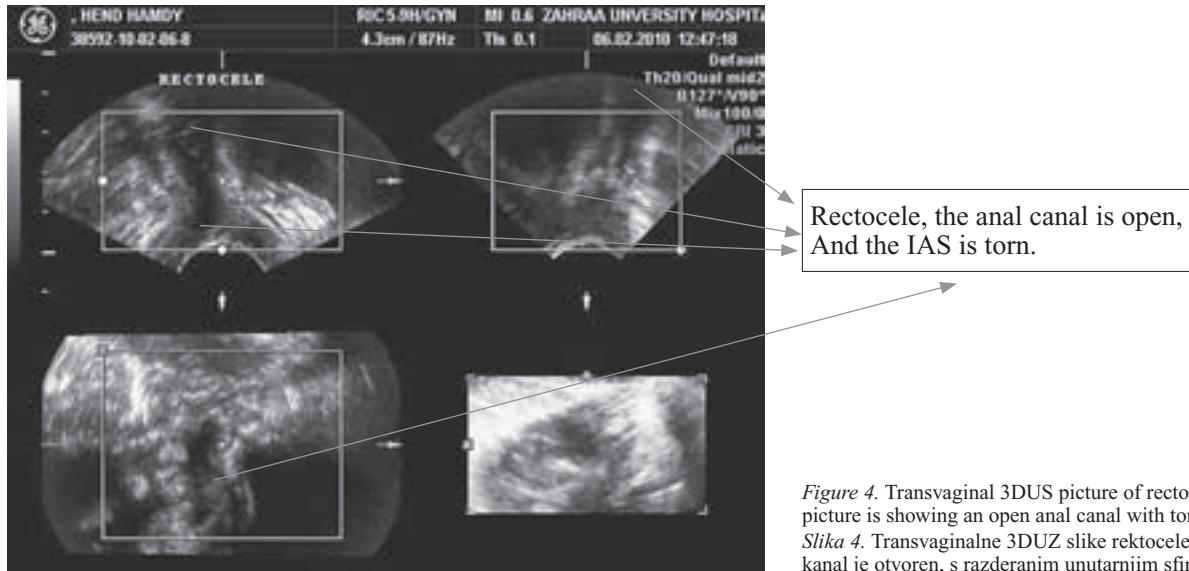


Figure 4. Transvaginal 3DUS picture of rectocele: the picture is showing an open anal canal with torn IAS.  
 Slika 4. Transvaginalne 3DUZ slike rektocele: analni kanal je otvoren, s razderanim unutarnjim sfinkterom.

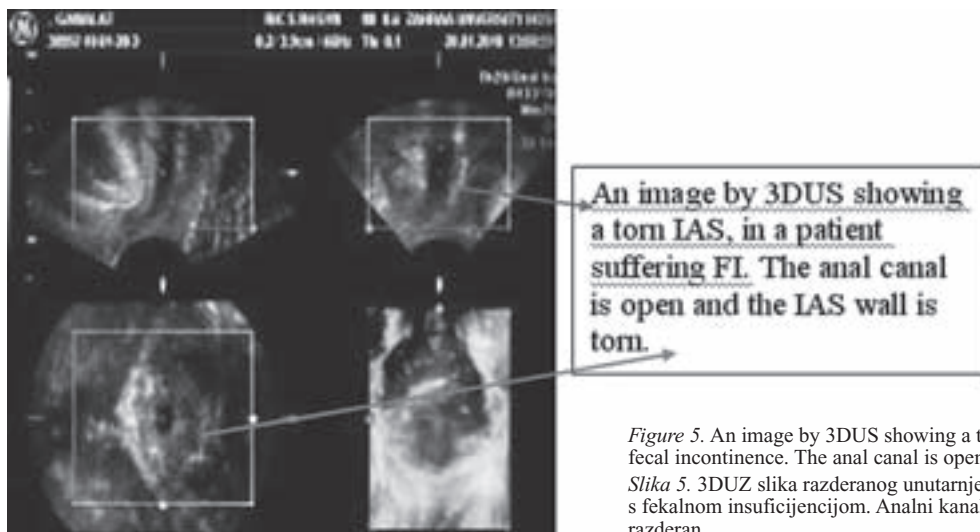


Figure 5. An image by 3DUS showing a torn IAS, in a patient suffering fecal incontinence. The anal canal is open and the IAS wall is torn.  
 Slika 5. 3DUZ slika razderanog unutarnjeg analnog sfinktera u bolesnice s fekalnom insuficijencijom. Analni kanal je otvoren, unutarnji sfinkter razderan.

nal pressure and forcing the feces through the anal canal). 5. The smooth muscles of the distal colon and rectum contract, propelling the feces into the anal canal (through the autonomic nervous system). 6. Followed by sequential contractions of the three parts of the external anal sphincter, deep, then superficial and then the subcutaneous parts, that will squeeze the anal canal propelling any residual contents and emptying the anal canal completely.

When the rectum is distended, stretch receptors are stimulated. The sensation of rectal distension travels along the pelvic parasympathetic nerves to S2, S3 and S4 ganglia. In the recto-anal junction, there are specialized sensory end organs e.g. Krause end-bulbs, Golgy-Mazzoni bodies. Specialized afferent nerves for tension, temperature, texture, touch and friction subserve these organized nerve endings.

An intact sampling reflex allows the individual to choose whether to discharge or to retain the rectal con-

tents. Discharge is, by relaxing the IAS and EAS for a moment only to release flatus, or for longer time to pass stool. An intact IAS, through the acquired high alpha sympathetic tone, keeps the anal canal closed and empty.

### Objectives

Imaging of the anal canal by 3-dimension ultrasound (3DUS) in normal women and women suffering from fecal incontinence (FI) and women suffering from rectocele to compare the state of the IAS, EAS and the anal canal.

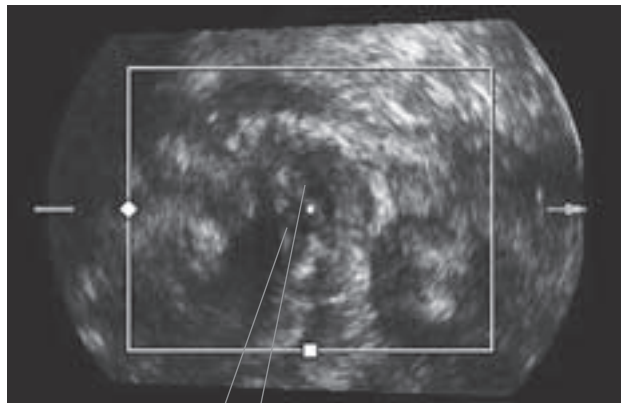
### Methods

40 patients with FI were assessed clinically and by imaging using 3DUS, and also 10 normal women not suffering from FI. Three dimension ultrasound (3DUS) assessment of the IAS was done for the 10 continent women as control and for each patient of the 40 study

cases using trans-vaginal route and transperineal route by a vaginal probe multi-frequent 5–7.5 MHz, General Electric, integrated 3D-4D Unit (GE Voluson) 730 Pro V machine.

## Results

The anal canal is closed in normal women, with intact IAS (*Figures 1–3*). In women suffering from fecal in-



Torn IAS seen, the damage is mainly in the collagenous sheet with muscle fibers intact. Also kindly notice the anal canal is opened.

*Figure 6.* A patient who is suffering from fecal incontinence. 3DUS transvaginal image showing in the cross section torn IAS. The damage is mainly in the collagenous sheet leaving the muscle fibers intact. Notice an open anal canal.

*Slika 6.* Bolesnica s fekalnom insuficijencijom. 3DUZ transvaginalna slika u kosom prerezu prikazuje razderani unutarnji sfinkter. Pretežito je oštećena kolagena ovojnica, a mišićni snopovi su intaktni. Analni kanal je otvoren.

continence the anal canal is wide and open with torn IAS wall. (*Figures 4–6*).

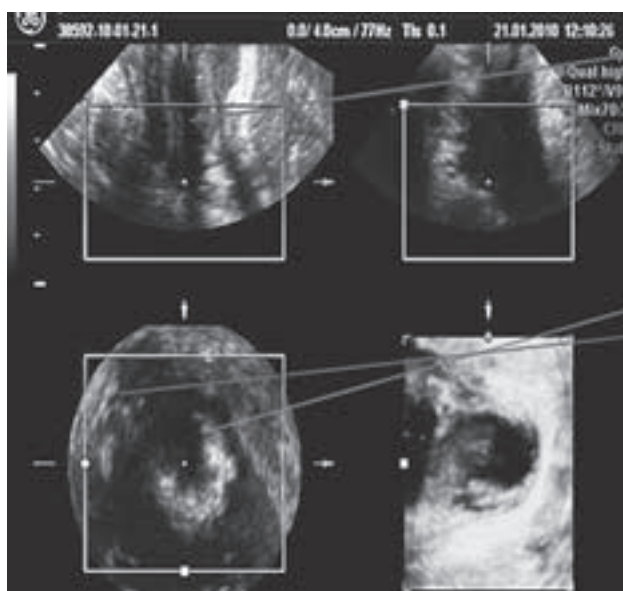
## Discussion

The internal anal sphincter (IAS) is a collageno-muscular tissue cylinder that surrounds the anal canal innervated by alpha-sympathetic nerve supply from the hypogastric nerves. (*Figures 1–3*). It is surrounded in its lower part by the EAS which is a striated muscle innervated by the pudendal nerve. Damage of the IAS causes dilation of the anal canal. Open and dilated anal canal allows the rectal contents to enter the anal canal with subsequent fecal incontinence. So we can more correctly say that, the first cause of fecal incontinence is anal sphincter's damage: traumatic injury to one and/or both anal sphincters: IAS, EAS. Also we can add, an anal intercourse to be a traumatic cause of anal sphincter injury.

Also, this can explain why repair of the EAS in cases of complete perineal tear (*Figure 7*) whether by end-to-end or overlapping techniques does not lead to complete fecal continence:<sup>1</sup> as a concomitant torn IAS is missed, not diagnosed and not repaired.

All published reports of the results of overlapping technique have shown significant improvements in symptoms of fecal incontinence, with 60%–80% achieving continence.<sup>2</sup> It is also clear, however, that fecal control deteriorates over time with only 50% of initial successful outcomes having improved continence at five years.<sup>3</sup> Poor understanding of perineal anatomy and inadequate training in repair techniques are possible reasons for the high incidence of persistent symptoms.<sup>4</sup>

With a new concept the failure can be explained by missing to recognize and repair the torn IAS. Vaginal



The anal canal is seen open in a case of a complete perineal tear. The IAS is seen torn.

An image by 3DUS of a complete perineal tear. The edges of the EAS are seen, in addition to the torn collagenous sheet of the IAS.

*Figure 7.* The patient who is suffering from complete perineal tear imaged by 3DUS, showing the anal canal is open and the IAS torn, in addition to the torn edges of the EAS.

*Slika 7.* Bolesnica s potpunim razdorom mećice, prikazanim na 3DUZ. Analni kanal je otvoren, unutarnji sfinkter razderan uz razderane rubove vanjskog analnog sfinktera.

prolapse, anterior wall and posterior wall, is quite common especially after frequent multiple labors, difficult and instrumental labors. Childbirth trauma causes redundancy, flabbiness and rupture of the collagenous sheet of the vagina leading to its prolapse. At the same

time it causes rupture of the internal urethral sphincter (IUS) leading to stress urinary incontinence (SUI); and rupture of the IAS leading to fecal incontinence. (Figures 4–6, 8–10).

We innovated an operation »Urethro-Ano-Vaginoplasty« to surgically treat urinary incontinence and fecal incontinence and vaginal prolapse. At the operation

1. We mend the torn IUS causing SUI,
2. We mend the torn IAS causing fecal incontinence,
3. We strengthen the flabby redundant vaginal walls by overlapping longitudinally the two vaginal flaps, instead of cutting away any extra vaginal tissue.

**Conclusion**

Pelvic collagen is an essential support of the pelvic organs. It is an essential part of the constituents of the internal urethral sphincter, internal anal sphincter, pel-

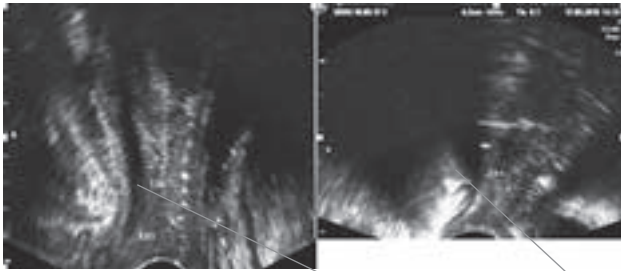
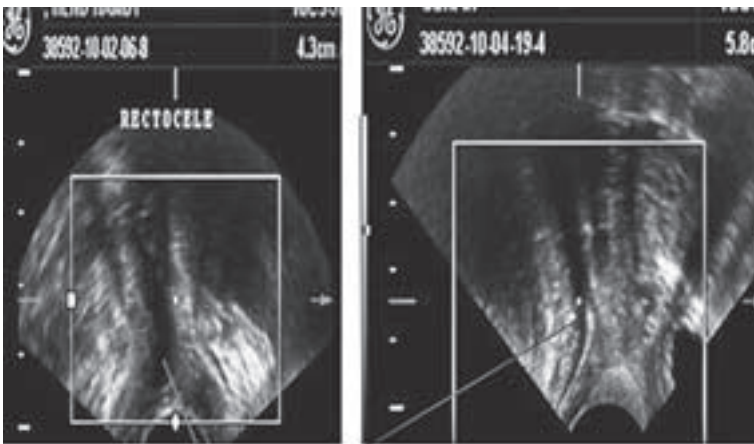


Figure 8. Comparison between an intact IAS on the left, and a torn IAS in a patient with fecal incontinence as imaged by 3DUS picture.  
Slika 8. Usporedba neoštećenog i razderanog unutarnjeg analnog sfinktera u bolesnice s fekalnom insuficijencijom prikazanog 3DUZ slikom.



Abnormal IAS: an open anal canal & torn walls of the IAS, Compared to Normal IAS: Closed anal canal with intact walls of the IAS.

Figure 9. Comparison between normal IAS with closed anal canal as compared to torn IAS with an open anal canal and torn walls of the IAS.  
Slika 9. Usporedba između normalnog unutarnjeg analnog sfinktera sa zatvorenim analnim kanalom i razderanog sfinktera s otvorenim analnim kanalom.

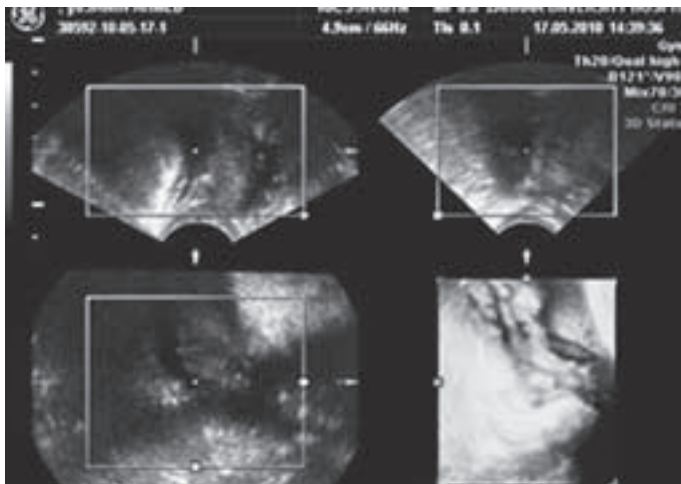
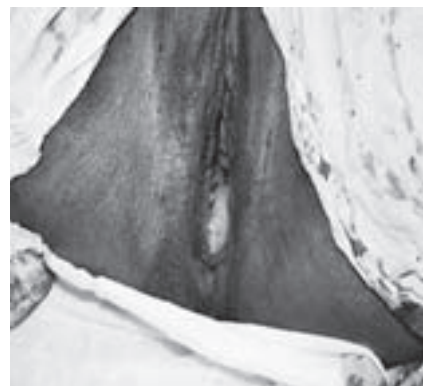

Figure 10. Rectocele. A posterior wall is seen bulging without bearing down. Imaging is done by 3DUS showing the anal canal open with torn IAS wall and dilated rectum.

Slika 10. Rektocela. Vidi se izbočena stražnja stijenka, ali bez ispadanja. 3DUZ slika prikazuje otvoreni analni kanal, razderani unutarnji sfinkter i prošireni rectum.



vic ligaments and the vagina. Rupture and weakness of the pelvic collagen is the cause of stress urinary incontinence, fecal incontinence and genital prolapse.

## References

1. France-Borello D, Burgio KL, Richter HE, et al. Fecal and urinary incontinence in primiparous women. For the Pel-

vic Floor Disorders Network. *Obstet Gynecol* 2006;108(4): 863–72.

2. Pinta TM, Kylanpaa ML, Salmi TK, et al. Primary sphincter repair: are the results of the operation good enough? *Dis Colon Rectum* 2004;47:18–23.

3. Halverson AL, Hull TL. Long term outcome of overlapping anal sphincter repair. *Dis Colon Rectum* 2002;45:345–8.

4. Sultan AH, Thakar R. Lower genital tract and anal sphincter trauma. *Best Pract Res Clin Obstet Gynecol* 2002;16:99–115.

*Paper received:* March 3, 2010; *Accepted:* May 25, 2010.

*Address for correspondence:* Prof. Abdel Karim Mohammad Aly El Hemaly, FRCS, MRCOG, Faculty of Medicine, Al Azhar University, 3 emad el din kamel street, Nasr City, Cairo-Egypt, Post box: 11371, E-mail: profakhemaly@hotmail.com



**VIJESTI  
NEWS**

## GLOBAL CONGRESS OF MATERNAL AND INFANT HEALTH Barcelona, Spain, 22–26. IX. 2010

Pozvani predavači 220; Pretkongresni tečajevi 8; 22 radionice; 58 simpozija; 40 posebnih predavanja; 16 kontroverzi; 6 forumskih sjednica: Mediteran, Latinskoameričke zemlje, Azijska i Oceanija, Srednje-europske zemlje, Arapske zemlje.

**Glavne sjednice.** Zdravlje majke i djeteta u Africi, Zdravlje majke i djeteta u Aziji i Oceaniji, Zdravlje majke i djeteta u Latinskoj Americi;

**Kotizacija** ovisno o trenutku uplate i statusu sudionika od 107 € do 695 €.

**Informacije:** Znanstveni sekretarijat: MATRES MUNDI, Londres 6–8, 08029, Barcelona, Spain; e-mail: barcelona2010@matres-mundi.org; Tehnički sekretarijat: GRUPO PACIFICO, Congress Division, Mariano Cubi, 4, 08006, Barcelona, Spain; e-mail: maternal2010@pacifico-meetings.com.

[www.globalcongress2010.com](http://www.globalcongress2010.com)



## XXXII ALPE ADRIA MEETING OF PERINATAL MEDICINE Bassano del Grappa, Italia, October 15–16, 2010

### Topics:

- Pregnancy, delivery and newborn in obese women.
- Preterm premature rupture of membranes
- Free communicatios
- Invited lecture (from Italy)