

On the Investigation of Human Remains, Found in Savvatiev Monastery (Tver Region, Russia)

• Andrei V. Zinoviev •

Zoology Division, Tver State University, Tver, Russia

Address for correspondence:

Andrei V. Zinoviev,
Tver State University,
Faculty of Biology,
Zoology Division,
Chaikovskogo pr. 70a
170002 Tver, Russia.
E-mail: m000258@tversu.ru

Bull Int Assoc Paleodont. 2011;5(1):24-36.

Abstract

Three skeletons found on the course of restoration works in Znamenskaya Church of the former Savvatiev Monastery (Tver Region, Russia) were studied. They belonged to two mature and one senile man buried in XV century. The senile man, buried in rich limestone sarcophagus, stand out by its high stature, strong physicality and old age. He also had a severe trauma of its left leg. The attribution of this skeleton to the Saint Savvaty, Palestine monk and founder of Savvatiev Monastery, who was buried in Znamenskaya Church, is problematic due to the absence of Mediterranean features in his skull and traumas, not known for him in historical records. Two other men, buried by the sarcophagus, do not exceed average physical conditions of contemporaneous men and have a peculiar anomaly of first two cervical vertebrae, which may show their close kinship.

Keywords: Archaeoanthropology Tver; Saint Savvaty; Palestine; Prince Mikhail Alexandrovich; Metropolitan Cyprian; Pathology; Fracture

Introduction

At the end of the August, 2009 on the course of restoration works in Znamenskaya Church (Church of Sign) in former Savvatiev Monastery (village Savvatievo, Tver region), Figure 1, a limestone sarcophagus has been uncovered. On September 22nd of the same year by the order of Archbishop of Tver and Kashin Victor the studies of the mentioned sarcophagus, presumably belonging to the founder of monastery, Saint Savvaty, began. Started on October 5th, the archaeological excavations

have additionally opened a part of monastery necropolis. Human remains, found there, including the skeleton from the sarcophagus, have been shipped to Moscow, where they were investigated by the specialists from the Institution of Archaeology of the Russian Academy of Sciences (8, 9). Their report was sent to archpriest of Znamenskaya Church, who initiated the further investigations, inviting the author of this article to study human osseous remains, returned from Moscow.

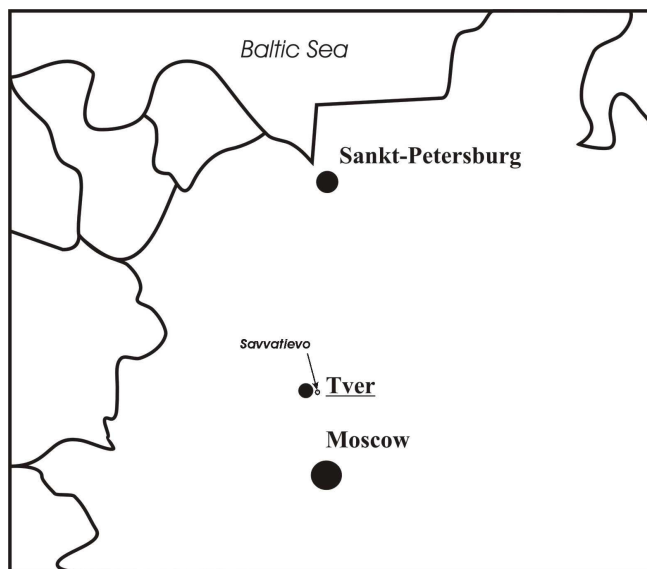


Figure 1 Location of the village Savvatievo

Historical account

The origin of Savvatiev Monastery begins from the small hole (Figure 2), in which the monk from Palestine, Savvaty, has settled around 1390 AD. According to the legend, he came to Tver from Jerusalem and brought a small wooden cross, containing a small particle of wood from the Cross of Jesus. He could have got to Tver following metropolitan Cyprian (1390-1406). In the year 1390 Cyprian has arrived to Tver invited by the Great Prince Mikhail Alexandrovich (1368-1399). Here he appointed archdeacon Arseny as a head of Episcopal Cathedral. Savvaty did not stay for a long time in a busy city – the capital of former strong Principality of Tver. To find the better place for the coenobite feat, he went to the forest. In 9 kilometers from Tver, near the bank of Orsha river, he excavated the hole along with a well and small pond. There he lived, carrying chains with large stone, weighting around 25 kg. He also walked barefoot. By the end of 90th of XIV century, the rumor about the hermit from Palestine has spread among adjacent monasteries. Lots of people, among which were famous monks and church figures, started to visit the hole of hermit. Savvaty felt their approach, meeting visitors in front of the forest, where his dwelling was. He talked to the visitors and then accompanied them about 8 km on their way back to Tver. Some of the people, who visited Savvaty, wanted to stay by. Gradually the Savvatiev Monastery has appeared. Some of the monks followed the

Savvaty's style, living in holes nearby, some lived in established Monastery. Savvaty himself lived in the hole for 44 year, until his death on April 24th, 1434. He was buried in Znamenskaya Church, built by the masters from Novgorod on the place of older wooden church. In XV century the Monastery started to flourish, being supported by mighty and wealthy people of Tver. In this and next centuries several stone churches were erected here. According to the record of the year 1692, the prosperous Monastery owned vast areas of lands; its town church was situated in Tver near the House of Bishop. During the reign of Peter the Great, Savvatiev Monastery was attached to Voskresensky Monastery on Istra and gradually declined. It was closed in the year 1764 and turned into parish. However, churches of Monastery remained famous among citizens of Tver and adjacent areas. They were frequently visited until 1935, when church services were terminated. Buildings of Monastery were destroyed, the hole of Savvaty, well and pond were filled up with the earth. The revival of the Monastery started in the year 2000 (church services started earlier, in 1998). The sacred hole, well and pond were reconstructed, Znamenskaya Church was erected again on the basement of the destroyed one (Figure 3).



Figure 2 The hole of Saint Savvaty. End of XIX century




Figure 3 Reconstructed Znamenskaya Church in Savvatievo (2010)

Time, materials and methods

Investigations of skeletal remains have been carried out on July 26th, 2010 near Znamenskaya Church on the territory of the former Savvaty Monastery.

Three human skeletons in various states of preservation were studied. Bones from the burial No. 1 (in sarcophagus) were the worst preserved of all. Due to the prolonged contact to the humid air they became fragile and partially disintegrated. The breakage of the lid of sarco-phagus on the course of excavations and subsequent fall of its pieces inside additionally de-stroyed the skeleton. The bones from the burial No. 2, which was deposited under the sarco-phagus, were in better state. Only small distal bones of limbs have vanished. Similar state of preservation had the skeleton from burial No. 3, found at the edge of the excavation pit.

The sex of buried were determined by pelvic bones (16, 27) as well as by secondary sexual characters on other bones (review see in 24). The age of buried individuals has been determined by combination of several methods using cranial (2, 3) and postcranial features (1, 4, 6, 7, 11-13, 17, 20, 23, 28, 32, 34, 35). We also kept in mind the reliability of each method (5, 18). The stature estimation was based on a number of methods, provided in the work of Alekseev (1). To check the results several later methods were applied (7, 10, 15, 21; 22, 25, 26, 31, 33). We also used several recommendations to determine the age of hypoplastic lines (14, 29, 30).

An original computer program "Stature of Buried" (2007), developed at the Physics-Technical Faculty of Tver State University, has been used to find an optimal value for the stature of buried. Skeletons have been vectorized by the author in Corel-Draw 10. Forms for vectorization have been generously provided by Thierry Vette (France).

Results and discussion

Joint data on skeletons is provided in the Table 1.

Burial No. 1 (from sarcophagus), Figures 4 and 5. The detailed description of skeleton from this burial is provided in the report of specialist from Moscow (9). They noticed age de-generative changes in all parts of the skeleton. A special attention was paid to traumatic changes in the left leg and vertebral column. We think, that described earlier as independent, they resulted from one accident, namely due to the fall of the person from the considerable height on the extended left leg. The pressure of the fall went along the long axis of the leg bones, breaking tibia. As the result, its distal fragment moved proximally and subsequently fused with the proximal part, thus making the healed tibia 2,3 cm shorter its pre-accidental length (36,5 cm for left tibia versus 38,8 cm for right tibia). The more powerful femoral shaft of the left leg withstood the pressure; the weaker collum femoris broke. Although hip joint remained intact, the left femur became 2,5 cm shorter (44,0 cm for left femur versus 46,5 cm for right femur) due to the abnormal (dorsally bent) fusion of femoral neck to its shaft. After healing the leg has been used in walking till the death of individual, since the articular surfaces of hip joint did not deteriorate. However, due to the traumatic changes, the left leg was turned outwards (supinated) as well as by 4,8 cm shorter than the right one. The individual must have been pronouncedly lame in the left leg. The discussed accident has obviously influenced the vertebral column, compressing the bodies of lumbar vertebrae. The body of the first lumbar vertebra is especially compressed from the right side. This also could be related to the constant right bending of the corpus while stepping on the shortened left leg. The latter disturbed the individual till the death not only by its deficient length. Long-lasting inflammation, which started by the fracture of the left tibial bone, gradually expanded on the adjacent areas of fibula. Apart from mentioned traumas, one of the ribs of the buried has the traces of the old fused fracture. Well developed crests for the muscle insertions, massive neurocranium (facial part of the skull is not preserved) and lower jaw, stature, large for the XI-XVI centuries (172 ± 2 cm), characterize person, buried in sarcophagus as physically strong man, belonging to the Caucasian race.

Burial No. 2 (beneath the sarcophagus), Figures 6 and 7. Caucasian men from this burial is younger than that from sarcophagus. Better preserved skeleton, including facial part of the skull, shows more gracile individual. 10 cm shorter, than previous man, this individual well matches the average masculine height of the century. "Well preserved dental system", noticed by Dobrovolskaya and Mednikova (8), have traces of paradontosis. However, the absence of tartar and caries besides the good genetics could point on the low proportion of low-molecular carbohydrates in the meal of the buried. The rotation of the left canine along its long axis must be mentioned as an anomaly. The more widespread anomaly is an absence of third molars; this individual lacked both lower and right upper third molars. More frequently met in women, this state is also characteristic for men of gracile stature with shorted jaws (19, 38). Hypoplastic lines on right lower canine show stresses, which the buried underwent in ages of 3,5, 4 and 4,5 years. Vertebral bodies show initial minute traces of osteochondrosis. The arthrosis in the place of contact between atlas and axis is of particular interest. Odontoid process of the axis appears larger and flattened. Atlas has a corresponding flattened area. Changes in both vertebrae, however, did not preclude the rotation of the head, as Moscow specialists concluded.

Burial No. 3 (from the edge of excavation pit), Figures 8 and 9. The skeleton from this burial belonged to the Caucasian men of 45-50 years old. His stature was quite similar to the men from burial No. 2. The similarity even went further. Person shows the identical anomaly of the first two cervical vertebrae. As in the previous person, this anomaly did not preclude the free rotation of the head. The late fusion of the metopic suture is worthwhile mentioning; this anomaly is more characteristic for women (36, 37). The dental system of the man from burial No. 3 is in by far worse state, than that of the individual from burial No. 2. Many teeth have fallen out antemortem – P2dex et sin, M3sin, M3-P2sin, P2dex, M3dex. Both jaws bear traces of para-dontosis. Preserved teeth, however, lack caries. Hypoplastic lines on right lower canine indicate stresses, which the buried underwent in ages of 4,5 and 5 years.

Table 1 Joint data on skeletons

Burial	Sex	Age (years)	Age group	Stature (cm)
No. 1	♂	70+	senilis	172±2
No. 2	♂	40-45	maturus	162±1
No. 3	♂	45-50	maturus	163±1

SENILIS															
1								2							
8	7	6	5	4	3	2	1	1	2	3	4	5	6	7	8
8	7	6	5	4	3	2	1	pm	2	3	pm	pm	?	?	?
4								3							

Burial No. 1

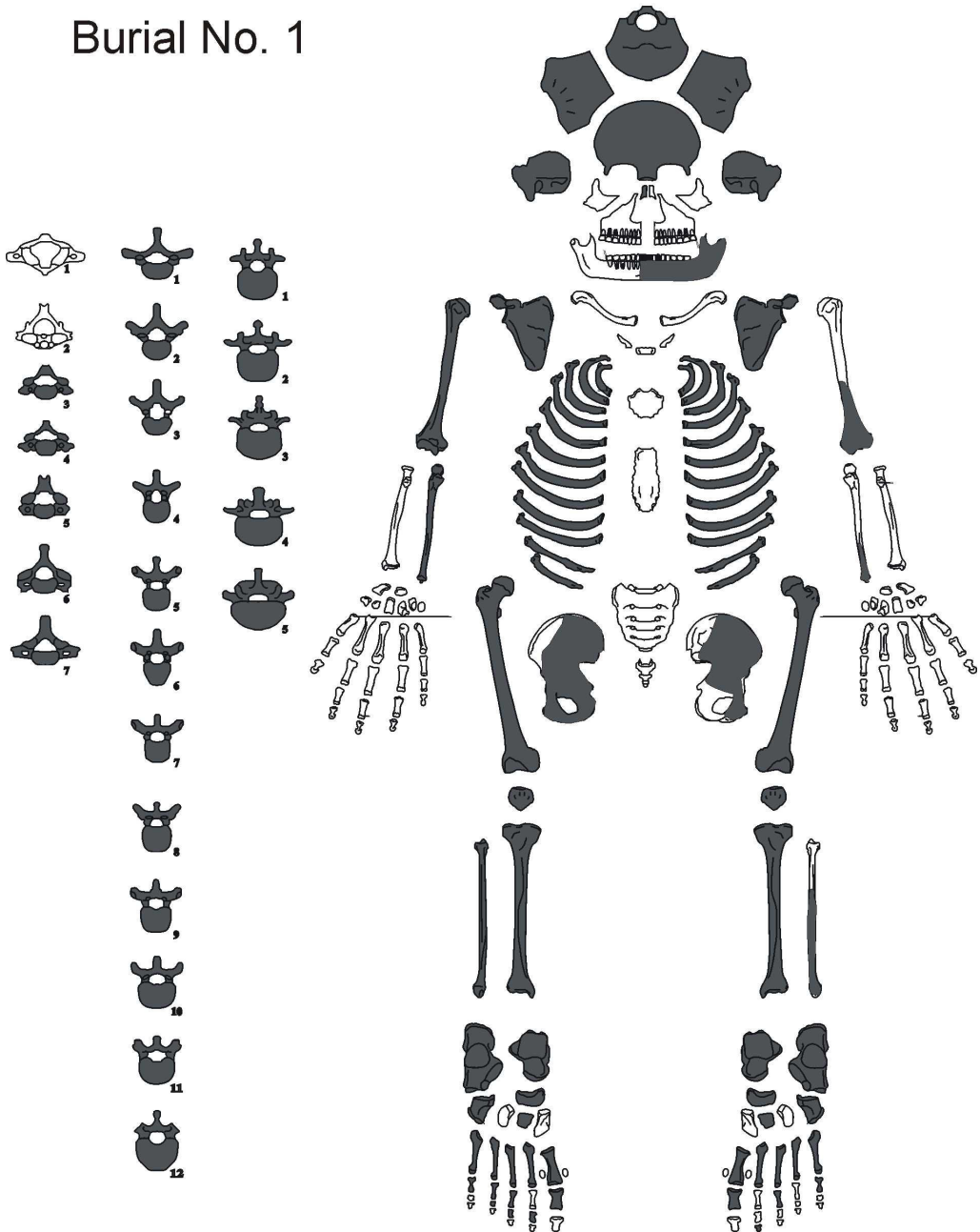


Figure 4 Skeleton from the burial No. 1. Bones available for study are filled with black

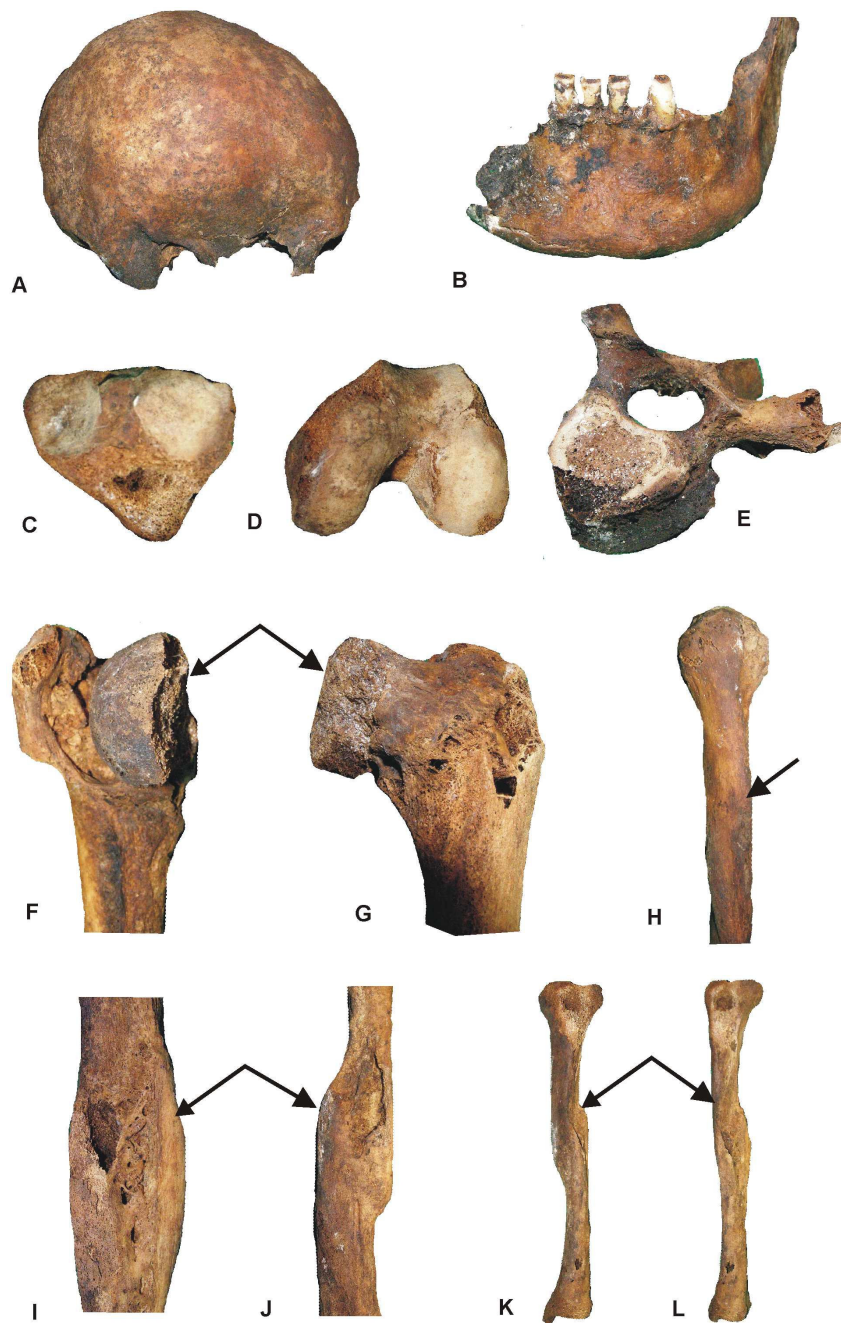
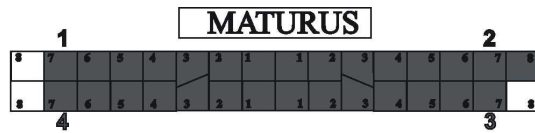


Figure 5 Details of masculine skeleton from burial No. 1. A – side view of neurocranium; B – fragment of the lower jaw; C – proximal joint surface of the left tibia; D – distal joint surface of the left femur; E – lumbar vertebra with compressed body; F, G – caput femoris caudally and cranially (arrows show the lost part); H – proximal half of the right humerus (arrow shows well developed muscular crest); I, J – place of fracture and inflammation of left tibia (arrows); K, L – left tibia (arrows point the place of abnormal fusion after the fracture).



Burial No. 2

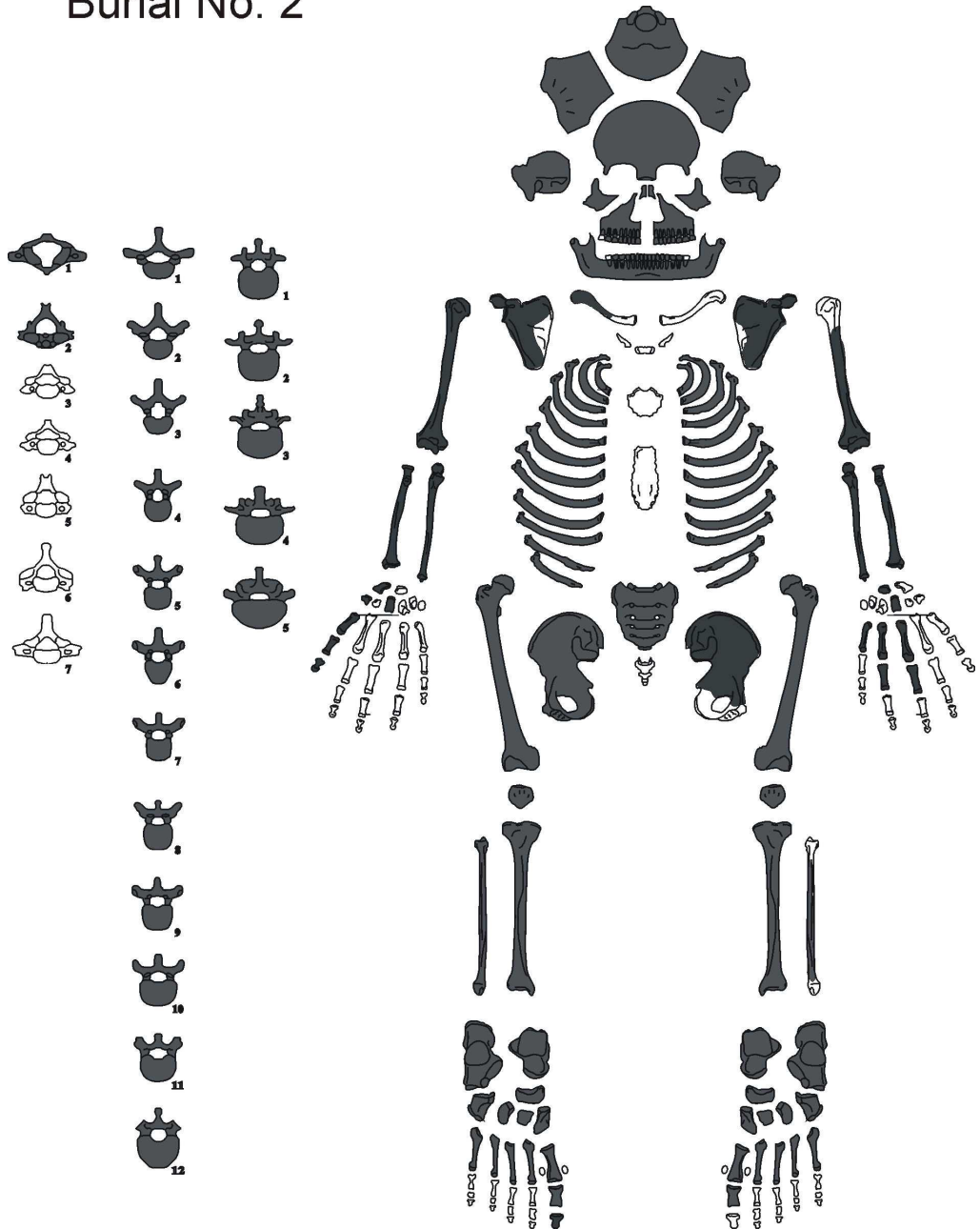


Figure 6 Skeleton from the burial No. 2. For abbreviations see Figure 4

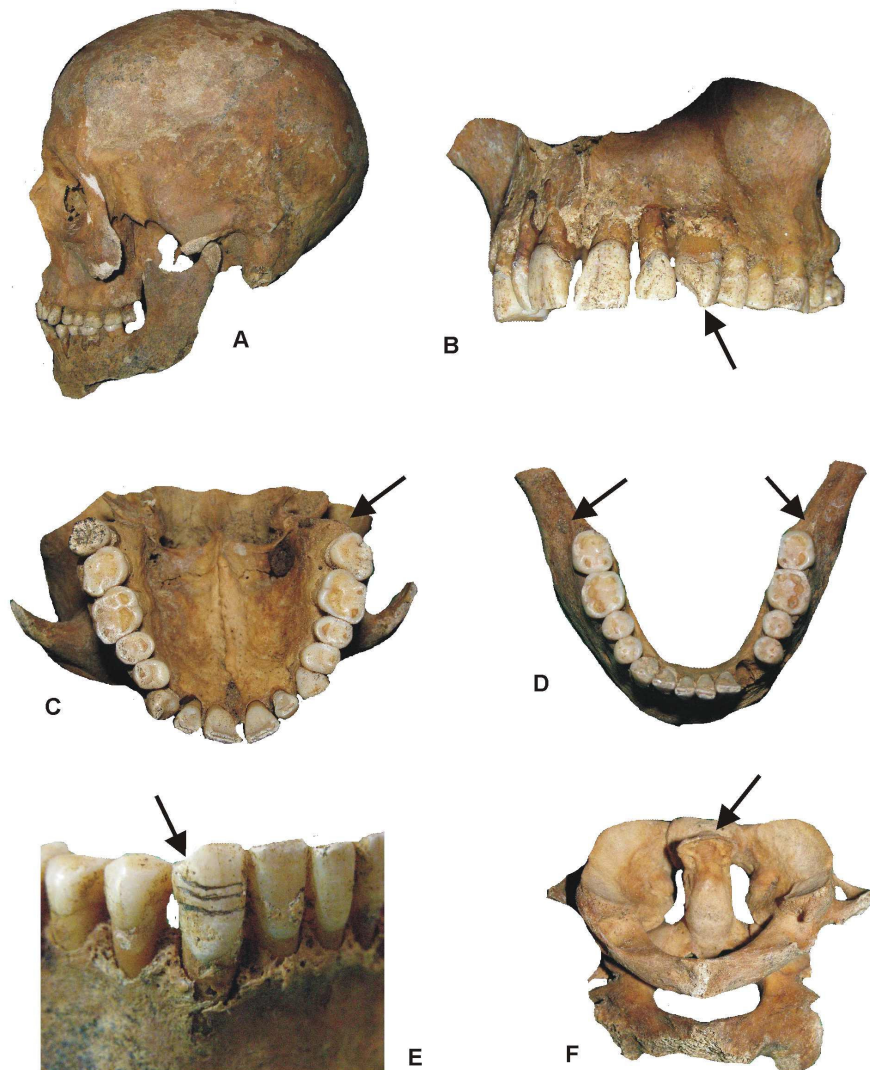


Figure 7 Fragments of skeleton from the burial No. 2. A – side view of the skull; B – fragment of the upper jaw frontolaterally (arrows points on the rotate canine), notice also the open roots due to the paradontosis; C – upper jaw masticatory (arrow points the absence of left upper third molar); D – lower jaw masticatory (arrows point the absence of both lower third molars); E – right lower canine with hypoplastic lines; F – atlas and axis (arrow points the anomaly in the region of contact the odontoid process with the first cervical vertebra).

MATURUS													
1										2			
am	pm	am	pm	am	pm	am	pm	am	pm	am	pm	am	pm
am	pm	am	pm	am	pm	am	pm	am	pm	am	pm	am	pm
4										3			

Burial No. 3

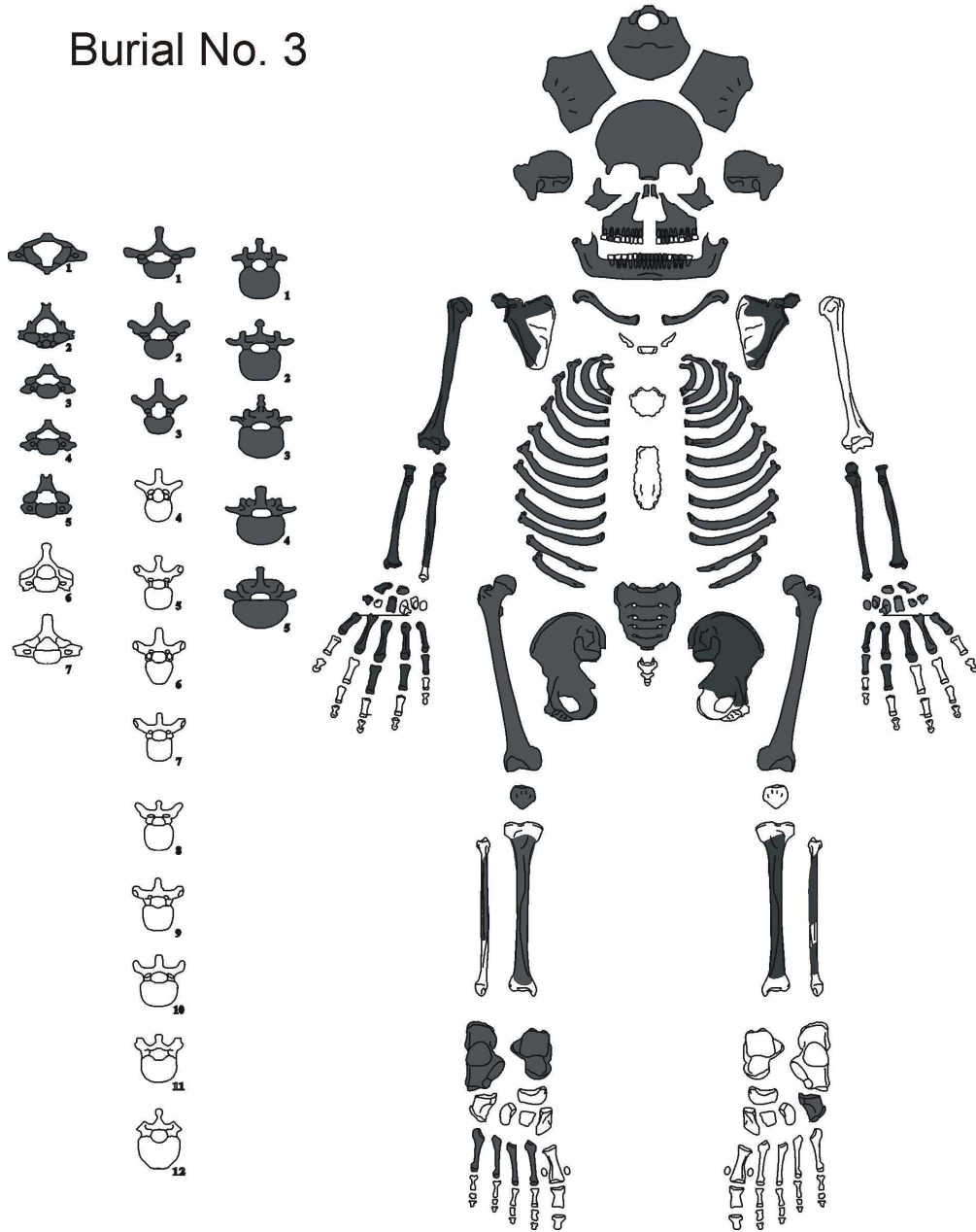


Figure 8 Skeleton from the burial No. 3. For abbreviations see Figures 4 and 6

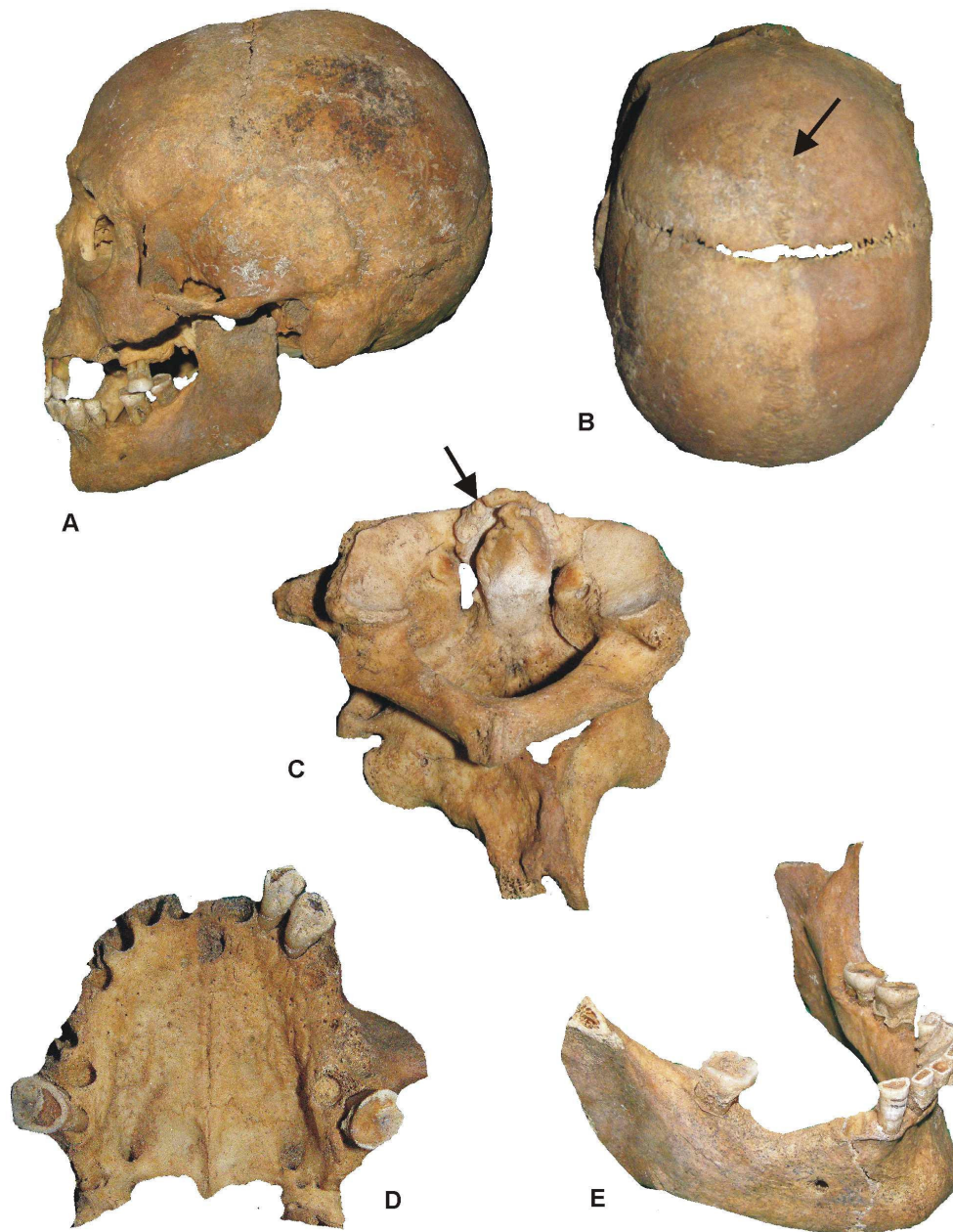


Figure 9 Fragments of skeleton from the burial No. 3. A – side view of the skull; B – skull from the top (arrow points still visible metopic suture); C – atlas and axis (arrow points the anomaly in the region of contact the odontoid process with the first cervical vertebra); D – upper jaw masticatory; E – lower jaw frontolaterally (notice the absence of teeth, fallen out antemortem, as well as traces of paradontosis. Canine bears hypoplastic lines.

Conclusion

Skeletons, found on the course of excavations in Znamenskaya Church of the former Savvaty Monastery, belong to two mature and one senile individual. The latter stays apart by its older age, better physical development and big stature. Being, undoubtedly, important person of his time due to the rich limestone sarcophagus and place of burial in the Church, this individual can be identified in historical records by remarkable stature, age, lameness, and compensatory bending of the back. Studying the historical records of XIV-XV centuries, related to the Great Principdom of Tver, may help to identify this person. Features of the skeleton from the sarcophagus do not undoubtedly point on its belonging to Savvaty. Two other men, buried by the sarcophagus, are more ordinary people of those times. The remarkable feature of both is an anomaly of first two cervical vertebrae. If this anomaly is genetically determined, then it is possible to tell of the close kinship of buried.

Acknowledgements

I am grateful to Father Andrei (Egorov), archpriest of Znamenskaya Church in Savvatievo, who provided the osseal material for present study. Vladimir Khukharev (Tver Scientific and Research Restoration Centre, Tver, Russia) made this study possible.

References

1. Alekseev VP. Osteometry. Moscow: Nauka; 1966. (in Russian).
2. Alekseev VP, Debets GF. Craniometry, Methods of anthropological research. Moscow: Nauka; 1964.
3. Ashley-Montagu MF. Aging of the skull. *American Journal of Physical Anthropology*. 1938; 23(3):355-75.
4. Bass WM. Human osteology: A laboratory and field manual. Columbia: Missouri Archaeological Society; 1995.
5. Brooks S, Suchey J. Skeletal age determination based on the os pubis: a comparison of the Acsadi-Nemesken and Suchey-Brooks methods. *Human Evol* 1990; 5:227-38.
6. Brooks ST. Skeletal age at death: The reliability of cranial and pubic age indicators. *Am J Phys Anthropol* 1955; 13(4):567-97.
7. de Mendonca MC. Estimation of height from the length of long bones in a Portuguese adult population. *Am J Phys Anthropol* 2000; 112(1):39-48.
8. Dobrovolskaya MB, Mednikova MB. Expertise of osseal remains from burials of Savvatiev Monastery near village Savvatievo (Kalinin area, Tver region). Moscow: Institute of Archeology of the Russian Academy of Sciences; 2009a. 6 p. (in Russian).
9. Dobrovolskaya MB, Mednikova MB. Preliminary expertise of osseal remains from limestone sarcophagus, found in altar region of Znamenskaya Church of Savvatiev Monastery in the village Savvatievo of Kalinin area (Tver region). Moscow: Institute of Archeology of the Russian Academy of Sciences; 2009b. 5 p. (in Russian).
10. Duyar I, Pelin C, Zagyapan R. A new method of stature estimation for forensic anthropological application. *Anthrop Sci* 2006; 114(1):23-7.
11. Erlich EP. Complex study of human vertebral bodies for age and sex determination. PhD thesis. Moscow: 1993. (in Russian).
12. Graves WW. Observations on age changes in the scapula. A preliminary note. *Am J Phys Anthropol* 1922; 5(1):21-33.
13. Haglund WD, Galloway A, Simmons T. Practical forensic anthropology of human skeletal remains recovery analysis & resolution. Crc Press; 2002.
14. Halcrow SE, Tayles N. Stress near the start of life? Localized enamel hypoplasia of the primary canine in late prehistoric

- mainland Southeast Asia. *J Archeol Sci* 2008; 35(8):2215-22.
15. Jantz RL. Modification of the Trotter and Gleser female stature estimation formula. *J Forensic Sci* 1992; 37:1230-5.
 16. Kelley MA. Phenice's visual sexing technique for the os pubis: A critique. *Am J Phys Anthropol* 1978; 48(1):121-2.
 17. Kurki H. Use of the first rib for adult age estimation: a test of one method. *International Journal of Osteoarchaeology*. 2005; 15(5):342-50.
 18. Lee MM. Problems in combining skeletal age for an individual. *Am J Phys Anthropol* 1971; 35(3):395-8.
 19. Levesque GY, Demirijian A, Tanguay R. Sexual dimorphism in the development, emergence, and agenesis of the mandibular third molar. *J Dent Res* 1981; 60:1735-41.
 20. Lovejoy CO, Meindl RS, Mensforth RP, Barton TJ. Multifunctional determination of skeletal age at death: a method and blind tests of its accuracy. *Am J Phys Anthropol* 1985; 68(1):1-14.
 21. Lundy JK. The mathematical versus anatomical methods of stature estimate from long bones. *Am J Forensic Med Path* 1985; 6:73-6.
 22. Mall G, Hubig M, Buttner A, Kuznik J, Penning R, Craw M. Sex determination and estimation of stature from the long bones of the arm. *Forensic Sci Int* 2001; 117(1-2):23-30.
 23. Mays S. *The archaeology of human bones*. London: Routledge, an imprint of Taylor & Francis Books; 1998.
 24. Meindl RS, Lovejoy CO, Mensforth RP, Carlos LD. Accuracy and direction of error in the sexing of the skeleton. *Am J Phys Anthropol* 1985; 68(1):79-85.
 25. Oezaslan A, Iscan MY, Oezaslan I, Tugcu H, Koc S. Estimation of stature from body parts. *Forensic Sci Int* 2003; 132(1):40-5.
 26. Pelin C, Duyar I. Estimating stature from tibia length: a comparison of methods. *J Forensic Sci* 2003; 48:708-12.
 27. Phenice TW. A newly developed visual method of sexing the os pubis. *Am J Phys Anthropol* 1969; 30(2):297-301.
 28. Pryor JW. Time of ossification of the bones of the hand of the male and female and union of epiphyses with the diaphyses. *Am J Phys Anthropol* 1925; 8(4):401-10.
 29. Reid D, Dean M. Brief communication: the timing of linear hypoplasia on human anterior teeth. *Am J Phys Anthropol* 2000; 113:135-9.
 30. Ritzman TB, Baker BJ, Schwartz GT. A fine line: A comparison of methods for estimating ages of linear enamel hypoplasia formation. *Am J Phys Anthropol* 2008; 135(3):348-61.
 31. Rösing FW. Körperhöhenrekonstruktion aus Skelettmassen. Knussmann R, editor. *Anthropologie: Handbuch der Vergleichenden Biologie des Menschen*. Stuttgart: Gustav Fischer; 1988. S. 586-600.
 32. Schmitt A. Age-at-death assessment using the os pubis and the auricular surface of the ilium: a test on an identified Asian sample. *Int J Osteoarch* 2004; 14(1):1-6.
 33. Sjøvold T. Stature estimation from the skeleton. Siegel JA, Saukko PJ, Knupfer GC, editors. *Encyclopedia of Forensic Sciences*. Vol. 1. London: Academic Press; 2000. p. 276-83.
 34. Stevenson PH. Age order of epiphyseal union in man. *Am J Phys Anthropol* 1924; 7(1):53-93.
 35. Todd T. Age changes in the pubic bone. *Am J Phys Anthropol* 1921; 4(1):1-70.
 36. Todd TW, Lyon DWJr. Endocranial suture closure. Its progress and age relationship. Part I. - Adult males of white stock. *Am J Phys Anthropol* 1924; 7(3):325-84.
 37. Zinoviev AV. A study of human osseal remains from the "Cholera Cemetery" archaeological site (Tver, Russia). *Bull Intern Assoc Paleodont* 2007; 1(2):12-7.
 38. Zinoviev AV. A study of human osseal remains from archaeological excavations in Saint-Assumption Trinity Monastery (Staritsa, Tver District, Russia). *Bull Intern Assoc Paleodont* 2008; 2(1):4-18.