

Gynaecol Perinatol 2010;19(3):129–135

Faculty of medicine, Al Azhar University, Cairo, Egypt

SURGICAL TREATMENT OF STRESS URINARY INCONTINENCE, FECAL INCONTINENCE AND VAGINAL PROLAPSE BY A NOVEL OPERATION »URETHRO-ANO-VAGINOPLASTY«

**KIRURŠKO LIJEČENJE STRES URINARNE INKONTINENCIJE,
FEKALNE INKONTINENCIJE I VAGINALNOG PROLAPSA
NOVOM OPERACIJOM »URETRO-ANO-VAGINOPLASTIKA«**

*Abdel Karim M. El Hemaly, Laila A. Mousa, Ibrahim M. Kandil,
Fatma S. El Sokkary, Ahmad G. Serour, Hossam Hussein*

Original paper

Key words: urethro-ano-vaginoplasty, internal urethral sphincter, internal anal sphincter, fecal incontinence, stress urinary incontinence

SUMMARY. We put forward a novel concept explaining the mechanism of micturition and the factors that control urinary continence. Also, we describe the mechanism of defecation and the factors that control stool continence and prevent fecal incontinence. A weak *internal urethral sphincter* (IUS) will not withstand sudden rise of intra-abdominal pressure and urine will leak. The weakness of the IUS is mostly due to traumatic rupture of its wall as a result of the huge vaginal distension that happens during prolonged, difficult and multiple frequent labors. So, surgical correction is by exposing that rupture and mending its walls. Also the marked vaginal distension which occurs in labor will cause lacerations in the *internal anal sphincter* (IAS) which is intimately related to the posterior vaginal wall. The torn weak IAS will cause fecal incontinence (FI). Exposing the torn IAS and mending the torn walls will restore the sphincter strength and fecal continence. *Vaginal prolapse* occurs as a result of vaginal wall weakness, redundancy and flabbiness subsequent to its marked stretching of its walls during vaginal deliveries. Overlapping the vaginal flaps both in the anterior and posterior vaginal wall, such repair will strengthen the vaginal walls, as if we put a collagenous mesh but instead this is an autologous collagenous mesh. We innovated an operation called »urethro-ano-vagino-plasty« to surgically treat urinary incontinence, fecal incontinence and vaginal prolapse. **Objectives.** To describe this novel operation, and assess its results for a follow up period of 24 months. **Methods.** 134 patients with SUI and FI were assessed. Urethro-ano-vaginoplasty was done, and the results were assessed immediately and for 24 months follow up. **Results.** 121 (90.3%) gained urinary and fecal continence and remained continent in the follow up period. **Conclusion.** The internal anal sphincter (IAS) is a collageno-muscular tissue cylinder that surrounds the anal canal innervated by alpha-sympathetic nerve supply from the hypogastric nerves. It is surrounded in its lower part by the EAS which is a striated muscle innervated by the pudendal nerve. Its damage during childbirth causes fecal *incontinence* and mending the torn walls restores fecal *continence*.

Izvorni članak

Ključne riječi: uretro-ano-vaginoplastika, unutarnji uretralni sfinkter, unutarnji analni sfinkter, fekalna inkontinencija, stress urinarna inkontinencija

SAŽETAK. Predstavljena je nova koncepcija o mehanizmu mokrenja i čimbenicima koji reguliraju mokraćnu kontinenciju. Također, opisan je mehanizam defekacije te čimbenici koji kontroliraju kontinenciju stolice i sprječavaju fekalnu inkontinenciju. Slab *unutarnji uretralni sfinkter* (IUS) se ne može suprotstaviti naglom porastu intraabdominalnog tlaka te će mokraću bježati. Slabost IUS-a je većinom posljedica ozljede njegove stijenke zbog silnog vaginalna širenja koje se zbiva tijekom produljenih, teških i učestalih rađanja. Kirurška korekcija se sastoji u nalaženju prsnuća i opskrbi njegove stijenke. Vaginalno širenje tijekom poroda uzrokuje prsnuće *unutarnjeg analnog sfinktera* (IAS), koji je intimno povezan sa stražnjom vaginalnom stijenkom. Oslabljeni i prsnuti IAS uzrokuje fekalnu inkontinenciju (FI). Prikaz prsnutog IAS-a i šivanje njegovih razderanih stijenki uspostaviti će snagu sfinktera i fekalnu kontinenciju. *Vaginalni prolaps* nastaje kao posljedica slabosti i mlohavosti vaginalne stijenke te njene proširenosti, zbog istežanja tijekom vaginalnog rađanja. Preklapanjem vaginalnih režanja prednje i stražnje stijenke ojačava se stijenka, umjesto umjetne mrežice postava-

vljamo vlastitu autolognu kolagenu mrežicu. Izumjeli smo za korekciju urinarne i fekalne inkontinencije te vaginalna prolapsa novu operaciju i nazvali je »uretro-ano-vagino-plastika«. **Cilj rada** je opisati novu operaciju i prosuditi njen uspjeh nakon 24 mjeseca. **Metoda.** Operirane su 134 bolesnice sa stres urinarnom inkontinencijom i fekalnom inkontinencijom. **Rezultati.** 121 bolesnica (90,3%) je opet postigla mokraćnu i fekalnu kontinenciju i zadržala ih tijekom praćenja. **Zaključak.** Unutarnji analni sfinkter je kolegano-mišićni tkivni cilindar, inerviran alfa-simpatičnim živcima iz hipogastričkog pleksusa koji okružuje analni kanal. U donjem dijelu je okružen vanjskim sfinkterom koji je poprečno-prugaste mišićne građe i inerviran ograncima pudendalnog živca. Njegovo oštećenje tijekom rađanja uzrokuje fekalnu inkontinenciju, a šivanje prsnute stijenke uspostavlja fekalnu kontinenciju.

Introduction

We put forward a novel concept explaining the mechanism of micturition and the factors that control urinary continence.^{1–3} Also, we describe the mechanism of defecation and the factors that control stool continence and prevent fecal incontinence by a new concept. A weak internal urethral sphincter (IUS) will not withstand sudden rise of intra-abdominal pressure, intra-vesical pressure and urine will leak. The woman will be embarrassed, and a quick reflex reactive sympathetic activity will increase the existing acquired high alpha-sympathetic tone at the IUS preventing further urinary leakage. The weakness of the IUS is mostly due to traumatic rupture of its wall as a result of the huge vaginal distension that happens during prolonged, difficult and multiple frequent labors. So, surgical correction is by exposing that rupture and mending its walls.

Also the marked vaginal distension which occurs in labor will cause lacerations in the internal anal sphincter (IAS) which is intimately related to the posterior vaginal wall. The torn weak IAS will cause fecal in-

tinence (FI). Exposing the torn IAS and mending the torn walls will restore the sphincter strength and fecal continence.

Vaginal prolapse occurs as a result of vaginal wall weakness, redundancy and flabbiness subsequent to its marked stretching of its walls during vaginal deliveries. Overlapping the vaginal flaps both in the anterior and posterior vaginal wall repair will strengthen the vaginal walls, like as if we put a collagenous mesh but instead this is an autologous collagenous mesh.

We innovated an operation »Urethro-Ano-Vagino-plasty« to surgically treat UI and FI and vaginal prolapse. We call the operation »Urethro-Ano-Vaginoplasty«, in which:

- We mend the torn IUS causing stress urinary incontinence, detrusor overactivity and mixed type of urinary incontinence.
- We mend the torn IAS causing fecal incontinence.
- We strengthen the flabby redundant vaginal walls by overlapping longitudinally the two vaginal flaps, (instead of cutting away any extra vaginal tissue).

Visualizing the defect in the IUS and the IAS and mending the torn walls will restore the sphincter's strength. Further support of the IUS and strengthening the prolapsed flabby anterior vaginal wall, and similarly strengthening the redundant prolapsed posterior vaginal wall, adding more support to the IAS and narrowing the patulous vagina and the genital hiatus are our aim by doing urethro-ano-vaginoplasty.

Objectives. To describe this novel operation, and assessing its results for a follow up period of 24 months.

Materials and methods

The study was carried out starting January 2006 to January 2008. The study was approved by the local Ethics Committee.

Twenty continent women as a control group and 134 patients suffering from vaginal prolapse, SUI and FI as proved clinically (medical history and examination) by urodynamic evaluation and by 3D ultrasound studies were chosen for the study.

All the 134 patients had been evaluated at the Urogynaecology & Pelvic Floor Clinic. Evaluation included special questionnaire that inquire about lower urinary tract function and its social impact. Also questionnaire that inquire about fecal incontinence, stool and/or flatus. The questionnaire ended in identifying stress urinary incontinence and fecal incontinence. Following

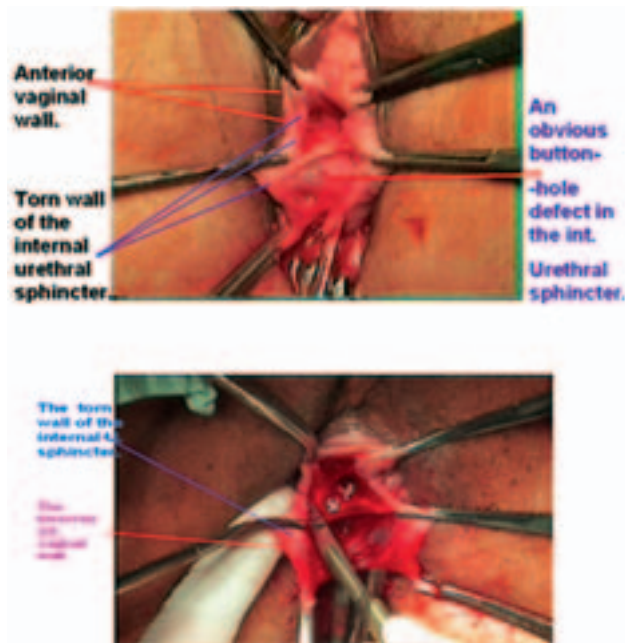


Figure 1. After bisecting the anterior vaginal wall, the rupture in the IUS can be noticed; kindly notice there are 2 edges, one of the torn IUS and the other of the bisected anterior vaginal wall.

Slika 1. Nakon raspolavljanja prednje vaginalne stijenke vidi se razdor unutarnjeg uretralnog sfinktera. Obratite pozornost: dva su ruba, jedan je razderanog unutarnjeg razderanog sfinktera, drugi rub je razdvojene prednje vaginalne stijenka.

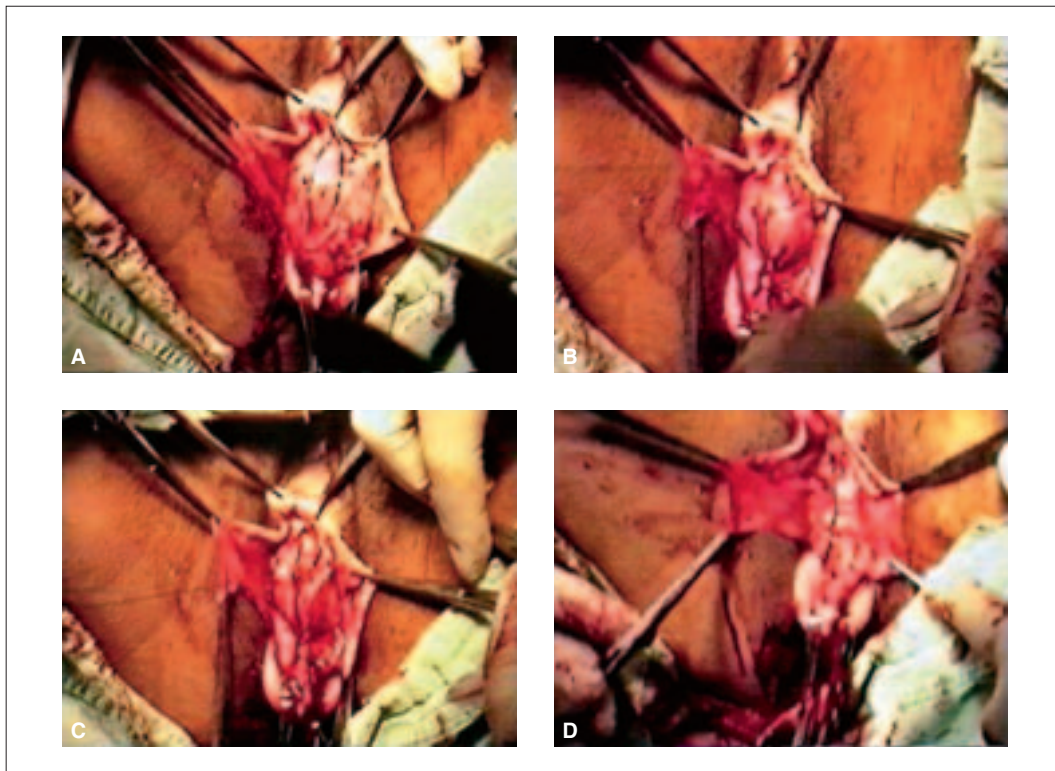


Figure 2. After carefully dissecting the walls of the IUS from the anterior vaginal wall, we start to mend the rupture in the IUS walls with connective simple interrupted sutures.

Slika 2. Nakon brižnog razdvajanja unutarnjeg uretralnog sfinktera od prednje vaginalne stijenke započinje se popravak razderanog unutarnjeg uretralnog sfinktera s jednostavnim prekidanim šavima.

recruitment, each patient was asked to keep a voiding diary to assess the severity of the leakage, and to monitor the results in the pre-operative and the post-operative follow up period.

Then, physical examination, measurement of any residual urine, urinalysis and tests for bacteriological culture and sensitivity were done, and accordingly treated from any infection.

Urodynamic studies, namely cystometry, pressure profiles e.g. urethral pressure profile (UPP), stress cysto-urethral pressure profilometry and leak-point pressure were done before surgery and after surgery at the follow up periods⁴.

Three dimension ultrasound (3DUS) assessment of the IUS and IAS was done for the 20 continent women as control and for each patient of the 134 study group cases using trans-vaginal route and trans-perineal route by a vaginal probe multi-frequent 5–7.5 MHz, General Electric, integrated 3D-4D Unit (GE Volosone) 730 Pro V machine.

The operation »urethro-ano-vaginoplasty« was done for the 134 patients. The patients were suffering from:

1. Anterior vaginal wall descent (Figure 1).
2. Urinary Incontinence (SUI, DO and Mixed-type of UI).
3. Fecal incontinence.

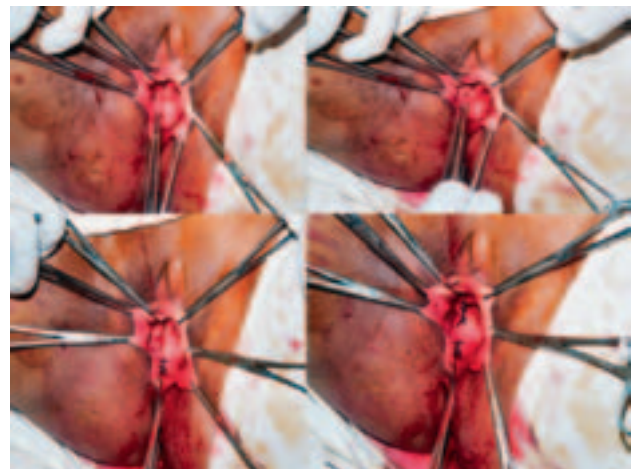


Figure 3. Mending the torn walls of the IUS is done. Kindly notice the thickness of the collagenous part of the IUS walls.

Slika 3. Šivanje razderanog ruba unutarnjeg uretralnog sfinktera. Obratite pozornost na debljinu koleganog dijela unutarnjeg sfinktera.

4. Posterior vaginal wall descent (rectocele – Figure 7.)

Patients suffering, from posterior vaginal wall prolapse (Bp-1 to +2cm and short perineum Pb less than 2cm were included.

Urethro-ano-vaginoplasty under general or regional anesthesia was done.

The operation consists of two main parts, e.g. anterior and posterior repair. The **anterior repair** has 2 main steps. *First step* is to expose the rupture in the posterior wall of the IUS, and to mend it by consecutive, simple interrupted sutures (urethro-raphy), using slowly absorbable suture material e.g. polyglycan (Vicryl 0). (Figures 1-3). *Second step* is to correct the flabby, lax and damaged prolapsed anterior vaginal wall, aiming at getting a tough narrow unprolapsed vagina and, also, providing additional strength and support to the IUS. (Figures 4-6).

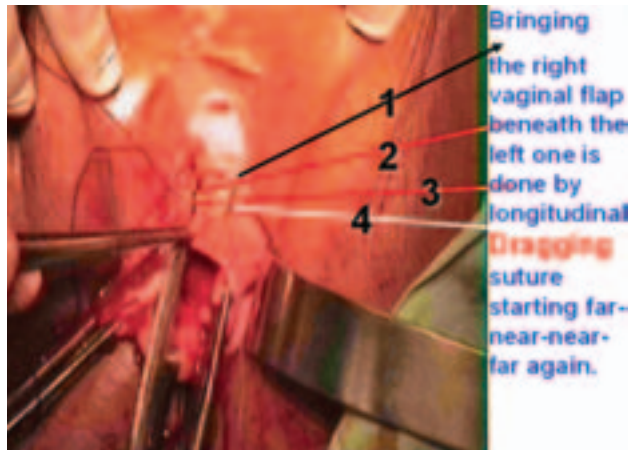


Figure 4. After mending the IUS, we start strengthen the anterior vaginal wall by dragging the right vaginal flap beneath the left one by this novel dragging sutures.

Slika 4. Nakon šva unutarnjeg uretralnog sfinktera započinje učvršćivanje prednje vaginalne stijenke uvlačenjem desnog reznja pod lijevi novim šavima.

After carefully mending the torn posterior wall of the IUS, the lax, overstretched anterior vaginal wall is then repaired by overlapping the two longitudinally bisected anterior vaginal wall flaps, over the mended IUS. Bringing the right vaginal flap beneath the left one, this is done by consecutive longitudinal dragging sutures. We start beneath the external urethral orifice going up the »made« transverse incision in the anterior vaginal wall on the cervix. Each stitch we start with the needle on the left flap far laterally, then going to the edge of the right flap (near), then going with the needle on the right edge externally, lower down, about 3-5 mm. (near) then going far again on the left flap 5 mm below the start point (far). Far-near-near-far. (Figure 4).

When we tie the 2 arms of the thread together this will bring the right flap beneath the left one. This is repeated 4-6 times till the »made« transverse incision we cut in the anterior vaginal wall. This will leave a free edge of the left flap which is sutured as far laterally on the right side of the vagina, starting below the external urethral orifice by interrupted sutures going up to the original transverse incision. This will bring the vagina upwards to its original site and enforce the anterior vaginal wall and support the overlying mended IUS.

The **posterior repair** (Figures 7-11) consists of three main steps: the *first step* is to expose the torn IAS and to mend it by consecutive simple interrupted sutures by slowly absorbable suture material, polyglycan (e.g. Vicryl 0). *Second step* is to approximate the two levators ani muscles in front of the anal canal to keep the acute recto-anal angle. *Third step* is to overlap longitudinally the bisected posterior vaginal wall by consecutive drag-

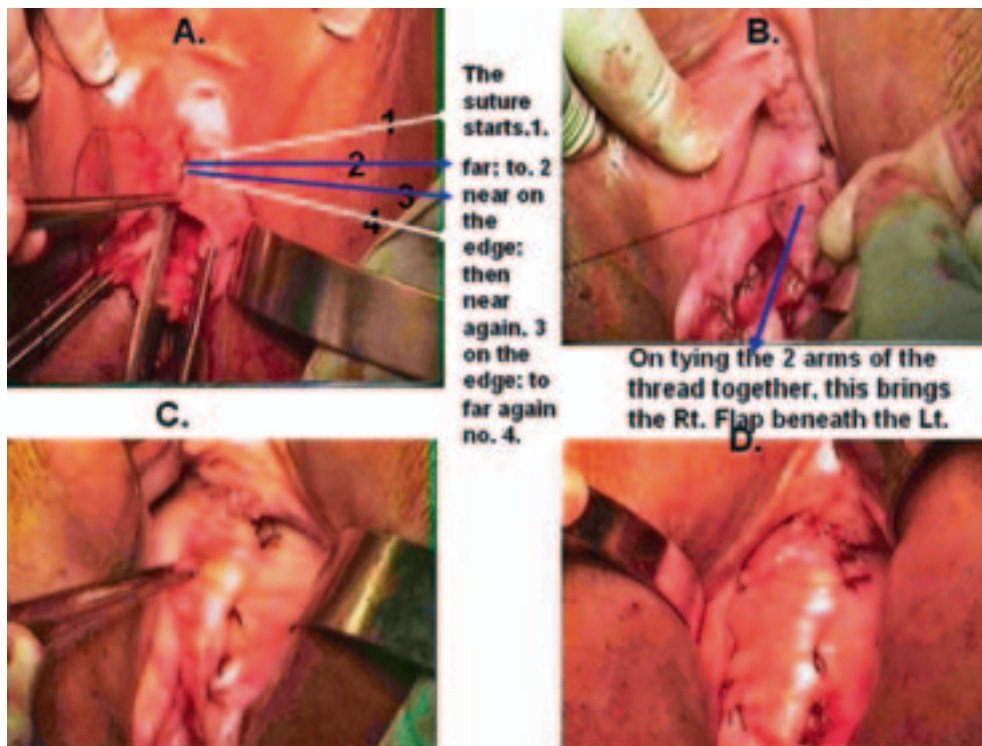
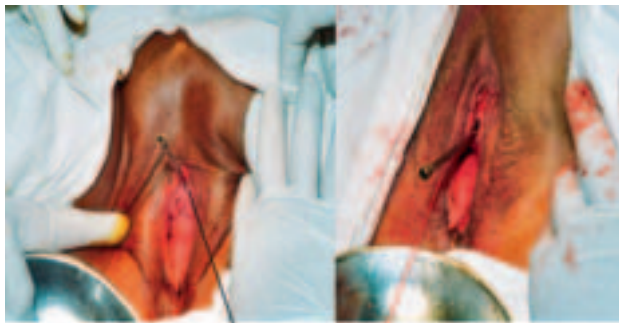


Figure 5. After completing dragging the right vaginal flap beneath the left one, we start suturing the free edge of the left vaginal flap as far laterally on the right side of the vagina.

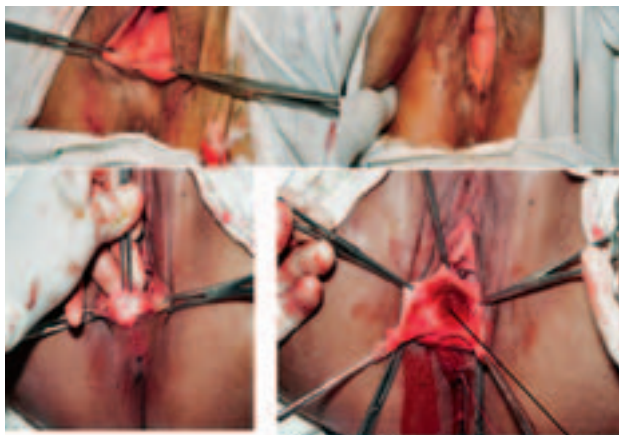
Slika 5. Nakon završenog uvlačenja desnog reznja pod lijevi učvršćuje se šavima lijevi vaginalni reznj na desnu stranu koliko je god to moguće.



Kindly notice the direction of the metal catheter before the operation and after the Urethro-Vaginoplasty.

Figure 6. After finishing mending the IUS and supporting the anterior vaginal wall, kindly notice the difference in the direction of both the catheter and the anterior vaginal wall before and after surgery.

Slika 6. Završivši šivanje unutarnjeg uretralnog sfinktera i učvrstivši prednju vaginalnu stijenku vidi se razlika smjera katetera i prednje vaginalne stijenke prije i nakon operacije.



Kindly notice 2 edges, the upper, torn, and the lower, the ant. Wall of the IAS torn.

Figure 7. Rectocele, the posterior vaginal wall is bulging without straining, we start dissecting the posterior vaginal wall away from the intimately underlying IAS.

Slika 7. Rektokela. Stražnja vaginalna stijenka se izbočuje i bez napinjanja. Počinje disekcija stražnje vaginalne stijenke od priležećeg unutarnjeg analnog sfinktera.

ging sutures to bring the right flap beneath the left one, then suturing the free edge of the left flap laterally in the right side of the posterior wall of the vagina.

This is carried out by cutting transversal incision at the posterior vagino-skin junction for about 5 cm. Our upper limit for dissection is marked by »Kocher« forceps we put it about 2 cm above and beyond the summit of the posterior vaginal bulge. We dissect the posterior wall of the vagina from the anal canal and its sphincter from below upwards, and bisect it into 2 flaps. Kindly notice there are 2 edges in each vaginal flap, one of the torn intimately lying IAS, and the other of the vagina. We separate the ruptured IAS from the vagina, mend it with consecutive interrupted sutures with »0« polyglycan thread. Then we approximate the 2 levators ani

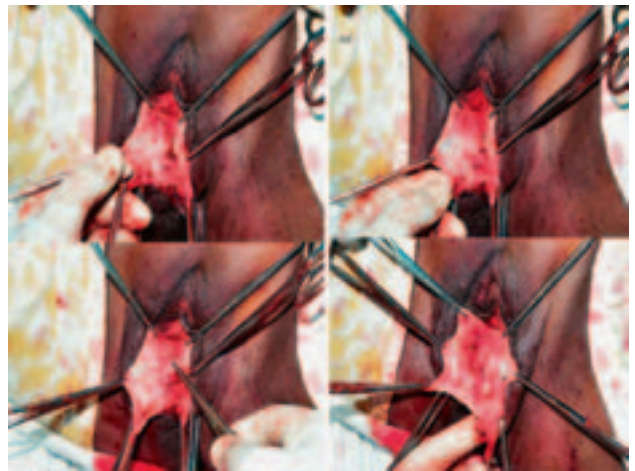


Figure 8. We start dissecting the posterior vaginal wall from the IAS, then we start to mend its torn walls.

Slika 8. Počinje disekcija stražnje vaginalne stijenke od analnog sfinktera te se zatim šiva njegove razderane rubove.

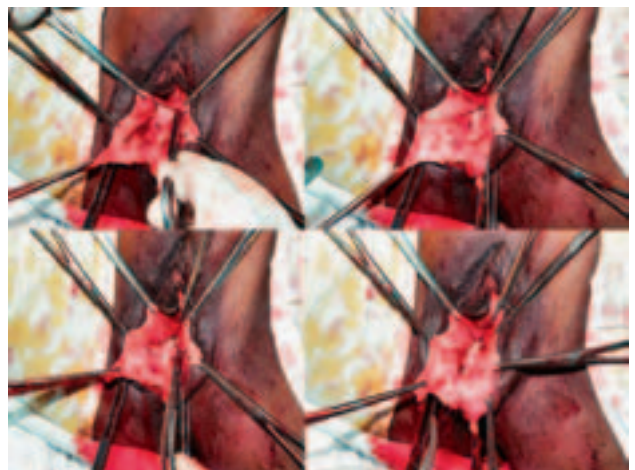


Figure 9. We mend the torn IAS, then we put approximating sutures in the levators ani (tie them later after repairing the vagina).

Slika 9. Šiva se razderani unutarnji analni sfinkter, nakon toga se postavljaju približavajući šavovi na mišić levator (šav se steže kasnije nakon reparature vagine).

muscles with 2–3 sutures, not tying them at that time in order not to narrow the field. Then we overlap the 2 vaginal flaps with consecutive dragging sutures bringing the right flap beneath the left one, and stitching the free edge of the left flap as far laterally on the right side.

Results

In urinary and fecal incontinence we assessed the patients using subjective criteria + objective clinical signs + 3DUS and urodynamics: 121 from the 134 patients, (90.3%), gained fecal and urinary continence immediately and successfully. They remained continent in the follow up period.

Patients with fecal incontinence are cured and regained control of the feces and flatus.

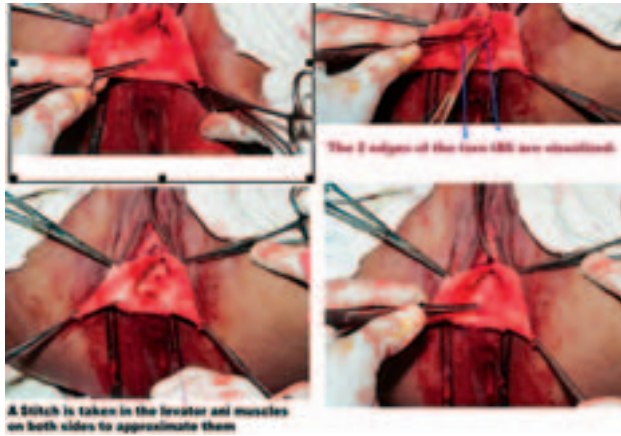


Figure 10. Kindly notice the very thick collagenous walls of the torn IAS. Stitches 2–3 are put in the levators ani muscles to be tied later on. Slika 10. Vrlo debela kolagena vlakna razderanog unutarnjeg analnog sfinktera. 2–3 uboda su postavljena na mišić levator, bit će stegnuta kasnije.

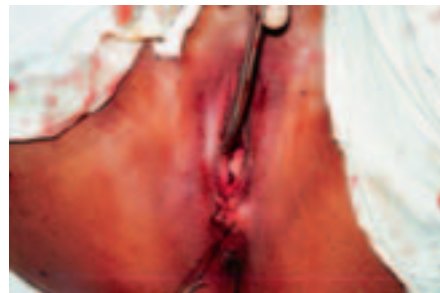
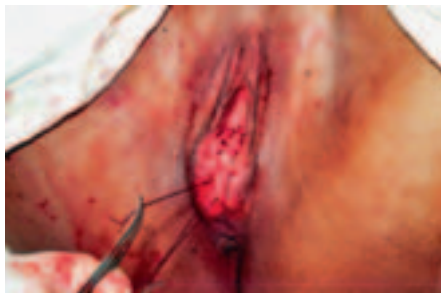
Figure 11. After mending the IAS, and supporting the posterior vaginal wall by overlapping technique the levators ani muscles sutures are tied and the perineum repaired. Slika 11. Nakon što je sašiven unutarnji analni sfinkter i poduprta stražnja vaginalna stijenka dvorežnjastom tehnikom, stegnute su šavi levatora i repariran perineum.

Discussion

The role of the IAS in keeping fecal continence and the mechanism of defecation is not properly understood nor has been described before. We put forward a novel concept on the physiology of defecation and showed the importance of the IAS. The IAS is a collageno-muscular tissue cylinder that surrounds the anal canal and is exposed to damage during vaginal childbirth, especially multiple frequent deliveries, instrumental and difficult vaginal deliveries. The childbirth's trauma will damage the posterior vaginal wall, the anterior rectal wall, and the IAS leading to rectocele and fecal incontinence.

Those injuries in addition to the clinical picture can be visualized by imaging by 3DUS.

Combined urinary incontinence and fecal incontinence are quite common, but sometimes there is a need for direct questions inquiring on unwanted or untimely release of feces and/or flatus. The clinical picture of »cysto-rectocele« is quite prevalent⁵. Posterior vaginal repair should include mending the torn IAS.

The repair of the EAS in cases of complete perineal tear, suturing the torn ends of the EAS, whether by end-to-end or overlapping is not quite successful. The IAS has to be repaired by mending its torn walls to get full fecal continence.

At the surgery for urinary incontinence attention, at first, is directed to elevation of the bladder neck, nar-

The lax flabby prolapsed vagina was repaired and strengthened without cutting and losing any vaginal tissue, saving its own collagen which also provides extra support for the IUS, and the IAS.

In the follow up period, there was improvement in 7 patients, a rate of (5.2%). Failure was recorded in 6 women, a rate of 4.5%.

Number of patients.	Success.	Improvement.	Failure.
Total no 134	121– (90.3%)	7– (5.2%)	6– (4.5%)

The anterior and the posterior vaginal walls regained their tough, strong, high unprolapsed position in all patients. With all points back to normal:

Aa-3 cm; Ba-5 cm; C at-8 to 9.5 cm; Gh 2-3 cm;

Ap-3 cm; Bp-5 cm; TVL 9-11 cm & Pb 3-4 cm.

rowing the bladder neck, restoring the angulations between the urethra and the urinary bladder and elongation of the urethra. Later the attention is focused on supporting the mid-urethra by inserting different tapes e.g. TVT, TOT and mini slings. The current enthusiasm for mid-urethral sling placement was sparked by the introduction of TVT procedure, and fueled by generous industry sponsorship and vigorous marketing. Initial reports of high success rates and low complication rates were followed by an increasing recognition that this »minimally invasive« procedure may be 'maximally erosive' and that its infective complications may be life-threatening. TOT was introduced to avoid risks associated with blind retropubic »harpooning« (bladder, bowel or iliac vessel perforation) but it probably has the same risks of infection and erosion.⁶

It is not the position of the bladder neck and its relation to the symphysis pubis which govern the continence of urine; it is the state of the IUS as demonstrated by the new concept.^{1–3} We describe a novel operation which treats urinary incontinence, fecal incontinence and vaginal prolapse, 'urethro-ano-vaginoplasty' at the same time.

The IUS as described by the new concept and as is seen by 3DUS imaging is a cylinder that extends from the bladder neck to the urogenital diaphragm and is not a muscular ring at the bladder neck. It is composed

mainly of collagen sheet, a very strong tissue that gives the IUS the high wall tension necessary for creating high UPP. There are muscle fibers that intermingle with the collagen in the middle of the cylinder's thickness innervated by alpha sympathetic nerves (T10-L2) that is responsible for opening and closing the urethral lumen. The muscle fibers are connected above with the detrusor muscle. The IUS is intimately lying on the anterior vaginal wall, so that lacerations affecting the vagina from over distention in childbirth will lacerate the posterior wall of the IUS, mainly its collagen sheet.

A tough and a strong anterior vaginal wall is an essential support for keeping the vagina in its upward position, and is a major support for the intimately overlying IUS and the lower part of the posterior wall of the urinary bladder on filling. A weak overstretched and flabby anterior vaginal wall will fall down (prolapse), with its overlying IUS and lower part of the posterior wall of the urinary bladder on filling. The strength and the toughness of the vaginal wall depend on its rich compact collagen fibers. The compact tough collagen bundles are also essential elements of keeping the vagina in its normal upward position without descending or falling down. As an example, a hard-cover book will stand upright on a shelf, while a paper-cover book will fall down.

The IAS is a collageno-muscular tissue cylinder that surrounds the anal canal and keeping it closed by the acquired high alpha sympathetic tone gained by learning and training in early childhood. A tough and strong posterior vaginal wall is a sound support for itself and the underlying rectum and anal canal.

Prolonged labor, difficult labor, multiple frequent labors, and operative vaginal deliveries cause over stretching of the vagina and attenuation, split and actual lacerations of the collagen bundles in the vagina causing weakness and laxity of the vaginal walls and the intimately IUS and IAS.

The stretching, attenuation, degeneration, split and lacerations which affect the anterior vaginal wall will affect the intimately overlying IUS causing rupture of its posterior wall. This will lead to a defective weak IUS with lowered UCP, and subsequent urinary incontinence on provocation.

Posterior damage to vaginal wall, rectum and IAS cause rectocele and fecal incontinence and an open anal canal as seen by 3DUS.

Conclusion

Posterior vaginal wall prolapse, rectocele, causes fecal incontinence, due to traumatic injury of the IAS which when mended will regain its function. A weak IUS with a low UCP is caused by traumatic rupture of its wall. The level and the extent of the rupture along the cylinder of the IUS will determine the type and severity of SUI, and the morphological changes seen on imaging.

Pelvic collagen is the skeleton of all pelvic organs, and is the main pillar for maintaining urinary continence, fecal continence and genital organs. Collagen is the most abundant protein in the body, and collagen fibers are the strongest tissue in our body. Collagen form the sclera, ligaments, tendons, rectus sheet and even the bones are ossified collagen. Pelvic collagen is hormone sensitive and undergoes atrophy after menopause which aggravates any weakness from previous childbirth trauma, and other types of trauma.

References

1. El Hemaly AKMA, Kandil IM, Kurjak A, Serour AG, Mousa LAS, Zaied AM, Khalid Z, El Sheikha KZ. Imaging the internal urethral sphincter and the vagina in normal women and women suffering from stress urinary incontinence and vaginal prolapse. *Gynaecol Perinatol* 2009;18(4):169–86.
2. El Hemaly AKMA, Mousa LA. Micturition and urinary continence. *Int J Gynecol Obstet* 1996;42:291–2.
3. El Hemaly AKMA. Nocturnal enuresis: Pathogenesis and treatment. *Int Urogynecol J Pelvic Floor Dysfunct* 1998;9:129–31.
4. McGuire EJ, Cespedes D, O'Connell HE. Leak-point pressures. *Urologic Clinics North Am* 1996; 23(2):253–62.
5. Djakovic A, Oreskovic S, Ivanisevic M, Juras J, Delmis J. Risk factors for development of pelvic floor injuries and urinary incontinence in women. *Gynaecol Perinatol* 2009;18(4):183–7.
6. Heyns C. Editor's note. *South African Urol Gynaecol Rev* 2009;6(Nr.2).

Paper received: March, 3, 2010; *accepted:* May, 20, 2010.

Address for correspondence: Prof. AKMA El Hemaly, FRCS, MRCOG, 3 emad el din kamel street, Nasr City, Cairo, Egypt, Post No: 11371, E-mail: profakhemaly@hotmail.com