

# VARIATIONS IN SHAPE, NUMBER AND POSITION OF TEETH IN STONE MARTENS FROM ISLAND HABITATS (CROATIA) – PRELIMINARY RESULTS

DEAN KONJEVIĆ<sup>1\*</sup>, VERA NJEMIROVSKIJ<sup>2</sup>,  
MARIJANA VUKOVIĆ<sup>3</sup>, ALEN SLAVICA<sup>1</sup>, ZDRAVKO JANICKI<sup>1</sup>,  
KREŠIMIR SEVERIN<sup>1</sup> & MAGDA SINDIČIĆ<sup>1</sup>

<sup>1</sup>Department for Game Biology, Pathology and Breeding, University of Zagreb  
Veterinary Faculty, Heinzelova 55, 10 000 Zagreb, Croatia

<sup>2</sup>Department for Dental Anthropology, Dental School University of Zagreb,  
Gundulićeva 5, 10 000 Zagreb, Croatia

<sup>3</sup>Croatian Natural History Museum, Demetrova 1, 10 000 Zagreb, Croatia

Konjević, D., Njemirovskij, V., Vuković, M., Slavica, A., Janicki, Z., Severin, K. & Sindičić, M.: Variations in shape, number and position of teeth in stone martens from island habitats (Croatia) – preliminary results. *Nat. Croat.*, Vol. 20, No. 1., 215–223, 2011, Zagreb.

A total of 27 skulls of stone martens (*Martes foina* Erx., 1777) from the Mediterranean island habitat were examined for dental abnormalities. Irregular arrangement of lower incisors was observed in 7 individuals (25.9%). The P<sub>1</sub> was absent bilaterally in 6 (22%) and unilaterally in 5 individuals (18.5%). In contrast, the P<sup>1</sup> was absent only unilaterally in 2 cases (7.4%). Of other teeth, I<sup>1</sup> was absent unilaterally in 2 cases (7.4%), while I<sup>2</sup>, C<sup>1</sup> and P<sup>3</sup> were missing in one case respectively (3.7%). We found only one supernumerary tooth, the upper right premolar. This condition was associated with rotation of P<sup>2</sup> and P<sup>3</sup> as a consequence of overcrowding. Rotation was observed on 6 premolars in total (two lower and four upper). Complicated crown fractures were observed on three skulls (11%). Fractures were only found on canines. Porosity of the alveolar bone was observed in one case of a fractured canine. Pronounced tooth wear was recorded in 7 skulls (25.9%). Congenital absence of teeth is a frequent finding in all carnivores, reflecting the evolutionary trend to a reduction of the number of teeth. The relatively low incidence of tooth fractures and the almost complete absence of periodontal diseases can be attributed to the fact that the majority of examined skulls originated from adolescent animals.

**Keywords:** stone marten, tooth, dental abnormalities

\* corresponding author: dean.konjevic@vef.hr, member of the Martes Working Group

Konjević, D., Njemirovskij, V., Vuković, M., Slavica, A., Janicki, Z., Severin, K. & Sindičić, M.: Varijacije u izgledu, broju i položaju zuba kuna bjelica s otočnih staništa (Hrvatska) – preliminarni rezultati. *Nat. Croat.*, Vol. 20, No. 1., 215–223, 2011, Zagreb.

Ukupno 27 lubanja kuna bjelica (*Martes foina* Erx., 1777) podrijetlom sa otočnog mediteranskog staništa je pregledano na zubne anomalije. Nepravilan raspored donjih sjekutića zamijećen je u 7 jedinki (25,9%). Obostrani nedostatak P<sub>1</sub> zabilježen je u 6 (22%) odnosno jednostrano u 5 jedinki (18,5%). Nasuprot tomu, P<sup>1</sup> je nedostajao isključivo jednostrano, u dva slučaja (7,4%). Od ostalih zuba, nedostatak I<sup>1</sup> je zabilježen u dva slučaja jednostrano (7,4%), dočim su I<sup>2</sup>, C<sup>1</sup> i P<sup>3</sup> nedostajali po jednom (3,7%). Prekobrojni zub je uočen samo u jednom slučaju, i to kao desni pretkutnjak, praćen zakretanjem P<sup>2</sup> i P<sup>3</sup>, kao posljedice prekobrojnosti zuba. Zakretanje zuba je zabilježeno u slučaju još 6 pretkutnjaka (dva donja i četiri gornja). KomPLICIRANI prijelomi zuba zamijećeni su na tri lubanje (11%). Prijelomi su nadđeni isključivo na očnjacima. Poroznost pripadajuće alveolarne kosti je primijećena samo iznad jednog prelomljenog očnjaka. Konačno, izraženo trošenje zuba utvrđeno je na 7 lubanja (25,9%). Uočen nedostatak pojedinih zuba je relativno čest nalaz u svih pripadnika skupine mesojeda, odražavajući time evolucijski trend smanjenja broja zuba. Relativno rijedak nalaz prijeloma zuba i gotovo potpuni nedostatak periodontitisa može se pripisati činjenici da je većina prikupljenih lubanja potječe od mladih životinja.

**Ključne riječi:** kuna bjelica, zub, zubne anomalije

## INTRODUCTION

The stone marten (*Martes foina* Erx., 1777) is a medium-sized carnivore species from the mustelid family that inhabits a large part of Europe and Asia. In Croatia, stone martens are distributed throughout the country, from continental to karst and Mediterranean habitats, their territory overlapping with that of a close relative, the pine marten (*Martes martes* L., 1758) (MITCHELL-JONES *et al.*, 1999; JANICKI *et al.*, 2007). The dental formula of stone martens comprises 38 teeth aligned in the following dental formula: I 3/3; C 1/1; P 4/4; M 1/2. Despite the fact that stone martens are originally a carnivorous species, they are actually opportunistic animals that feed on both animals and fruits (BALTIĆ, 2000; BULL, 2000; POSLUSZNY *et al.*, 2007). Such opportunistic feeding habits are indicated by the enlargement of their occlusal tooth surfaces, especially in the case of M<sub>1</sub> (KALLAY, 1977). Previously, dental variations in stone martens were studied by WOLSAN *et al.* (1985) in Poland who found missing P<sup>1</sup> in one animal and one or both P<sub>1</sub> missing in eight out of 43 skulls. No supernumerary teeth were recorded. A higher frequency of missing teeth in stone martens, in 52 out of 106 skulls examined, was reported by KRYŠTUFEK & POLAK (1996) for Slovenia. Beside that, KRYŠTUFEK & POLAK (1996) recorded 13 specimens with evident traumatic injuries to the teeth, 3 specimens with abnormal dental wear and 4 skulls with traumatic injuries that affected subsequent tooth development. There were also several well documented cases of dental caries and severe periodontal disease in stone martens presented by DIERKS (2001). More recently, an extensive study covering a sample of 337 macerated stone marten skulls from Germany was performed by HEDDERGOTT (2006), combining craniometric and dental pathology analysis.

Study of the dental characteristics variations in tooth size, shape, and number, as well as of dental pathology, is a valuable research tool since mammalian teeth provide insights into ontogeny, life experience, feeding habits, history, etc. (ALT, 1999). They are also important from the point of ecotoxicology (as bioindicators) and the

occurrence of certain diseases that influence the development of dental hard tissues (DUBIELZIG, 1979; BITTEGEKO *et al.*, 1995). The aim of this study was to document and analyze variations in size, number, shape and pathology of teeth of stone martens from the first sample of the Croatian island population.

## MATERIALS AND METHODS

In total, 27 skulls of free-ranging stone martens (*Martes foina* Erx., 1777) from the Mediterranean island habitat in Croatia were examined macroscopically for dental abnormalities. The skulls were deposited in the Croatian Natural History Museum (CNHM) in Zagreb, Croatia. The skulls were defleshed and cleaned according to standard skull preparation methods. To each skull an inventory number was assigned in the CNHM Mammal Collection: samples originating from the island of Cres (HPM6550, 6551, 6554-6568, MB33); island of Hvar (HPM6549, 6569-6575) and island of Rab (HPM6552). Beside macroscopic inspection of the teeth we used a dental (periodontal) probe to analyze and measure gum pockets (retrospectively) and horizontal bone loss. In the case of tooth absence, the alveolar bone was thoroughly examined to determine whether the respective tooth had been lost during life or post mortem. Only tooth anomalies that developed during the life of the respective animal were recorded. No radiographic analyses were used in this study. Due to the invasiveness of relatively accurate age estimation methods we did not attempt to determine the age in specimens. Skulls were categorized into juveniles and adults according to the degree of tooth wear and dental replacement.

## RESULTS AND DISCUSSION

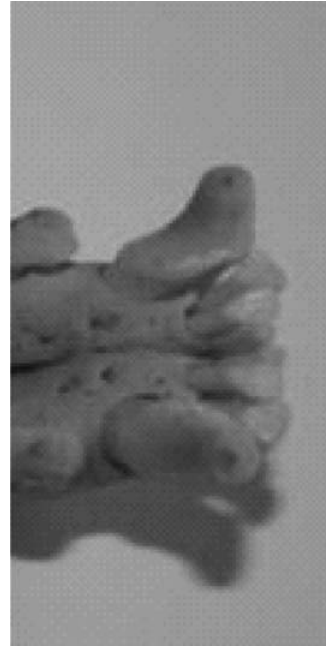
The results obtained in this study with the exception of missing teeth are summarized in Tab. 1. The observed irregular arrangement of incisors (Fig. 1) in 25.9 % of examined skulls is a common finding in mustelids (MILES & GRIGSON, 1990). According to MILES & GRIGSON (1990) such irregularities are so common in certain taxa that it must be regarded as normal. Frequently, crowding of the incisors and consequent irregular arrangement is related to crowding of the premolars.

The absence and reduction in size of the first lower premolar could reflect the evolutionary trend toward a reduction in tooth number in carnivores (BENSLEY, 1903; SAVAGE, 1977). The reduction in number of premolars in this genus has already been mentioned by PEYER (1968). Such a reduction of tooth number results in shortening of the jaws which in combination with changes in the temporo-mandibular joint leads to increased bite power. However, as well as in carnivores, different missing teeth have been documented in various species (MILES & GRIGSON, 1990). In general, it is more likely to occur in teeth of low functional value (HALL, 1940) – a relation to first premolars in stone martens. In our small sample study we observed on 6 skulls bilateral and on 5 skulls unilateral absence of  $P_1$ . The unilateral absence of  $P_1$  was observed only on the right side of the mandibles (Fig. 2). In contrast,  $P^1$  was found to be missing in only two cases, one on the left and other on the right side of the maxilla. These findings supports HALL's (1940) conclusion since the

**Tab. 1.** Distribution of different dental lesions in 27 analyzed stone marten skulls.

Tooth Lesions	Left													Right							
	M <sup>2</sup>	M <sub>1</sub>	P <sup>4</sup>	P <sup>3</sup>	P <sup>2</sup>	P <sup>1</sup>	C	I <sup>3</sup>	I <sup>2</sup>	I <sup>1</sup>	I <sub>1</sub>	I <sub>2</sub>	I <sub>3</sub>	C	P <sup>1</sup>	P <sub>2</sub>	P <sub>3</sub>	P <sub>4</sub>	M <sub>1</sub>	M <sub>2</sub>	
Fracture																					
	U						2														
Pronounced wear																					
	L						1														
Dental calculus																					
	U	1	1	1	1								1							2	
Periodontitis																					
	L	2	1	1	1	5									5	1	1	1	1	1	1
Tooth	M <sub>2</sub>	M <sub>1</sub>	P <sub>4</sub>	P <sub>3</sub>	P <sub>2</sub>	P <sub>1</sub>	C	I <sub>3</sub>	I <sub>2</sub>	I <sub>1</sub>	I <sub>1</sub>	I <sub>2</sub>	I <sub>3</sub>	C	P <sub>1</sub>	P <sub>2</sub>	P <sub>3</sub>	P <sub>4</sub>	M <sub>1</sub>	M <sub>2</sub>	

Legend: U – upper jaw (maxilla); L – lower jaw (mandible).



**Fig. 1.** Irregular arrangement of lower incisors in stone marten

first premolars are the smallest teeth in mustelids and are prone to rapid wear (as discussed later). The alveolar bone in the area of missing teeth was examined carefully and in the case of a visible bone remodeling or a closed alveolar opening an intravital tooth loss was deduced. However, without X-ray analysis it is difficult to state whether there were really missing or just unerupted teeth. Furthermore, we cannot definitely conclude whether the respective tooth was lost early in life (meaning that traces of bone remodeling are rather scarce) or if tooth absence occurred as a congenital anomaly. Similar problems were recognized by other authors (KRYŠTUFEK & POLAK, 1996; VERSTRAETE *et al.*, 1996).

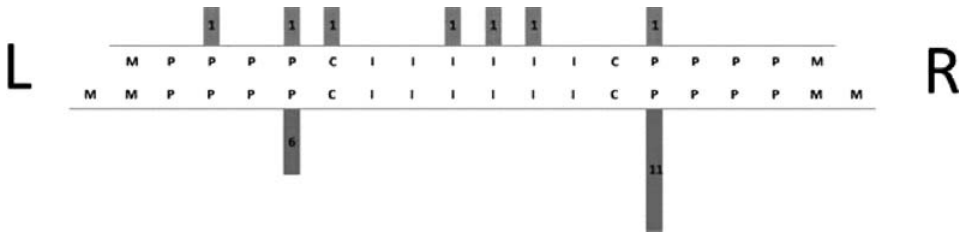


Fig. 2. Distribution of teeth lost during the lifetime (including non-erupted).

Presence of supernumerary teeth, i.e. occurrence of at least one tooth that is additional to the normal series is a rare finding in martens and is associated with consequent overcrowding and rotation of teeth (not in a case when the extra tooth is completely out of the teeth line). This overcrowding must be differentiated from overcrowding due to evolutionary loss of the tooth place. In our study only one skull had a supernumerary premolar tooth on the right side of the maxilla, placed between P<sup>2</sup> and P<sup>3</sup>. The erupted supplemental premolar caused overcrowding and consequent slight rotation of both P<sup>2</sup> and P<sup>3</sup> (Fig. 3). In total, rotation was observed on 6 premolars (two lower and four upper) (Fig. 4).

The frequency and distribution of other dental lesions in the analyzed skulls are presented in Tab. 1. Complicated crown fractures, especially of canines, are a common finding in carnivores. The predisposition to fracture is influenced with killing and feeding behavior, age of the animal and tooth strength. Furthermore, increased feeding pressure due to lack of feed resources or increased competition can result in a switch to alternative feed resources and with time lead to increased predisposition to injury (VAN VALKENBURGH & RUFF, 1987; VAN VALKENBURGH, 1988; VAN

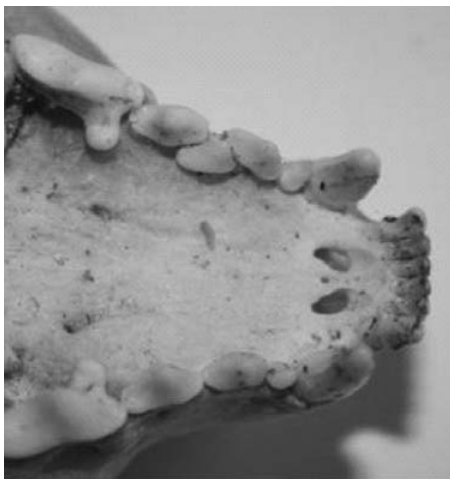


Fig. 3. Supernumerary premolar tooth. Note the slight rotation of P<sup>2</sup> and P<sup>3</sup>.

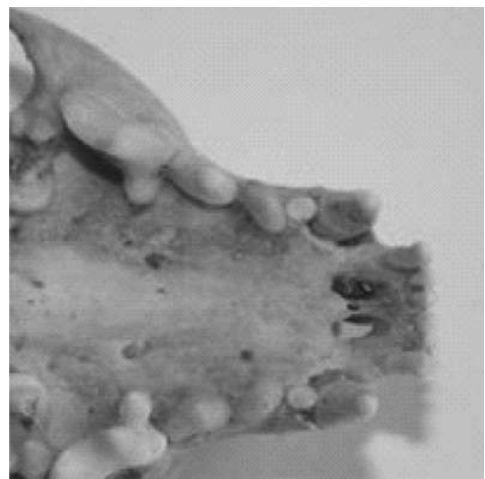
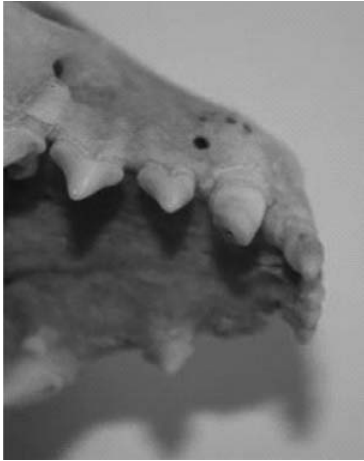


Fig. 4. Rotation of the left and right P<sup>2</sup>.



**Fig. 5.** Complicated fracture of the right upper canine with exposed pulp chamber. Note the porous bone over the canine root. On the other side of the maxilla, bone remodeling is visible over the C, P<sup>1</sup> and P<sup>3</sup> alveolus.

VALKENBURGH & HERTEL, 1993; LEONARD *et al.*, 2007). According to VAN VALKENBURGH (1988) there is 25 % likelihood that a carnivore will break some of its teeth during its lifetime. In the analysis of tooth fractures among recent and Pleistocene carnivores VAN VALKENBURGH (2009) reports 23 to 67 % tooth breakage in different mustelid species, weasels (*Mustela nivalis* L., 1766) and stoats (*Mustela erminea* L., 1758). According to VAN VALKENBURGH (2009) there was a 46 % (100 animals examined) incidence of tooth breakage in weasels and 67 % (72 examined) in stoats. The life habits of the stone marten as a primarily carnivorous species, combined with its aggressive behavior, results in high predisposition to tooth fracture. As expected, traumatic impacts to the teeth are more common findings in older animals. KRYŠTUFEK & POLAK (1996) reported 13.7 % incidence of dental injuries in stone marten skulls (out of 95 examined). According to their observations the most frequently affected teeth were the incisors and lower premolars. Interestingly, canines and

carnassials, which are teeth with high risk of fracture in carnivores, were rarely damaged. This is not in accordance with our observations, where we found complicated crown fractures of one canine in two animals (1 × left C<sup>1</sup>; 1 × right C<sup>1</sup>) and in one animal of all four canines. Similarly to our observations, HEDDERGOTT (2006) and VAN VALKENBURGH (2009) have also reported that canines are the most frequently fractured teeth in mustelids. Furthermore we noted traumatic losses of three incisors (two animals) and of one P<sup>3</sup>. These were not included in Tab. 1, as no specific line of events could be determined retrospectively. The sequelae of tooth fractures vary in respect to the type of fracture and the tooth affected. Enamel fractures and fractures with intact pulp are clinically unimportant (VERSTRAETE *et al.*, 1996) and do not pose threats to the animal's life. On the other hand, opening of the pulp chamber in teeth of limited growth in the majority of cases will result in endodontic disease and pulp necrosis. If the most important teeth of carnivores, i.e. canines and carnassials, are affected and damaged, it will reduce their ability to kill prey, slice meat or crush bone, but will also impair the social interaction, since canines are frequently used as display organs (MILES & GRIGSON, 1990; LAZAR *et al.*, 2009).

Opening of the pulp chamber, its infection and subsequent development of inflammation and its spread to the periodontal area (gingiva, desmodont, root cementum and alveolar bone) can result in destruction of the periodontal ligament. The usual signs of periodontitis on macerated skulls are horizontal bone loss (and vertical bone loss if disease progresses), cribriform lesions of the bone, abscess formation and different levels of bone destruction, or just simply porous alveolar bone and a distally located draining hole. In this study we found only one case of porous

bone located just above the broken right maxillar canine (Fig. 5). Further, as well as by injury and consequent inflammation, periodontitis can also be caused through the formation of dental calculus. Stone martens as opportunistic feeders can occasionally develop dental plaque. In our case only one  $I_3$  with dental plaque was noted. The relatively low incidence of tooth fractures and almost complete absence of periodontal diseases can be attributed to the fact that the majority of examined skulls originated from young animals. Pronounced tooth wear was observed in 25.9 % (7 skulls) of the examined skulls. KRYŠTUFEK & POLAK (1996) found 3 (out of 106) skulls with abnormal dental wear. The regularly used terms »attrition« and »abrasion« are not quite applicable in terms of carnivore dentition since secodont teeth partially or almost completely lack occlusal contact. The level of occlusion differs among carnivore families, being the least expressed in felids (KALLAY, 1974). Well-developed masticatory surfaces of the marten's molars indicate some chewing possibilities. In this study  $P_1$  were the most frequently worn down, constituting almost half of the mandibular teeth with pronounced wear (10 out of 21). This is in accordance with HALL's (1940) conclusion that  $P_1$  as a small tooth with almost no function is subjected to rapid wear. In his study on 337 marten skulls, HEDDERGOTT (2006) divided cases of abrasion in four degrees, ranging from 0 to 4 (with 4 being the most severe). In maxillar dentition the least affected tooth was right  $P^1$  with recorded abrasion of 11.4% (out of 307 samples; 1<sup>st</sup> degree – 9.1%, 2<sup>nd</sup> degree – 2.3%), while the most affected was left  $P^4$  with recorded abrasion of 47.1% (out of 300 samples; 1<sup>st</sup> – 33.7%, 2<sup>nd</sup> – 11.3%, 3<sup>rd</sup> – 0.7%, 4<sup>th</sup> – 1.4%). In mandibular dentition the least affected tooth was left  $P_1$  with recorded abrasion of 13.5% (out of 311 samples; 1<sup>st</sup> – 8.7%, 2<sup>nd</sup> – 4.8%). The most affected lower tooth was left  $I_1$  with abrasion in 86.4% of examined 302 samples (1<sup>st</sup> – 55.9%, 2<sup>nd</sup> – 30.5%). Most cases of 4<sup>th</sup> degree of abrasion were recorded in lower  $M_1$  (left in 1.6% and right in 1.7% of analyzed samples). According to HEDDERGOTT (2006) wear ratio is influenced by tooth function and is more pronounced in multifunctional teeth ( $P_2$ - $M_1$ ). We have observed increased wear on molars in just two cases plus one skull that exhibited pronounced wear on all premolars and molars.

## ACKNOWLEDGEMENTS

The study was financially supported by the project »Dental Pathology of Wild Mammals«, Croatian Ministry of Science, Education and Sport. The results of this study were partially presented as a poster during the 10<sup>th</sup> Croatian Biological Congress in Osijek, Croatia.

Received April 6, 2010

## REFERENCES

- ALT, K. W., 1999: Spuren in die Vergangenheit – Zähne als Informationsträger. *Quintessenz Team-Journal* **29**, 685–694.
- BALTIĆ, M., 2000: The diet of the stone marten *Martes foina* (Erxleben 1777) on the island of Cres. MSc Thesis. Faculty of Science, University of Zagreb, Zagreb.

- BENSLEY, B. A., 1903: On the evolution of the Australian Marsupialia; with remarks on the relationships of the Marsupials in general. *Transactions of the Linnaean Society of London (Zool.)* **9**, 83–217.
- BITTEGEKO, B., ARNBJERG, J., NKYA, R. & TEVIK, A., 1995: Multiple dental abnormalities following canine distemper infection. *Journal of American Animal Hospital Association* **31**, 42–45.
- BULL, E. L., 2000: Seasonal and Sexual Differences in American Marten Diet in Northeastern Oregon. *Northwest Science* **74**, 186–191.
- DIERKS, K., 2001: Dental caries and periodontitis in macerated skulls demonstrated in badgers (*Meles meles* Linné 1758) and stone martens (*Martes foina* Erxleben 1777). *Wissenschaftliche Mitteilungen aus dem Niederösterreichischen Landesmuseum* **14**, 113–124.
- DUBIELZIG, R. R., 1979: The effect of canine distemper virus on the ameloblastic layer of the developing tooth. *Veterinary Pathology* **16**, 268–270.
- HALL, E. R., 1940: Supernumerary and missing teeth in wild mammals of the orders Insectivora and Carnivora, with some notes on disease. *Journal of Dental Research* **19**, 103–43.
- HEDDGEROTT, M., 2006: Ergebnisse einer Untersuchung zu den Gebisserkrankungen in einer Population des Steinmardes *Martes foina* (Erxleben, 1777) in Zentral Deutschland. Logos Verlag, Berlin.
- JANICKI, Z., SLAVICA, A., KONJEVIĆ, D. & SEVERIN, K., 2007: Zoologija divljači. Zavod za biologiju, patologiju i uzgoj divljači, Veterinarski fakultet Sveučilišta u Zagrebu, Zagreb, pp. 115–118.
- KALLAY, J., 1977: Komparativna odontografija. Izdavački zavod Jugoslavenske akademije, Zagreb.
- KRYŠTUFEK, B. & POLAK, S., 1996: Dental and skull abnormalities in the stone marten *Martes foina* (Erxleben, 1777) from Slovenia. *Small Carnivore Conservation* **14**, 14–18.
- LAZAR, P., KONJEVIĆ, D., KIERDORF, U., NJEMIROVSKIJ, V., ČURLÍK, J. & GRUBEŠIĆ, M., 2009: Traumatic injury to the incisive bones and maxillary dentition in male gray wolf (*Canis lupus* L.) from Slovakia. *European Journal of Wildlife Research* **55**, 85–89.
- LEONARD, J. A., VILA, C., FOX-DOBBS, K., KOCH, P. L., WAYNE, R. K. & VAN VALKENBURGH, B., 2007: Megafaunal extinctions and the disappearance of a specialized wolf ecomorph. *Current Biology* **17**, 1146–1150.
- MILES, A. E. W. & GRIGSON, C., 1990: Colyer's variations and diseases of the teeth of animals, revised edition. Cambridge University Press, Cambridge, UK.
- MITCHELL-JONES, A. J., AMORI, G., BOGDANOWICZ, W., KRYŠTUFEK, B., REIJNDERS P. J. H., SPITZENBERGER, F., STUBBE, M., THISSEN, J. B. M., VOHRALÍK, V. & ZIMA, J., 1999: The atlas of European mammals. Academic Press, London, pp. 160–168.
- PEYER, B., 1968: Comparative Odontology, translated and edited by Rainer Zangerl. The University of Chicago Press, Chicago, USA, pp. 246–247.
- POSŁUSZNY, M., PILOT, M., GOSZCZIŃSKY, J. & GRALAK, B., 2007: Diet of sympatric pine marten (*Martes martes*) and stone marten (*Martes foina*) identified by genotyping of DNA from faeces. *Annales Zoologici Fennici* **44**, 269–284.
- SAVAGE, R. J. G., 1977: Evolution in carnivorous mammals. *Palaeontology* **20**, 237–271.
- VAN VALKENBURGH, B. & RUFF, C. B., 1987: Canine tooth strength and killing behaviour in large carnivores. *Journal of Zoology* **212**, 379–397.
- VAN VALKENBURGH, B., 1988: Incidence of tooth breakage among large, predatory mammals. *American Naturalist* **131**, 291–302.
- VAN VALKENBURGH, B. & HERTEL, F., 1993: Tough times at La Brea: tooth breakage in large carnivores of the late Pleistocene. *Science* **261**, 456–459.
- VAN VALKENBURGH, B., 2009: Costs of carnivory: tooth fractures in Pleistocene and Recent carnivores. *Biological Journal of the Linnean Society* **96**, 68–81.
- VERSTRAETE, F. J. M., VAN AARDE, R. J., NIEUWOUTD, B. A., MAUER, E. & KASS, P. H., 1996: The Dental Pathology of Feral Cats on Marion Island, Part I: Congenital, Developmental and Traumatic Abnormalities. *Journal of Comparative Pathology* **115**, 265–282.
- WOLSAN, M., RUPRECHT, A. L. & BUCHALCZYK, T., 1985: Variation and asymmetry in the dentition of the pine and stone martens (*Martes martes* and *M. foina*) from Poland. *Acta Theriologica* **30**, 79–114.



## S A Ž E T A K

**Varijacije u izgledu, broju i položaju zuba kuna bjelica s otočnih staništa (Hrvatska) – preliminarni rezultati**

D. Konjević, V. Njemirovskij, M. Vuković, A. Slavica, Z. Janicki,  
K. Severin & M. Sindičić

Kuna bjelica (*Martes foina* Erx. 1777) je autohtoni sisavac u Republici Hrvatskoj čiji areal rasprostiranja obuhvaća sva četiri tipa staništa (nizinska, brdska, gorska i mediteranska). U ovom je radu pregledano ukupno 27 lubanja kuna bjelica podrijetlom iz mediteranskih otočnih staništa Republike Hrvatske. Nepravilan raspored donjih sjekutića zamijećen je u 7 jedinki (25.9%). Navedena je pojava toliko česta u kuna da se u pojedinim vrsta smatra redovitim i normalnim nalazom. Nepravilan raspored sjekutića je uglavnom posljedica premalog prostora za smještaj postojećih zuba i često se javlja istodobno i u pretkutnjaka. Obostrani nedostatak  $P_1$  zabilježen je u 6 (22%) odnosno jednostrano u 5 jedinki (18,5)). Nasuprot tomu,  $P^1$  je nedostajao isključivo jednostrano, u dva slučaja (7,4%). Od ostalih zuba, nedostatak  $I^1$  je zabilježen u dva slučaja jednostrano (7,4%), dočim su  $I^2$ ,  $C^1$  i  $P^3$  nedostajali po jednom (3,7%). U svakom slučaju potpunog nedostatka zuba, alveolarna kost je temeljito pregledana na znakove da li je zub izgubljen prije ili nakon uginuća. Nedostatak  $P_1$ , njegova veličina i sklonost trošenju dovode se u vezu s trendom smanjivanja broja zubi i daljnje specijalizacije u mesojeda. Prekobrojni zub je uočen samo u jednom slučaju, i to kao desni  $P^2$ , praćen zakretanjem dotičnog zuba i  $P^3$ , kao posljedice prekobrojnosti zuba. Zakretanje zuba je zabilježeno još u slučaju 6 pretkutnjaka (dva donja i četiri gornja). Komplikirani prijelomi zuba zamijećeni su na tri lubanje (11%). Prijelomi su nađeni isključivo na očnjacima. Nađeno je u suglasju s većinom drugih istraživanja na kunama i drugim mesojedima s obzirom da su očnjaci i derači najčešće izloženi agresivnim radnjama. Poroznost pripadajuće alveolarne kosti je primijećena samo iznad jednog prelomljenog očnjaka. Konačno, izraženo trošenje zuba utvrđeno je na 7 lubanja (25,9%). Pri tome treba naglasiti kako je dobar dio navedenog trošenja utvrđen na prvom pretkutnjaku donje čeljusti što je u suglasju s prethodnim opažanjima kako je  $P_1$  zub male funkcije s vrlo naglašenom sklonošću trošenju. Uočena kongenitalna hipodoncija je relativno čest nalaz u svih pripadnika skupine mesojeda, odražavajući time težnju ka smanjenju broja zuba. Relativno rijedak nalaz prijeloma zuba i gotovo potpuni nedostatak periodontitisa može se pripisati činjenici da je većina prikupljenih lubanja podrijetlom od mladih životinja.