

Osteolytic Skull Metastasis with Dural Involvement from a Papillary Thyroid Carcinoma

Karlo Houra¹, Majda Vučić², Hrvoje Čupić², Damir Kovač³ and Vatroslav Čerina³

¹ »Sv. Katarina« Hospital, Zabok, Croatia

² University of Zagreb, »Sestre milosrdnice« University Hospital Center, »Ljudevit Jurak« University Department of Pathology, Zagreb, Croatia

³ University of Zagreb, »Sestre milosrdnice« University Hospital Center, Department of Neurosurgery, Zagreb, Croatia

ABSTRACT

Skull metastatic tumors are relatively rare medical entities and originate most often from the lungs, breast or prostate. We report a case of a 76-year-old woman who presented with a bulging, well-circumscribed mass on the right side of the forehead. Neuroimaging of the cranium detected an osteolytic lesion measuring 7 cm in the largest diameter while propagating outwards and intracranially. A thorough medical history revealed that patient had undergone surgery for invasive breast ductal carcinoma and also for a well-differentiated thyroid carcinoma 13 years ago. Considering patients medical history metastatic breast carcinoma was suspected. After a frontal craniotomy the tumour tissue was totally resected. Histological examination revealed metastatic papillary carcinoma characterized by ground-glass nuclei with intranuclear pseudo inclusion and nuclear grooves. We report clinical and neuroradiological features of this uncommon lesion and discussed the differential diagnosis of skull osteolytic lesion together with the treatment management.

Key words: distant metastasis, osteolytic lesion, papillary thyroid carcinoma, skull

Introduction

Metastatic tumours to the skull are relatively rare and originate most often from the lung, breast or prostate¹. Most metastatic skull lesions are asymptomatic. Skull and dural metastases from a well-differentiated thyroid carcinoma are very uncommon²⁻⁵. Papillary thyroid carcinoma usually remains intrathyroidal and tends to metastasize only to the regional lymph nodes⁶. We describe a case of skull metastasis with a dural involvement from a papillary thyroid carcinoma 13 years after thyroidectomy and discuss the differential diagnosis of skull osteolytic lesion together with the treatment management.

Case Report

A 76-year-old female was admitted at our Department of Neurosurgery due to the growing tender mass on the right side of her forehead. The patient complained on headache and confusion together with sleeping disturbance. A thorough medical history revealed that she had

undergone the right-sided mastectomy and a lymphadenectomy due to the invasive ductal carcinoma in the stage T2N0M0 13 years ago. She had also undergone a surgery for a well-differentiated thyroid carcinoma when left total lobectomy and partial right lobectomy was performed. The diagnosis was papillary thyroid carcinoma stage T2 without extension beyond the thyroid gland. Ever since she is under a continuous surgical control including regularly chest X-rays and abdominal ultrasound that revealed no metastatic disease. Endocrinological control including thyroid function tests was within normal limits. Repeated fine needle cytological aspiration of the residual thyroid gland was negative for malignant cells. Regional cervical lymph nodes were also clear with no signs of local recurrence.

In the last year the patient noticed a gradually growing, soft and well-circumscribed mass with no neurological deficits what so ever. A local examination revealed a palpatory, subcutaneous, non-pulsating, soft, right frontal egzophytic swelling. Haematological, biochemical tests

and chest X-ray did not reveal any abnormal findings. The patient's neurological examination did not disclose any abnormal findings. A plain X-ray showed an elliptical area lucency of 8 cm in diameter in the right frontal bone. A computed tomography (CT) scan revealed an irregular bone defect measuring 7 cm in largest diameter involving both the inner and the outer table of the skull in the right frontal region together with multilobulated egzophytic lesion that was propagating mostly outwards but also intracranially compressing the adjacent dura and brain (Figure 1). Considering patients medical history a metastatic brain carcinoma was suspected. After a complete neuroradiological evaluation, the patient underwent surgery.

A semicircular incision of the skin was made and the galea was differentiated from the coetaneous flap. It was infiltrated by the brown multilobulated, soft, vascular tumour tissue (Figure 2). The tumour tissue was then resected at the bone level after which we have performed a right-sided frontal craniotomy, encompassing the bone defect. After elevating the eroded bone flap, it was clear that the tumour had started to infiltrate the dura. No infiltration under the dura was evident upon its opening. At the end a cranioplasty with Palacos was performed. Postoperative recovery was uneventful.

Histological hematoxylin-eosin (H&E) slides revealed a tumour lesion composed of a follicular growth pattern containing colloid and oedematous papillary structures with the fibrovascular core covered by the epithelium with characteristic nuclear features that include enlarged, oval shaped and overlapping nuclei with typically ground glass appearance (Figure 3). The tumour had infiltrated between the bone trabecula with focally dural infiltration. Additional immunostaining with anti-thyroglobulin antibody stained most tumour cells. Based on these findings, a definitive diagnosis of a metastasis from the papillary carcinoma of the thyroid was made.

A total body radioiodine (I-131) scan didn't detect activity. A follow-up cranial CT scan showed no tumour recurrence. Ten months later patient's general condition remained well.



Fig. 2. Surgically removed specimen; the brown multilobulated, softly tumour tissue mass.

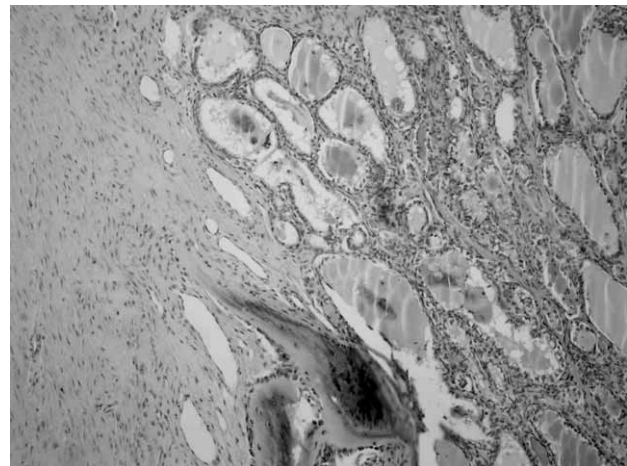


Fig. 3. Metastatic lesion between bone trabecula composed of follicular growth pattern containing colloid and lined by epithelium with characteristic nuclear features with typically ground glass appearance (H&E x200).

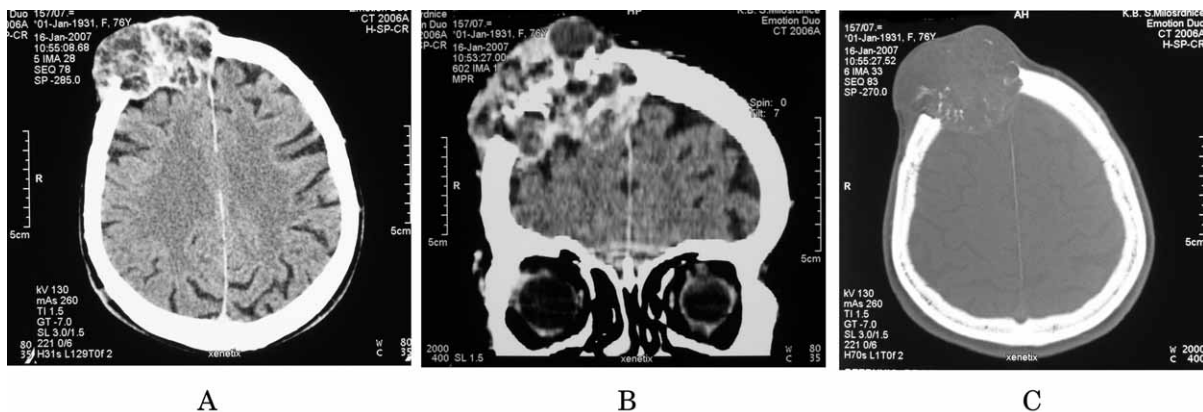


Fig. 1. Cranial CT scan; transversal (A), coronal sections (B) and bone window (C) irregular bone defect involving both the inner and outer table of the skull in the right frontal region.

Discussion

Skull metastases are found at 5–6% of patients with advanced systemic cancer. Clinically they cause local swelling that is usually painless and rarely lead to neurological dysfunction¹. Dural involvement developed in 15% of these cases by direct extension from skull metastasis, usually produces neurological deficit and sometimes subdural haematomas^{4,7,8}. Metastatic lesions of the skull are result of haematogenous seeding with tumour emboli that occurs initially in the red marrow⁵. Skull metastases spread most often from the lungs, breast, prostate or a renal cell carcinoma. Breast cancer is associated with the highest rate of the metastatic skull lesion^{1,9}. Bone metastases may be osteolytic, sclerotic or mixed on radiographs. Osteolytic metastases are encountered most frequently, especially in the breast and a lung carcinoma.

Papillary carcinoma of the thyroid generally carries a good prognosis. It usually remains intrathyroidal and tends to metastasise locally to regional lymph nodes². Distant spread may occur to the lungs or bones but exceptionally to the skull. Bone metastases are usually developed after the appearance of lung metastases. Typically multiple lesions are present within the 10 years after surgery¹⁰. Incidence of bone metastases from a well-differentiated thyroid papillary carcinoma was 0.4–1%, and from follicular thyroid carcinoma was 6–8%^{2,8,11}. The most common site for bone metastases from well-differentiated thyroid carcinoma is the spine. The most frequent histopathological presentation in the case of skull metastases was also follicular thyroid carcinoma¹². There are several reports of skull metastasis from thyroid papillary carcinoma^{3,5,7,13,14}. Even when they spread, which is extremely rare, they usually metastasize in the brain parenchyma and not in the skull¹⁵. Such a cranial metastatic lesion can become threatening in a more aggressive manner, particularly in the older patients. The preferred treatment algorithm for most primary thyroid carcinomas is near-total thyroidectomy followed by post-operative 131-I ablation and in the absence of 131-I uptake, external beam radiation therapy is preferred¹⁵. Patients should also be on chronic TSH suppression to control disease progression.

Cranial osteolytic metastatic lesions can clinically and radiologically mimic osteocartilaginous skull tumours or tumour-like lesions. The differential diagnosis includes a chondroma that radiographically appears as a lytic lesion mostly at the base of the skull with fairly sharp margins. CT reveals well marginated bone destruction and an associated homogenous, isodense and lobulated soft tissue mass with interspersed calcification. Chondrosarcomas develop usually in adults, as a malignant transformation

in a benign chondroma. They grow for a long period of time and produce the pain and a deformity. CT reveals an irregular destructive process with a homogenous, hyperdense, and enhancing soft tissue mass¹⁰. In a case of solitary plasmocytomas and multiple myeloma skull x-rays show solitary lytic lesion or multiple punched areas of bone destruction¹⁶. Other rare tumours, such as, reticulum cell sarcoma, angiosarcoma, malignant fibrous histiocytoma can also be presented as an osteolytic bone lesions¹⁷. Osteomyelitic changes appear radiologically long after the onset of clinical signs and symptoms. Multiple nodular lucent areas appear in the outer table or in the diploe. Later they condense into large defects with scalp oedema (Pott's puffy tumour)^{10,16}. As radiological findings are not specific, biopsy with pathohistology may be needed to confirm the diagnosis of such osteolytic lesions.

Conclusion

Solitary metastasis of differentiated thyroid cancer to the skull is extremely rare. It is of no surprise then, that the differential diagnosis for skull tumours does not customarily include these lesions, but a strong argument can be made that it should, regardless of the patient's age and especially in patients with previous history of thyroid carcinoma. In our case report a solitary, lytic skull lesion, considering the patients medical history and a statistical probability, was suspected to be a metastasis of a breast cancer. This was not the case however. The patient presented with a skull metastasis of a well-differentiated thyroid papillary carcinoma that was totally surgically removed 13 years ago without local progression or lung involvement. The metastases of thyroid tumours are most frequent from the follicular carcinomas, while papillary carcinoma tends to metastasize in the regional nodes or in the lung. Bone metastasis is usually seen after the appearance of lung metastasis within the first 10 years after surgery.

If possible, a histologic tissue diagnosis should always be attempted, followed by total thyroidectomy, 131-I, or external beam radiation and chronic TSH suppression. Surgical resection of the metastasis is recommended as a curative option for increasing patient survival and also to maximize the effect of subsequent radioiodine treatment therapy. Patients with dural infiltration and related neurologic deficit should be treated surgically to relieve symptoms and therefore improve the quality of life. Moreover in the case of solitary metastasis without additional metastases radical extirpation of bone metastasis was associated with improved survival.

REFERENCES

1. STARK AM, EICHMANN T, MEHDORN HM, Surg Neurol, 60 (2003) 219. — 2. AGUIAR PH, AGNER C, TAVARES FR, YAMAGUSCHI N, Neurosurgery, 49 (2001) 1008. — 3. FENG D, RHATIGAN R, SHUJA S, WOLFSON D, MAKARY R, KOCH K, MASOOD S, Diagn Cytopathol, 37 (2009) 522. — 4. DO MY, RHEE Y, KIM DJ, KIM CS, NAM KH, AHN CW, CHA BS, KIM KR, LEE HC, PARK CS, LIM SK, Endocr J, 52 (2005) 701. — 5. SISSON JC, DEWARAJA YK, WIZAUER EJ, GIORDANO TJ, AVRAM AM, Thyroid, 19 (2009) 297. — 6. KUSUNOKI T, URANO K,

- SAITO K, MURATA K, Thyroid, 13 (2003) 889. — 7. PORTOCARRERO-ORTIZ L, GARCIA-LOPEZ R, ROMERO-VARGAS S, PADILLA JA, GÓMEZ-AMADOR JL, SALINAS-LARA C, TENA-SUCK ML, GONZÁLEZ AS, J Neurooncol, 95 (2009) 281. — 8. OZDEMIR N, SENOGLU M, ACAR UD, CANDA MS, J Neurosurg Sci, 47 (2004) 167. — 9. TSENG SH, LIAO CC, LIN SM, CHEN Y, SHUN CT, Acta Neurol Scand, 108 (2003) 43. — 10. BERTONI F, BACCHINI P, Eur J Radiol, 27 (1998) 74. — 11. YAN B, LIU DG, LÚ HL, ZHANG QH, Chin Med J (Engl), 123 (2010) 2750. — 12. MATSUNO A, KATAKAMI H, OKAZAKI R, YAMADA S, SAKI M, NAKAGUCHI H, YAMADA SM, HOYA K, MURAKAMI M, YAMAZAKI K, ISHIDA Y, IWASAKI H, KUYAMA J, KAKUDO K, Neurol Med Chir (Tokyo), 50 (2010) 421. — 13. HASHIBA T, MARUNO M, FUJIMOTO Y, SUZUKI T, WADA K, ISAKA T, IZUMOTO S, YOSHIMINE T, Brain Tumor Pathol, 23 (2006) 97. — 14. MIYAWAKI S, YAMAZAKI R, HARADA T, TAKANASHI S, NAGASHIMA T, NAKAGUCHI H, OKAZAKI R, YAMAZAKI K, ISHIDA Y, MATSUNO A, J Clin Neurosci, 14 (2007) 481. — 15. MYDLARZ WK, WU J, AYGUN N, OLIVI A, CAREY JP, WESTRA WH, TUFANO RP, Laryngoscope, 117 (2007) 1146. — 16. KUZELYI K, DURU S, CEYLAN S, AKTURK F, Neurosurg Rev 18 (1995) 39. — 17. ASAHI T, KURIMOTO M, KAWAGUCHI M, YAMAMOTO N, SATO S, ENDO S, J Clin Neurosci, 9 (2002) 704.

K. Houra

*Krajiška 13, 10000 Zagreb, Croatia
e-mail: khoura1912@gmail.com*

OSTEOLITIČKA METASTAZA LUBANJE PAPILARNOG KARCINOMA ŠTITNJAČE S DURALNOM PROPAGACIJOM

S A Ž E T A K

Metastatski tumori lubanje relativno su rijetki medicinski entiteti te se najčešće javljaju kod karcinoma pluća, dojke i prostate. U ovome smo radu prezentirali slučaj sedamdesetšestogodišnje bolesnice koja je u našu kliniku došla s jasno ograničenim izbočenjem na desnoj strani čela. Neuroradiološkim slikanjem glave našli smo osteolitičku leziju veličine 7 cm u najširem promjeru koja se propagirala intrakranijalno ali i ekstrakranijalno. Uzimanjem temeljite anamneze saznali smo da je bolesnica pred dvanaest godina operirala invazivni duktalni karcinom dojke kao i dobro diferencirani karcinom štitnjače. Uzimajući u obzir anamnezu postavili smo sumnju na metastazu karcinoma dojke. Nakon frontalne kraniotomije tumor smo u potpunosti odstranili. Patohistološkom je analizom ustvrđeno da se radi o metastazi papilarnog karcinoma štitnjače čije stanice karakteriziraju svijetle jezgre s intranuklearnim pseudoinkluzijama te pregradama. U radu smo stoga prikazali cjelovitu kliničku prezentaciju bolesti, neuroradiološke karakteristike ovog netipičnog procesa, obradili smo diferencijalne dijagnoze drugih osteolitičkih lezija lubanje te moguće načine liječenja.