

Aggressive Multifocal Form of Epithelioid Hemangioendothelioma – Case Report

Antica Duletić-Načinović¹, Dragana Grohovac¹, Renata Dobrila-Dintinjana²,
Nada Brnčić³ and Nives Jonjić⁴

¹ Department of Hematology, Internal Medicine Clinic, Rijeka University Hospital Center, Rijeka, Croatia

² Clinic for Radiotherapy and Oncology, Rijeka University Hospital Center, Rijeka, Croatia

³ Clinic for Infectious Diseases, Rijeka University Hospital Center, Rijeka, Croatia

⁴ Department of Pathology, University of Rijeka, School of Medicine, Rijeka, Croatia

ABSTRACT

Epithelioid hemangioendothelioma (EHE) is a rare tumor of the vascular origin. It was first described in its pulmonary form by Dail and Leibow in 1975. and named »intravascular bronchioalveolar tumor« (IVBAT). Since then, reports of occurrences of the tumor have been made for number of locations, but most often tumor can be found in soft tissues, liver, lungs, bone and skin. It is considered to be a low or borderline malignant tumor with, usually, slow progression, but aggressive forms have been described. We here report a case of a 46-year old female patient with multifocal malignant tumor spreading to lungs, liver, spleen and with synchronous involvement of lumbal vertebrae, iliac bones and central nervous system dissemination. To the best of the authors knowledge, no case of malignant EHE with multiorgan involvement of this proportions and synchronous central nervous system and bone involvement in one patient has been reported to this date in English-speaking literature.

Key words: epithelioid hemangioendothelioma, malignant tumor, metastatic spread

Introduction

Epithelioid hemangioendothelioma is a rare vascular neoplasm of uncertain malignant potential. It was first described in its pulmonary form by Dail and Leibow in 1975. Due to its characteristic appearance and propensity to invade pulmonary blood vessels and small airways authors named it »intravascular bronchioalveolar tumor« (IVBAT) considering it to be an aggressive form of bronchioalveolar carcinoma¹. Further immunohistochemistry and electron microscopy studies proved IVBAT to be of vascular endothelial origin, therefore Weiss and Enzinger renaming the tumor epithelioid hemangioendothelioma in 1982².

Due to low incidence and low diagnosis rate there is, in recent years, constantly growing knowledge of possible causes, pathophysiological pathways that lead to the tumorigenesis and disease development along with knowledge of biological nature of the tumor. There is till an unmet need for randomised clinical trials that would help elucidate the clinical questions on the effective treatment procedures that would increase the progression free survival or may offer a possibility of cure to the patients.

Case Report

A 46-year old female patient was referred due to her complaints of sharp, colic-like pain in her upper abdomen and occasional diarrhea in April 2004. Patient also complained of pain in her lumbar spine that radiated to her sacrum. That symptom existed for 5 months but was greatly intensified in two months ahead of admission. She also stated she felt fatigue and lethargy for the last 5 months with frequent urinary infections and subfebrile temperatures of up to 37.6°C. She had lost 7 kilograms during one year before admission. In patient history she revealed that 17 years ago she was evaluated in hospital because of radiographic finding of lung changes for which thoracotomy was done and biopsy specimen taken. According to the patient, a rare form of semi-malignant process was diagnosed for which she received no therapy and had no follow up. Other patient's medical history was unremarkable.

Initial laboratory findings revealed sideropenic anemia and elevated erythrocyte sedimentation rate of 100. Other laboratory unremarkable. Using esophagogastroduodenoscopy a diagnosis of chronic gastritis with positive

H. pylori test and acute bulbitis was made so the patient was introduced to the triple therapy (pantoprazolum, amoxicilin i metronidazolum) for eradication of *H. pylori*. Colonoscopy was performed and results were satisfactory, all stool exams for bacteria and parasites negative. Tumor markers (CEA, CA 19-9, AFP, CA 125, CA 15-3) also came out negative. As a result of therapy, abdominal pain subsided, but lumbar pain remained, so the medical workup continued. Chest radiography revealed prominent interstitial pattern close to the base of the lungs with calcified tuberculous sequelae infraclavicularly. Computed tomography (CT) of the thorax showed multiple bilateral nodular lesions in the lung parenchyma measuring less than 15 millimeters in diameter (Figure 1a). Abdominal CT showed an ill-defined hypodense lesion in the upper pole of the spleen measuring 20 millimeters in diameter along with two smaller lesions of the equal presentation in the middle pole, both 10 millimeters in diameter (Figure 1b). A 10 millimeter calcified lesion was revealed in the left lobe of the liver. Abdominal CT also detected well vascularized soft-tissue mass measuring 30x15 millimeter destructing the bone structure of both L2 and L3 vertebrae (Figure 1c). Abdominal magnetic resonance (MRI) confirmed CT findings as it was expected, but it revealed an additional lesion 2 millimeters in diameter located subcapsular in left liver lobe

not seen on CT. MRI of the lumbar spine was performed to evaluate vertebral dissemination. Hyperintense signal was revealed within the L2, L3, L5, and S2 vertebrae along with both iliac bones (Figure 1d).

Patient was transferred to neurosurgery where vertebrolysis was performed and biopsy specimen of the disease-altered bone was obtained. Hystologic evaluation revealed existence of round, polygonal, and in parts of the specimen spindle shaped cells, arranged both in cords and nests that showed striking atypia. Abundant eosinophilic cytoplasm contained intracytoplasmic lumina occasionally occupied by erythrocytes. Immunostains revealed diffuse positivity for CD31, CD34 and vimentin with negativity for keratins. Diagnosis of the EHE was therefore made (Figure 2). During her stay in clinic, patient complained on headaches and forgetfulness. MRI of the brain disclosed two metastatic deposits in the left cerebral hemisphere. One was located frontoparietally measuring 16x13 millimeters, accompanied with extensive perifocal edema and mass effect on adjacent structures, including ventricular system, and the other nodule, located temporoposteriorly was only 4–5 millimeters large (Figure 3).

Chemotherapy regimen with carboplatin and etoposide with addition of interferon α -2a was started, only to

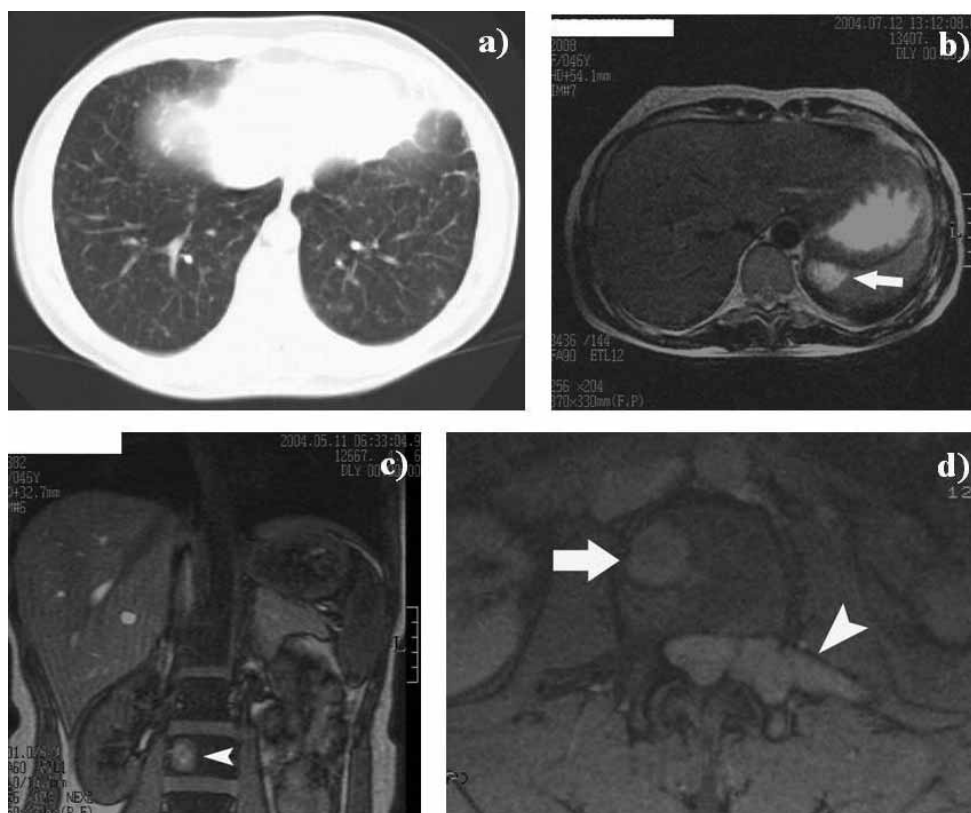


Fig. 1. a) Computed tomography scan of the chest shows multiple bilateral nodules of varying sizes; b) Abdominal MRI: axial T2-weighted image demonstrates focal splenic lesion with high signal intensity (arrow); c) Abdominal MRI: coronal T2-weighted image (gradient-echo) of the abdomen delineates area of high signal intensity in the body of L3 vertebrae (arrowhead); d) Axial T2-weighted image (gradient-echo) of the L3 vertebrae reveals hyperintense lesions in the right part of the body (arrow) and left articular and transverse process (arrowhead).

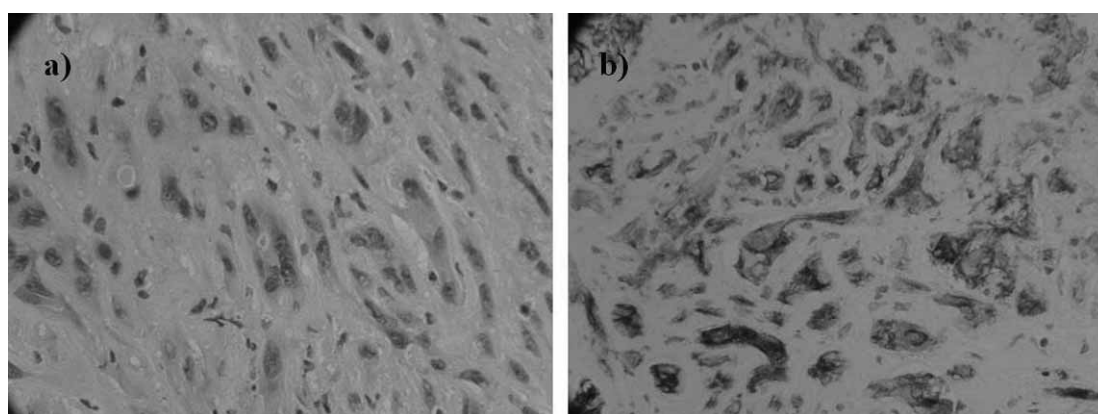


Fig. 2. a) Infiltration of epithelioid haemangioendothelioma in lumbar vertebra, b) Histologic feature with typical strand or cord-like pattern, and intracytoplasmic lumina (arrow). (B) Atypical tumor cells positive for CD34.

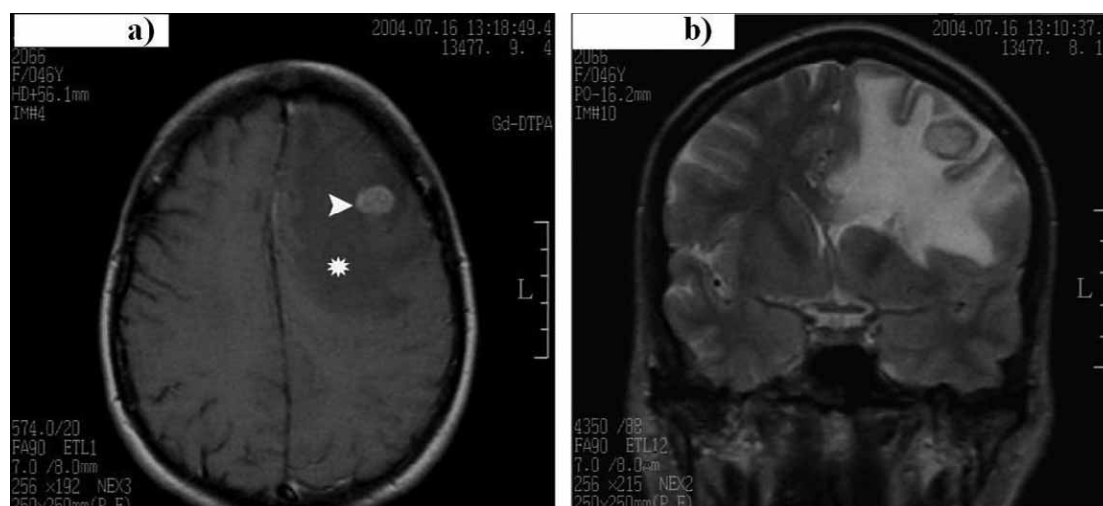


Fig. 3. a) Brain MRI: gadolinium-enhanced T1-weighted axial image of the brain shows enhancing nodular frontoparietal lesion (arrowhead) with associated hypointense perifocal edema (asterisk); b) Coronal T2 weighted image demonstrates round lesion with intermediate signal intensity surrounded by a significant amount of hyperintense perifocal edema and mass effect to the ventricular system.

establish continuous disease progression through reevaluation of the disease six weeks later. Repeated brain MRI after 2 months displayed progression of the disease detecting new lesions. Abdominal CT 5 months after showed disease progression – spleen nodules enlargement with appearance of new lesions. Between the stomach, pancreatic tail and spleen a conglomerate of enlarged lymphatic nodes appeared, as well as a new mass adjacent to the pancreas measuring 5 centimeters in diameter that was indentified as a metastasis. Patient's clinical condition rapidly deteriorated leading to her death 6 months after the diagnosis has been established.

Discussion

Epithelioid hemangioendothelioma is a very rare type of tumor with, up to today, unestablished incidence and unknown etiology and less than 500 reported cases worldwide. It is included in the group of vascular tumors origi-

nating from epithelioid or histiocytoid endothelial cell representing 1% of all vascular neoplasms. Usually is considered to be a tumor of low to borderline malignancy following an unpredictable clinical course. In most cases clinical course in mainly intermediate, one between haemangioma and angiosarcoma although cases of very aggressive expression of tumor have been reported in literature^{3,4}. It is commonly affecting middle-aged patients although it can be found in all age groups – several cases have been reported in pediatric patients^{5,6} and it shows female predominance³.

EHE is usually found accidentally since majority of patients are either asymptomatic or have unspecific signs or only mild symptoms in time of diagnosis such as cough, sputum, chest pain or dyspnea in case of pulmonary EHE^{5,7}; right upper quadrant pain and weight loss, nausea, weakness and fatigue in hepatic EHE⁸; paresis of the limbs, seizures, visual disturbances, even intracerebral hemorrhage in cerebral EHE^{4,9,10}. Several studies

tried to identify parameters that would help predict the biologic behaviour and clinical outcome of EHE but results have not been entirely conclusive and unified. Mitotic activity (>1 or >3 mitoses per 50 high power fields depending on the study), size (> 3.0 cm in diameter), cellular atypia, necrosis, high cellularity and extensive spindling are features that have reached statistical significance in some studies (but not in all) and may help differentiate tumors that should be regarded as aggressive and treated as such from the day of diagnosis, from those that could be designated low-risk and for which a good prognosis is anticipated^{3,4,9,11}. Symptoms at presentation, hepatic metastases, peripheral lymphadenopathy and lymphangitic spread of tumor are also prognostic factors indicating increased mortality in a number of studies^{3,4,7,9,11}. Tumor can arise from almost any organ but is most commonly located in soft tissues, liver, lungs, bones and skin. It can be manifested as an unicentric or multicentric disease of a single organ or as a multiorgan disease, whether it is presented simultaneously or sequentially. In latter, it is difficult to prove if tumor is multicentric or there is a primary lesion with multiple organ metastasis^{3,5,11}. Prognosis is often uncertain because of unspecific behaviour shown by EHE that seems to elude all efforts to evaluate it with greater amount of certainty using prognostic factors and for which EHE has been rightfully referred to as a »clinical chameleon«¹². Reports have been made of patients living from several months after diagnosis has been established, up to 30 years, sometimes even with extensive parenchymal involvement^{3,7} with expected survival between 1–20 years and intermediate clinical course.

Presented here is a case of a disseminated EHE affecting patient's lungs, liver, spleen, lymph nodes, lumbosacral vertebral column, iliac bones and central nervous system. This extent of multiorgan involvement, especially with synchronous central nervous system and bone dissemination, to the best of the authors knowledge, has not been reported nor described in literature till now. Questions remain unanswered whether this is the case of synchronous or sequential organ involvement as well as whether this is the case where the tumor remained dormant through 17 years and then transformed into aggressive, malignant form disseminating in mentioned locations^{13,14}. Typically, histology of EHE reveals clusters of rounded or slightly spindled eosinophilic endothelial cells arranged in nests or cords. Tumor cells have abundant eosinophilic cytoplasm filled with numerous intracellular vacuoles. Any mitotic figures are not a characteristic finding for EHE, but their presence, as already mentioned, is a predictor of an unfavourable outcome. Immunohistochemical stains of EHE cases show positivity for CD34, CD31, factor VIII-RAG and vimentin^{3,10,11}. Negativity of epithelial marker cytokeratin is essential to

exclude tumors of the epithelial origin, although small percentage of EHE tend to coexpress makers of both endothelial and epithelial origin³.

In our case diagnosis was based on histological and immunohistochemical evidence as well as radiological findings of typical multiple pulmonary nodules. Cellular atypia, symptoms at presentation and metastatic spread spoke in favour of high malignant potential as well as fulminant course of the disease confirmed by fierce progression registered by control cerebral MR performed in 2 months period and abdominal CT performed in 6 months period, spoke in favour of high malignant potential and aggressive nature of the tumor described.

Due to rarity of the tumor and specific tumor biology no standard therapy has been established to this day. Several spontaneous remissions have been reported and only anecdotal examples of remissions due to applied therapy. Surgical excision of a localized disease has the greatest shown benefit and should be considered as the treatment of choice although such approach has limited merit in a disseminated setting^{3,14}. In asymptomatic patients as well as in patients with successful surgical tumor resection regular follow up must be performed. EHE are chemo- and radioresistant tumors¹⁵. In case of a widespread disease, several chemotherapy protocols using numerous cytostatic agents have been reported with a single case of complete remission¹⁶ and several cases of small results or none. Immunotherapy using interferon has shown controversial results ranging from partial response¹⁷ to stable disease. Report has been made on patient with hepatic EHE with pulmonary metastasis who was successfully treated with talidomide¹⁸. Controlled clinical trials are needed to determine clinical benefits from those types of treatment^{19,20}.

Conclusion

Epithelioid hemangioendothelioma is vascular tumor regarded to be of low malignant potential. Malignant variants are extremely rare. In the presented case tumor malignancy is demonstrated by multiorgan dissemination, rapid progression and histological finding of atypia. Based on the presented case and available literature it is opinion of the authors that the usual designation of EHE as a low-grade tumor has to be reevaluated and more controlled clinical studies to present unified prognostic criteria have to be performed keeping in mind other known entities such as gastrointestinal stromal tumors that have proven, as well as EHE, to potentially have very unfavourable clinical forms. Differentiation parameters between multicentric versus metastatic tumor origins cases of multiple tumor sites is still to be clarified. Also, controlled clinical trials that may indicate effective treatment options are much needed.

REFERENCES

1. DAIL DH, LIEBOW AA, Am J Pathol, 78 (1975) 6. — 2. WEISS SW, ENZINGER F, Cancer, 50 (1982) 970. — 3. WEISS SW, GOLDBLUM JR. Hemangioendothelioma: Vascular tumors of Intermediate malignancy. In: Enzinger and Weiss's Soft tissue tumors. 5th ed. (Philadelphia. PA: Mosby-Elsevier; 2008). — 4. FERNANDES AL, RATILAL B, MAFRA M, MAGALHAES C, Neuropathology, 26 (2006) 201. — 5. MADHUSUDHAN KS, SRIVASTAVA DN, GAMANAGATTI S, Indian J Pediatr, 77 (2010) 699. — 6. ROSSI GA, TOMA P, SACCO O, FREGONESE B, PODESTA E, DODERO P, SIVERSTRIG, GAMBINI C, Eur Respir J, 22 (2003) 387. — 7. KITAICHI M, NAGAI S, NISHIMURA K, ITOH H, ASAMOTO H, IZUMI T, DAIL DH, Eur Respir J, 12 (1998) 89. — 8. FILIPEC KANIŽAJ T, ČOLIĆ CVRLJE V, MRZLJAK A, KARDUM-SKELIN I, ŠUŠTERČIĆ D, ŠEGRO D, GUŠTIN D, KOČMAN B, Coll Antropol 34 (2010) 177. — 9. KAJIHARA Y, IKAWA F, OHBAYASHI N, IMADA Y, HIDAHA T, MATSUSHIGE T, MITSUHARA T, INAGAWA T, OHAMA E, No To Shinkei, 57 (2005) 690. — 10. DEYRUP AT, TIGHIOUART M, MONTAG AG, WEISS SW, Am J Surg Pathol, 32(2008) 924. — 11. NIELSEN GP, SRIVASTAVA A, KATTAPURAM S, DESHPANDE V, O'CONNELL JX, MANGHAM CD, ROSENBERG AE, Am J Surg Pathol, 33 (2009) 270. — 12. BÖLKE E, GRIPP S, PEIPER M, BUDACH W, SCHWARTZ A, ORTH K, REINECKE P, VAN DE NES JA, Eur J Med Res, 11 (2006) 462. — 13. CHEN TM, DONINGTON J, MAK G, BERRY GJ, ROUSS SJ, ROSEN GD, UPADHYAY D, Respir Med, 100 (2006) 367. — 14. MA J, WANG L, MO W, YANG X, XIAO J, Eur Spine J, 22 (2011) (epub ahead of print). — 15. CELIKEL C, YUMUK PF, BASARAN G, YILDIZELI B, KODALLI N, AHISKALI R, APMIS, 115 (2007) 881. — 16. PINET C, MAGNAN A, GARBE L, PAYAN MJ, VERVLOET D, Eur Respi J, 14 (1999) 237. — 17. CALABRÒ L, DI GIACOMO AM, ALTOMONTE M, FONSATTI E, MAZZEI MA, VOLTERRANI L, MIRACCO C, MAIO M, J Exp Clin Cancer Res, 26 (2007) 145. — 18. RAPHAEL C, HUDSON E, WILLIAMS L, LESTER JF, SAVAGE PM, J Med Case Reports, 4 (2010) 413. — 19. ŠTAMBUK S, ŠUNDOV D, KURET S, BELJAN R, ANĐELINOVIĆ Š, Coll Antropol, 34 (2010) 763. — 20. KLINAR I, BLAŽIN A, BAŠIĆ M, PLANTAŠ I, BIŠKUPIĆ K, Coll Antropol, 34 (2010) 481.

A. Duletić-Načinović

Department of Hematology, Rijeka University Hospital Center, Krešimirova 42, 51000 Rijeka, Croatia
e-mail: antica.duletic-nacinovic@ri.t-com.hr

AGRESIVNI MULTIFOKALNI OBLIK EPITELOIDNOG HEMANGIOENDOTELIJOMA: PRIKAZ SLUČAJA

SAŽETAK

Epitelioidni hemangioendotelijom (EHE) je vrlo rijedak tumor vaskularnog podrijetla. Deil i Leibow su 1975. godine prvi put opisali njegov pulmonalni oblik i nazvali ga »intravaskularni bronhoalveolarni tumor« (IVBAT). Nakon toga se u literaturi opisuje pojavnost tumora u mekim tkivima, jetri, plućima, kostima i koži. Iako se smatra tumorom niskog ili granično malignog potencijala sa, uglavnom, sporom progresijom, opisani su i agresivni oblici. Ovdje je prikazan slučaj 46-godišnje bolesnice kod koje je maligni tumor multifokalno zahvatio pluća, jetru, slezenu, lumbalne kralješke, ilijačne kosti i središnji živčani sustav. Koliko je autorima poznato, do sada u literaturi engleskog govornog područja nije objavljen slučaj malignog EHE sa multiorganskom zahvaćenošću ovakvih razmjera i vrlo agresivnog tijeka.