

# Palaeodemographic and palaeopathological characteristics of individuals buried in three Bronze Age sites from southern Croatia

• M. Novak, V. Vyroubal, Ž. Bedić •

Department of Archaeology , Croatian Academy of Sciences and Arts, Zagreb, Croatia

## Address for correspondence:

Dr. Mario Novak

Department of Archaeology

Croatian Academy of Sciences and Arts

Ante Kovačića 5, 10 000 Zagreb, Croatia

E-mail: [mnovak@hazu.hr](mailto:mnovak@hazu.hr)

**Bull Int Assoc Paleodent. 2011;5(2):15-27.**

## Abstract

The purpose of this study is to reconstruct paleodemographic and paleopathological characteristics of sixteen individuals (three subadults, seven males and six females) buried in three Bronze Age sites (Crip, Matkovići, and Veliki Vanik) located in southern Croatia. The analysed sample is characterised by the presence of pathological changes which are often associated with stressful episodes such as anaemia, inadequate nutrition, infectious diseases and the occurrence of parasites. Cribra orbitalia, dental enamel hypoplasia, porotic hyperostosis and periostitis were observed in seven out of sixteen analysed skeletons. One ulnar “parry” fracture and three fractures of the frontal bone strongly suggest the presence of deliberate interpersonal violence within the studied communities. The average life span of the adults, as well as the number and character of the observed pathologies, suggest a relatively poor life quality and harsh living conditions in the studied region during the Bronze Age.

**Keywords:** southern Croatia; Bronze Age; demography; palaeopathology; bone trauma

## Introduction

In the past twenty years bioarchaeology in Croatia has experienced strong growth not only through the formation of new osteological collections and the start of the BA anthropology studies in Zagreb, but also by employing a number of young anthropologists in several institutions. These processes resulted in publication of numerous scientific papers which significantly contributed to the knowledge of paleodemographic and paleopathological characteristics of Croatian archaeological populations through the analyses of human skeletal remains. These analyses covered a broad period from

Mesolithic to the Early Modern period (19<sup>th</sup> century) with most studies focusing on Antique and Mediaeval populations. Unfortunately, prehistoric populations are poorly represented in these studies primarily due to an extremely small number of well-preserved skeletons from these periods, and the bioarchaeological analyses of human skeletal remains from the Bronze Age are very rarely published (1-3).

Implementation of large infrastructure projects (construction of highways, pipelines, etc.) in the last fifteen years in Croatia has led to numerous protective large-scale archaeological excavations which have resulted in large quantities of human skeletal remains from all chronological periods including the Bronze Age. A large portion of the skeletal material has been integrated into the osteological collection of Department of Archaeology at the Croatian Academy of Sciences and Arts in Zagreb, thus creating an appropriate assemblage for the implementation of comprehensive bioarchaeological studies, as well as publication of the results derived from these analyses.

In order to at least partially eliminate numerous unknown aspects about the conditions and quality of life of the Bronze Age inhabitants of southern Croatia this paper presents the results of bioarchaeological analysis of human skeletal remains of sixteen individuals buried at three Bronze Age sites (Crip, Matkovići, and Veliki Vanik) in the Split-Dalmatia County.

## Materials and methods

### *Archaeological context of the analysed sites*

All sites analysed in this paper were excavated between 2007 and 2009 as part of the rescue archaeological excavations conducted by Arheo plan Ltd. on a section of the future Zagreb-Split high-speed motorway in the Split-Dalmatia County (Figure 1). Radiocarbon dating and preserved archaeological artefacts date the use of these sites between the Early and the Late Bronze Age, i.e. to the 2<sup>nd</sup> millennium BC.

The site of Crip is located near the Kokorići village, a few hundred meters south of the Vrgorac - Makarska road and consists of four burial mounds dated between the Bronze Age and Late Mediaeval period. Burial mounds were positioned in pairs, in a row directed north - south, and the distance among them varied from only few meters to 50 meters (4). They were made from deposits of rock in the upper part and from deposits of soil in the lower part. Only burials dated to the Bronze Age are included in this analysis, and these are: 1) burial mound 1, graves 4 (two individuals) and 5 (two individuals) dated between the end of the Early and the beginning of the Middle Bronze Age, i.e. between 1730 and 1530 BC; 2) burial mound 3, grave 2 (two individuals) dated to the Middle Bronze Age, i.e. between 1520 and 1420 BC; 3) burial mound 4, grave 2 (one individual) dated to the Bronze age (4). All analysed individuals were buried in a flexed position, in graves in the shape of a stone coffin (4). The only artefacts found in and around the graves were fragments of pottery and flints dated to the Bronze Age (4).

The Gomila burial mound is located 200 m south of the Matkovići hamlet, about a kilometre south-west of the intersection of Split-Vrgorac and Vrgorac-Makarska roads (4). The burial mound was constructed of rough stone in the upper part and of dirt in the lower part. It was circular-shaped with a diameter of 22 m with a relative height of 3.4 m (4). Two prehistoric graves in the shape of stone coffins were found in the central part of the burial mound (4). In the northern grave (gr. 1), which was oriented north/northeast-south/south-west, three individuals were buried. In the southern grave (gr. 2), also oriented north/northeast-south/southwest, only one individual was buried. All individuals were buried in a flexed position. The recovered archaeological material comprises several fragments of Bronze Age pottery (4). Radiocarbon dating put the use of grave 1 between 1460 and 1310 BC (Middle Bronze Age), whilst the use of grave 2 dated between 1380 and 1120 BC (end of the Middle and the beginning of the Late Bronze Age) (4).

The Veliki Vanik burial mound is located in the region of the Kotezi settlement, south of the Vrgorac - Kokorići road (4). It was made of rock and soil deposit with a circular base of 20 m and a relative height of 3.5 m (4). The burial mound was partly destroyed during the Early Modern period when a stone drywall was erected nearby and some of the rock material was harvested from the site (4). Three Bronze Age graves (one in the shape of a stone coffin and two inhumations in plain soil) were explored during the excavations: 1) grave 2 (three individuals buried in flexed position) dated between the end of the Early and the beginning of the Middle Bronze Age, i.e. between 1690 and 1500 BC; 2) grave 3 (one individual) dated to the Bronze Age; 3) grave 3 (one individual) dated to the Early Bronze Age, i.e. between 1880 and 1650 BC (4). Discovered artefacts (hair ornament made of coiled copper wire and fragments of pottery) put the use of these graves to the Bronze Age (4).

#### *Methods used*

During a comprehensive anthropological analysis of skeletal remains of the individuals buried in Crip, Matkovići, and Veliki Vanik, an inventory of preserved bones was conducted, the sex was determined and age at death was assessed, and present pathological changes were analysed.

The sex and age at death of the adult individuals was determined using standard methods (5-9), while age at death of subadults was determined using the chronology of epiphyseal fusion, diaphyseal lengths, and dental eruption criteria (5,10). The sex of subadults under 15 years of age was not determined.

Following pathological changes were included into the analysis: caries, antemortem tooth loss, cribra orbitalia, porotic hyperostosis, dental enamel hypoplasia, degenerative osteoarthritis on vertebrae, periostitis and trauma. The average height of adults was calculated using the Trotter-Gleser technique (11).

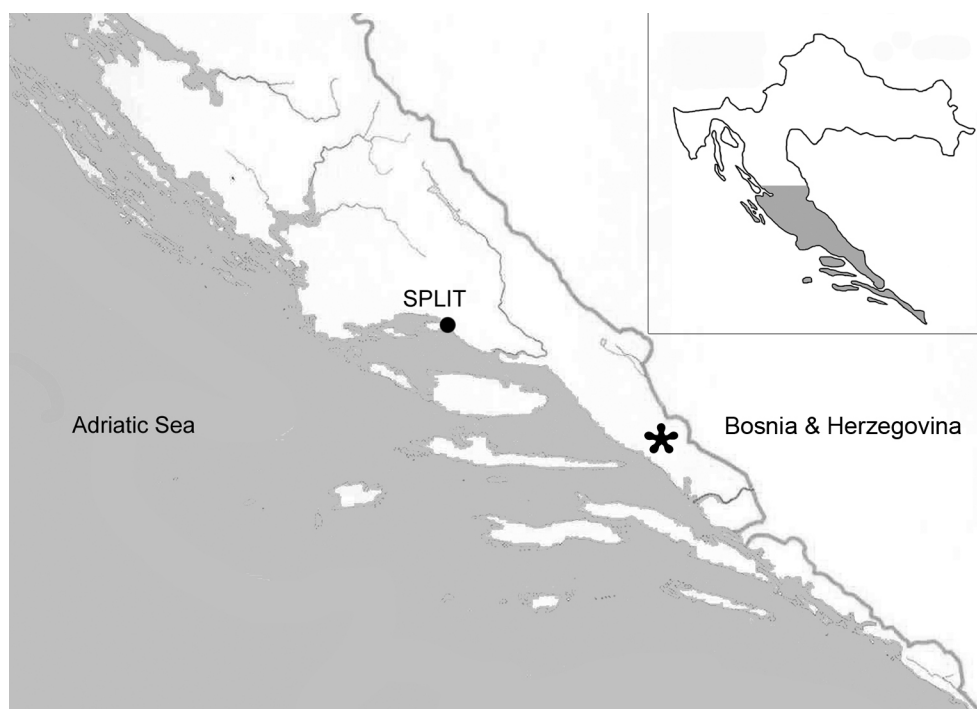


Figure 1 Map of Croatia with geographical location of the analysed sites (marked by asterisk)

## Results

The analysed sample consists of skeletal remains of sixteen individuals buried at three Bronze Age sites (Crip, Matkovići, and Veliki Vanik) of which three are subadults, seven are males and six are females. The average age at death for adults in this sample is 33.5 years. Detailed description of each skeleton by site is given below.

### *Crip*

Burial mound 1, grave 4, individual A - well preserved skeleton of an adult male (40 to 45 years). No pathological changes were observed in this individual.

Burial mound 1, grave 4, individual B - well preserved skeleton of an adult male (45 to 50 years). This individual exhibits antemortem tooth loss of left maxillary PM1 and PM2, and degenerative osteoarthritis on the temporomandibular joint.

Burial mound 1, grave 5, individual A - well preserved skeleton of a young male (25 to 30 years). The only pathology recorded in this skeleton is dental enamel hypoplasia on maxillary and mandibular canines.

Burial mound 1, grave 5, individual B - very well preserved skeleton of a young adult female (18 to 25 years). This individual exhibits healed porotic hyperostosis of the cranium vault and dental enamel hypoplasia on the mandibular canines.

Burial mound 3, grave 2, individual A - poorly preserved male skeleton (35 to 50 years). This individual

exhibits an antemortem well-healed “parry” fracture of the distal left ulna.

Burial mound 3, grave 2, individual B - poorly preserved female skeleton (20 to 35 years). No pathological changes were observed in this individual.

Burial mound 4, grave 2 - poorly preserved skeleton of an adult female (40 to 50 years). No pathological changes were observed in this individual.

#### *Matkovići*

Grave 1, individual A - very well preserved skeleton of an adult female (35 to 40 years). This individual exhibits carious lesions on maxillary right PM2, M1, M2 and M3, antemortem tooth loss of the maxillary right canine, healed porotic hyperostosis on both parietal bones, benign cortical defect of the muscle insertions of *latissimus dorsi* on right humeral bone, and degenerative osteoarthritis on the 4<sup>th</sup> and the 5<sup>th</sup> lumbar vertebrae.

Grave 1, individual B - very well preserved subadult skeleton (12 to 14 years). This individual exhibits an antemortem well healed round-shaped fracture of the frontal bone (Figure 2) and active form of periostitis on both tibiae.

Grave 1, individual C - very well preserved subadult skeleton (5 to 7 years). This skeleton exhibits active form of cribra orbitalia in both orbits (Figure 3) and active form of periostitis on the left tibia.

Grave 2 - very well preserved skeleton of an adult male (45 to 50 years). This skeleton exhibits carious lesion on mandibular left M1, antemortem tooth loss of the maxillary left PM2 and M1, dental enamel hypoplasia on mandibular canines, an antemortem well healed oval-shaped fracture of the frontal bone (Figure 2), and degenerative osteoarthritis in both knee joints.

Beside the pathological changes, some other non-metric characteristics such as metopic sutures were observed on frontal bones of the older subadult from grave 1 and the adult male from grave 2 (Figure 2).

An approximate height of both adult individuals from Matkovići was determined based on the maximum femur length: female was approximately 162.7 cm tall, while male was approximately 173.1 cm tall.

#### *Veliki Vanik*

Grave 2, individual A - poorly preserved subadult skeleton (5-7 years). No pathological changes were observed in this individual.

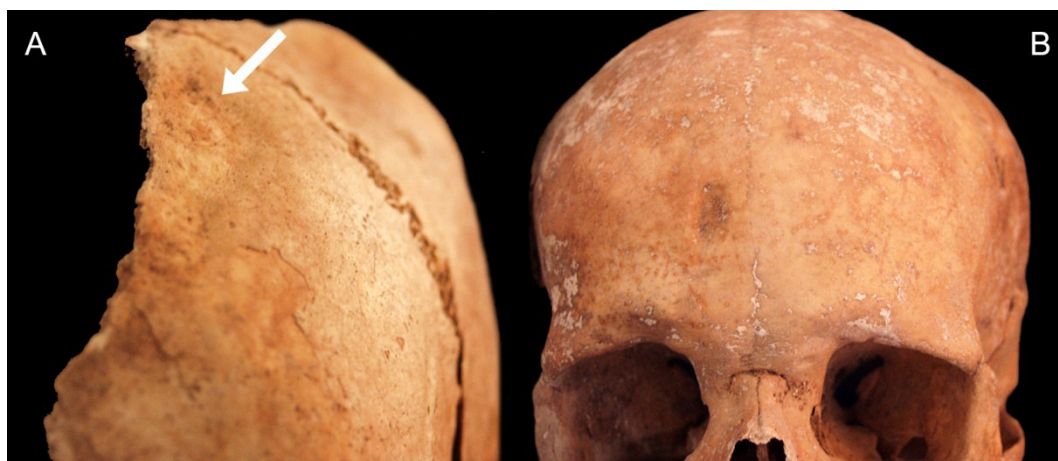Grave 2, individual B - well preserved skeleton of an older adult male (50 to 60 years). This individual exhibits carious lesions on both mandibular M3 (Figure 4), antemortem tooth loss of both mandibular PM2 and both mandibular M1, and degenerative osteoarthritis on the 7<sup>th</sup> cervical vertebra.

Grave 2, individual C - well preserved skeleton of an adult female (40 to 50 years). This individual exhibits antemortem tooth loss of left mandibular M1 (Figure 5) and right mandibular M1 and M3, as well as an antemortem well healed oval-shaped fracture of the frontal bone (Figure 6).

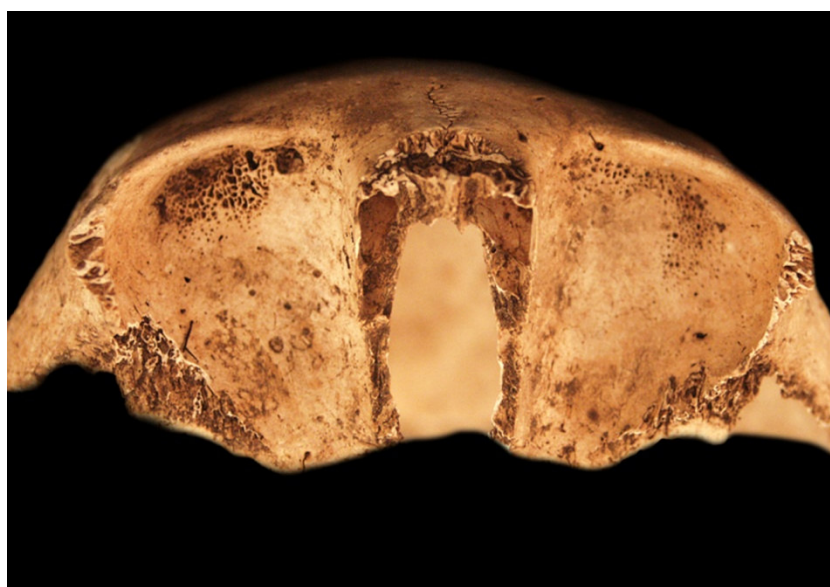
Grave 3 - poorly preserved skeleton of an older male (50 to 60 years). This individual exhibits healed porotic hyperostosis of the cranium vault (Figure 7) and degenerative osteoarthritis in the left shoulder, left hip, two cervical and two thoracic vertebrae (Figure 8).

Grave 4 - well preserved skeleton of an adult female (35 to 45 years). No pathological changes were observed in this individual.

An approximate height of an adult female buried in grave 4 from Veliki Vanik was determined based on the maximum femur length: she was approximately 155.6 cm tall.



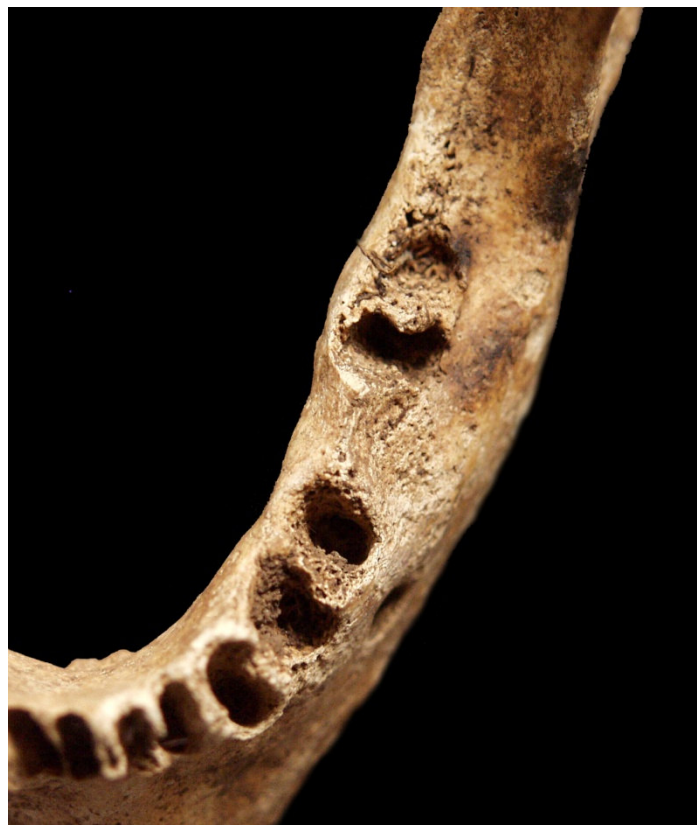*Figure 2 A: Antemortem healed fracture of the frontal bone and metopic suture; Matkovići, grave 1, individual B, subadult. B: antemortem healed fracture of the frontal bone and metopic suture; Matkovići, grave 2, male (photo by Vyroubal V., 2009)*



*Figure 3 Active cribra orbitalia in both orbits; Matkovići, grave 1, individual C, subadult (photo by Vyroubal V., 2009)*



*Figure 4 Caries on the left mandibular M3; Veliki Vanik, grave 2, individual B, male (photo by Vyroubal V., 2011)*



*Figure 5 Antemortem tooth loss of the left mandibular M1; Veliki Vanik, grave 2, individual C, female (photo by Vyroubal V., 2011)*

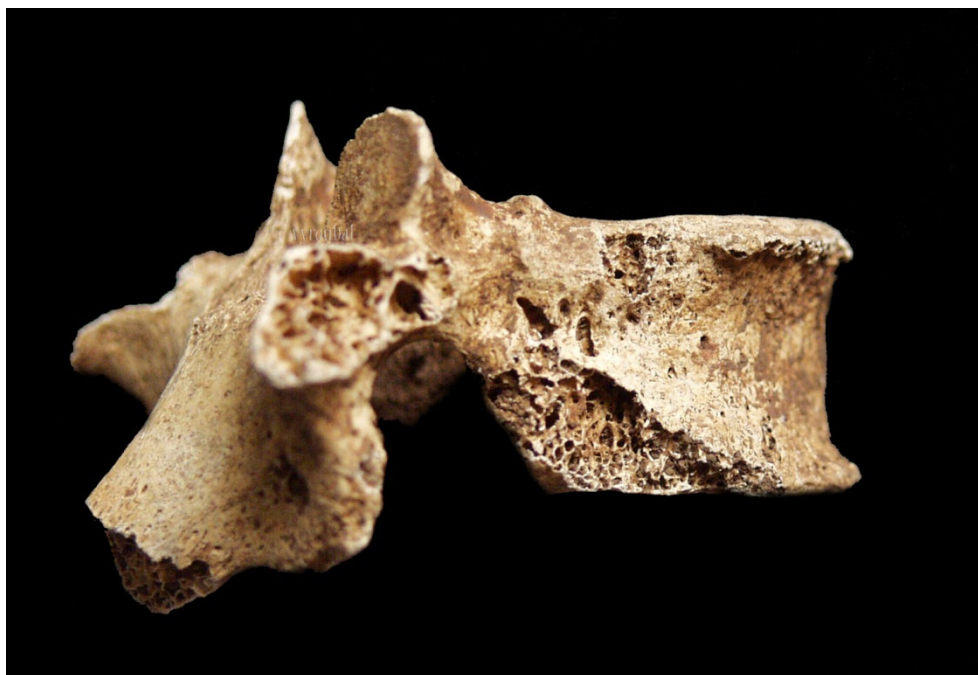

*Figure 6 Antemortem healed fracture of the frontal bone and metopic suture; Veliki Vanik, grave 2, individual C, female (photo by Vyroubal V., 2011)*



*Figure 7 Healed porotic hyperostosis on the occipital bone; Veliki Vanik, grave 3, male (photo by Vyroubal V., 2011)*





*Figure 8 Degenerative osteoarthritis (osteophytes) on the thoracic vertebra; Veliki Vanik, grave 3, male (photo by Vyroubal V., 2011)*

## Discussion

Although the skeletal sample presented in this paper is small, it contributes to our knowledge about the everyday life of the Bronze Age inhabitants of southern Croatia. The number and character of the observed pathologies, as well as the average life span, suggest a relatively poor quality of life and harsh living conditions in the studied region during the Bronze Age.

Average age at death in the Bronze Age sample from southern Croatia is similar to the average life span recorded in the Bezdanjača Bronze Age series (34.9 years) (2). These values correspond well to the data recorded in most of the Croatian archaeological samples where the average life span varies between 30 and 40 years, depending on site and chronological period (for more details see 2,12,13)

In the Bronze Age skeletal sample from southern Croatia dental pathologies (caries and antemortem tooth loss) were registered in three adult individuals. The observed pathologies could be a result of an advanced age of the affected individuals, but could also indicate poor oral hygiene in the observed communities. It is known that dental pathologies are age-dependent, i.e. their frequencies increase with advanced age. The fact that carious lesions and antemortem tooth loss in the analysed sample occur in individuals over 35 years of age (both adults from Matkovići and the male adult from Veliki Vanik) make this assumption highly probable. The occurrence of alveodental pathologies in the studied skeletal sample might also be a result of an inadequate oral hygiene, because insufficient oral hygiene that removes dental plaque is the basis of future dental loss (14), i.e. gingival inflammation, which is caused by bacterial plaque, leads to bone resorption and results in tooth loss.

Pathological changes associated with stressful episodes such as anaemia, inadequate nutrition, infectious diseases, and the occurrence of parasites, which manifest in bones and teeth, were recorded in almost half of the analysed sample (7/16) which represents a relatively high prevalence,

especially taking into account the poor preservation of some skeletons. Anaemia caused by iron deficiency that results from malnutrition, endemic parasitism, unhygienic living conditions or chronic gastrointestinal disease (15-17) was most probably present in Matkovići during the Bronze Age as evidenced by the presence of active form of cribra orbitalia in one subadult. Similar lesions affecting the cranial vault, called porotic hyperostosis, which can be associated with disparate aetiologies, including scurvy, rickets, anaemias, treponematoses and limited access to protein (18-20) were observed in the healed form in three individuals: one male from Crip, one male from Veliki Vanik, and in a female from Matkovići. Dental enamel hypoplasia is a subadult disorder usually associated with systemic physiological stress, including malnutrition, infectious diseases and metabolic disorders (14,21,22), and in the analysed sample is present in three adults: one male and one female from Crip, and a male from Matkovići. Periostitis, an indicator of non-specific infectious diseases, was recorded in the active form in both subadults from Matkovići. For comparison, the presence of cribra orbitalia was recorded in the Laganiši skeletal sample (3), while in Bezdanjača, cribra orbitalia was recorded in almost one third of the analysed crania (31.6%) and dental enamel hypoplasia was observed in 35.7% of the analysed teeth (2).

Bone fractures recorded in the analysed Bronze Age skeletal sample strongly indicate the presence of deliberate interpersonal violence. The part of the skeleton that has frequently been utilized as an indicator of such violence is the ulna, particularly the presence of 'parry' fractures on the distal or middle part of the ulna. This type of injury usually results from an attempt to protect oneself from a blow to the head by raising one's arm and exposing the forearm to the full impact of the blow, often resulting in breakage. The "parry" fracture of distal left ulna which was observed in the adult male from Crip may have resulted from an episode of deliberate violence, although the problem of attributing such fractures exclusively to intentional violence was raised by Smith (23) and Judd and Roberts (24). Several authors (25-27) point out that high frequencies of head and face trauma are conclusive proof of intentional violence. In the analysed sample three individuals exhibited fractures of the frontal bones and all cranial injuries are located on the right side. This might indicate that these injuries were sustained while the victims were fleeing their attacker or perhaps while lying prone (28). Usually, the cranial injuries in most archaeological samples are found on the left side because the left side of the skull is the most frequent injury site in a face to face combat with a right-handed aggressor (e.g. 29-31). The fact that all cranial injuries in the Bronze Age sample are located on the frontal bone could indicate an increased level of interpersonal violence in this sample, especially since Walker (25,32) relates the frontal location predominance to deliberate violence. Besides, all recorded cranial injuries are depressed fractures, as depressed injuries of the cranial vault are probably most common type of head injury in an archaeological context (33). Unfortunately, at this moment we cannot determine with certainty whether the intentional violence occurred within a community (e.g. domestic violence) or the fights occurred between communities due to disputes over sources of potable water, plots of fertile land or places for grazing livestock. Compared to the analysed sample, the frequency of cranial fractures in Bezdanjača was relatively high (12.1%) and all observed trauma in this sample were antemortem healed depression fractures (2).

Age, repetitive mechanical strain and genetic influences are usually stressed as the main factors

influencing the presence and severity of vertebral osteoarthritis in archaeological and modern populations (e.g. 34-36). However, studies of vertebral osteoarthritis conducted in the archaeological populations from the region of southern Croatia suggest that this change in this region is primarily a consequence of advanced age and not the result of activity-related stress (37). The assumption of an increased age as the main cause of degenerative osteoarthritis could be also applied in this case considering that osteoarthritis in the analysed sample occurs primarily in individuals with an above-average life-span, i.e. over 40 years of age, with an exception of a female from Matkovići who at the time of death was between 35 and 40 years old.

Four individuals from Matkovići form a separate complex within the studied Bronze Age sample. Specifically, the sex and age distribution of individuals buried in the Matkovići burial mound suggests the possibility that this was the burial place of one family consisting of a husband, wife and two children. This assumption is supported by the radiocarbon dating of bone samples from both graves, but also by the presence of epigenetic traits such as the metopic suture which is known to be hereditary (38,39). Nevertheless, in order to confirm this assumption it is necessary to conduct DNA analysis to determine the degree of genetic kinship between the buried individuals.

## Conclusion

Taking into account the observed bioarchaeological characteristics of individuals buried in Crip, Matkovići, and Veliki Vanik it may be concluded that the everyday life of the Bronze Age populations in the region of contemporary southern Croatia was harsh. Average life span of the individuals from the three Bronze Age sites is very similar to values recorded in other archaeological populations from Croatia. The occurrence of cribra orbitalia, dental enamel hypoplasia, porotic hyperostosis and periostitis in the analysed sample indicates relatively frequent episodes of hunger, epidemics and parasitism suggesting low hygiene level and fragile health. Recorded bone fractures strongly suggest the presence of deliberate interpersonal violence in studied communities but the exact nature of this violence cannot be determined at this point. Considering that the anthropological studies of the Bronze Age human skeletal remains from the Croatian territory have been rarely published, this research along with previously published analyses represents only the initial step in creating a much larger database of palaeodemographic and palaeopathological characteristics of the Bronze Age inhabitants of Croatia.

## Acknowledgements

Authors would like to thank to Nela Kovačević Bokarica from the Arheo plan Ltd. who provided the skeletal material, the archaeological data and radiocarbon dating for all three sites. Authors would also

like to thank to Dr. Mario Šlaus, Department of Archaeology of the Croatian Academy of Sciences and Arts, for his comments and suggestions. This study was financially supported by a grant from the Ministry of Science, Education and Sports of the Republic of Croatia (Grant No. 101–197–0677–0670).

## References

1. Boljunčić J. Analiza zatiljne kosti populacije ljudi iz brončanodobne nekropole u špilji Bezdanjači (Hrvatska). *Pril Inst arheol Zagrebu*. 1994/1995;11/12:151-66.
2. Šlaus M. *The Bioarchaeology of Continental Croatia. An analysis of human skeletal remains from the prehistoric to post-medieval periods*. Oxford: Archaeopress; 2002.
3. Rajić Šikanjić P. Analysis of human skeletal remains from Laganiši cave. Laganiši Cave. In: Komšo D, editor. *A Place of Life and a Place of Death*. Pula: Arheološki muzej Istre; 2008. p. 37-44.
4. Mucić K, Kovačević Bokarica N. Doprinosi poznavanju povijesti Vrgoračke krajine na osnovi rezultata novijih arheoloških istraživanja. In: Tomasović M, editor. *Arheološka istraživanja na trasi autoceste u Zabiokovlju i Plini*. Makarska: Gradski muzej Makarska; 2011. p. 125-212.
5. Bass WM. *Human Osteology. A Laboratory and Field Manual of the Human Skeleton*. Columbia: Missouri Archaeological Society; 1995.
6. Krogman WM, Iscan MY. *The human skeleton in forensic medicine*, 2<sup>nd</sup> ed. Springfield: C.C. Thomas; 1986.
7. Meindl RS, Lovejoy CO. Ectocranial suture closure: a revised method for the determination of skeletal age at death based on the lateral-anterior sutures. *Am J Phys Anthropol*. 1985;68:57-66.
8. Brooks S, Suchey JM. Skeletal age determination based on the os pubis: a comparison of the Acsádi-Nemeskéri and Suchey-Brooks methods. *Hum Evol*. 1990;5:227-38.
9. Lovejoy CO, Meindl RS, Pryzbeck TR, Mensforth RP. Chronological metamorphosis of the auricular surface of the ilium: a new method for the determination of age at death. *Am J Phys Anthropol*. 1985;68:15-28.
10. Scheuer L, Black S. *Developmental Juvenile Osteology*. San Diego: Academic Press; 2000.
11. Trotter ML. Estimation of stature from intact limb bones. In: Stewart TD, editor. *Personal Identification in Mass Disasters*. Washington: Smithsonian Institution; 1970. p. 71-83.
12. Šlaus M. *Bioarheologija – demografija, zdravlje, traume i prehrana starohrvatskih populacija*. Zagreb: Školska knjiga; 2006.
13. Novak M, Šlaus M, Pasarić M. Subadult stress in the Medieval and Early Modern populations of continental Croatia. *Pril Inst arheol Zagrebu*. 2009;29:247-70.
14. Hillson S. *Dental Anthropology*. Cambridge: Cambridge University Press; 2000.
15. Carlson DS, Armelagos GJ, Van Gerven DP. Factors influencing the etiology of cribra orbitalia in prehistoric Nubia. *J Hum Evol*. 1974;3:405-10.
16. Hengen OP. Cribra orbitalia: Pathogenesis and probable etiology. *Homo*. 1971;22:57-75.
17. Mittler DM, Van Gerven DP. Developmental, diachronic, and demographic analysis of cribra orbitalia in the medieval Christian populations of Kulubnarti. *Am J Phys Anthropol*. 1994;93:287-97.
18. Stuart-Macadam P. Porotic hyperostosis: new evidence to support the anaemia theory. *Am J Phys Anthropol*. 1987;74:521-26.
19. Ortner DJ. *Identification of Pathological Conditions in Human Skeletal Remains*. London: Academic Press; 2003.
20. Walker PL, Bathurst RR, Richman R, Gjerdrum T, Andrushko VA. The causes of porotic hyperostosis and cribra orbitalia: a reappraisal of the iron-deficiency-anaemia hypothesis. *Am J Phys Anthropol*. 2009;139:109-25.
21. Goodman AH, Martinez C, Chavez A. Nutritional supplementation and the development of linear enamel hypoplasia in children from Solis, Mexico. *Am J Clin Nutr*. 1991;53:773-81.
22. Pindborg JJ. *Pathology of the dental hard tissues*. Philadelphia: W.B. Saunders; 1970.
23. Smith MO. „Parry“ fractures and female directed interpersonal violence: implications from the Late Archaic Period of west Tennessee. *Int J Osteoarchaeol*. 1996;6:84-91.

24. Judd MA, Roberts CA. Fracture trauma in a medieval British farming village. *Am J Phys Anthropol.* 1999;109:229-43.
25. Walker PL. Cranial injuries as evidence of violence in prehistoric southern California. *Am J Phys Anthropol.* 1989;80:313-23.
26. Alvrus A. *Fracture* patterns among the Nubians of Semna South, Sudanese Nubia. *Int J Osteoarchaeol.* 1999;9:417-29.
27. Jurmain R, Bartelink EJ, Leventhal A, Bellifemine V, Nechayev I, Atwood M, DiGiuseppe D. Paleoepidemiological patterns of interpersonal aggression in a prehistoric central California population from CA-ALA-329. *Am J Phys Anthropol.* 2009;139:462-73.
28. Larsen CS. *Bioarchaeology: Interpreting behavior from the human skeleton.* Cambridge: Cambridge University Press; 1999.
29. Djurić MP, Roberts CA, Rakočević ZB, Djonić DD, Lešić AR. Fractures in Late Medieval skeletal populations from Serbia. *Am J Phys Anthropol.* 2006;130:167-78.
30. Owens LS. Craniofacial trauma in the Prehispanic Canary Islands. *Int J Osteoarchaeol.* 2007;17:465-78.
31. Jiménez-Brobeil SA, du Souich P, Al Oumaoui I. Possible relationship of cranial traumatic injuries with violence in the south-east Iberian Peninsula from the Neolithic to the Bronze Age. *Am J Phys Anthropol.* 2009;140:465-75.
32. Walker PL. Wife beating, boxing, and broken noses: skeletal evidence for the cultural patterning of violence. In: Martin DL, Frayer DW, editors. *Troubled times: Osteological and archaeological evidence of violence.* New York: Gordon and Breach; 1997. p. 145-80.
33. Roberts CA, Manchester K. *The archaeology of disease.* Ithaca: Cornell University Press; 1995.
34. Rogers J, Waldron T, Dieppe P, Watt I. Arthropathies in palaeopathology: the basis of classification according to most probable cause. *J Archaeol Sci.* 1987;14:179-93.
35. Knüsel CJ, Gögel S, Lucy D. Comparative degenerative joint disease of the vertebral column in the medieval monastic cemetery of the Gilbertine Priory of St. Andrew, Fishergate, York, England. *Am J Phys Anthropol.* 1997;103:481-95.
36. Spector TD, MacGregor AJ. Risk factors for osteoarthritis: genetics. *Osteoarthr Cartilage.* 2004;12:S39-S44.
37. Novak M, Šlaus M. Vertebral pathologies in two early modern period (16th-19th century) populations from Croatia. *Am J Phys Anthropol.* 2011;145(2):270-81.
38. Torgersen JH. A roentgenological study of the *metopic suture.* *Acta Radiol.* 1950;3:1-11.
39. Torgersen JH. The developmental genetics and evolutionary meaning of the metopic suture. *Am J Phys Anthropol.* 1951;9:193-207.