

Endoscopically Assisted Latissimus Dorsi Flap Harvesting and Breast Reconstruction in Young Female with Poland Syndrome

Zoran Veir¹, Anto Dujmović¹, Mladen Duduković¹, Davor Mijatović¹, Bruno Cvjetičanin¹ and Merica Veir²

¹ University of Zagreb, Zagreb University Hospital Center, Department of Plastic and Reconstructive Surgery and Breast Surgery, Zagreb, Croatia

² Srćana Polyclinic, Zagreb, Croatia

ABSTRACT

We will describe a second phase of breast reconstruction on a young girl suffering from Poland syndrome. She has the breast, pectoralis major and minor muscle aplasia on the right side. She has no other deformities. The best result is achieved by combining latissimus dorsi flap and a silicone implant, and even better aesthetic result is accomplished with endoscopically assisted latissimus dorsi harvesting. Purpose of this operation is to correct the chest asymmetry and to accomplish good aesthetic result.

Key words: Poland syndrome, breast implant, latissimus dorsi flap, endoscopically assisted

Introduction

Poland syndrome includes the features of ipsilateral breast and nipple hypoplasia or aplasia, deficiency of subcutaneous fat and axillary hair, absence of the sternal head of the pectoralis major muscle, hypoplasia of the rib cage, and hypoplasia of the upper extremity. Involvement of adjacent muscles, including the pectoralis minor, serratus, latissimus dorsi, and external oblique, also has been described. Skeletal deformities may involve absence of portions of the ribs or costal cartilages anteriorly. In severe cases, anterior lung herniation may be present. The scapula may be smaller with winging. The upper extremity also may be hypoplastic. The upper arm, forearm, and fingers may be shortened, which is termed brachysymphalangism. Simple, complete, or incomplete can also be found in patients with Poland syndrome^{1,2}.

The incidence is estimated to range from one in 7,000 to one in 100,000 live births³.

Varying techniques for the repair of these deformities have been reported^{4,5}.

In a female the reconstruction of thoracic wall usually involves the use of implants or a tissue expander and latissimus dorsi flap^{6,7}. We have harvested a latissimus dorsi endoscopically and in this way minimized a scar problem.

Case Report

We present a case of seventeen years old girl with Poland syndrome. She had an aplasia of right breast with pectoralis major and minor muscle aplasia. The rest of her anatomy was normal.

She has already done a first stage of reconstruction in another hospital where she had been implanted a breast expander under the skin of the right breast. During the period of two years the expander was inflated with saline and at first examination in our hospital the size of breast was similar, but there were problems with not satisfactory submammary and deltopectoral folds. Upper pole of

the right breast seemed to be empty. The problem with inframammary fold is that it was almost 3 cm lower than the left one.

Surgical Technique

Preoperatively the patient was measured and made marks on skin (Figure 1). Under general anesthesia, the

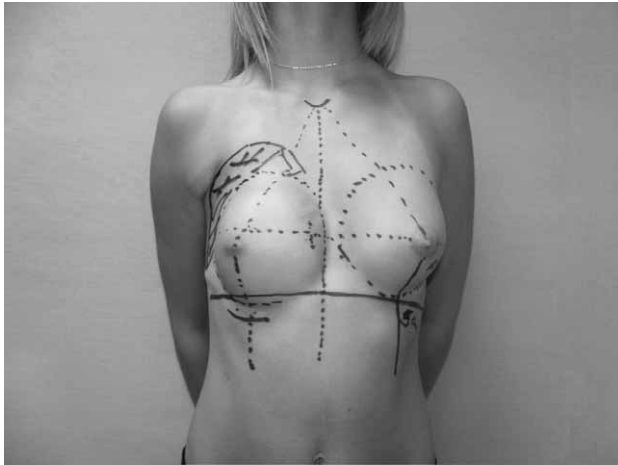


Fig. 1.

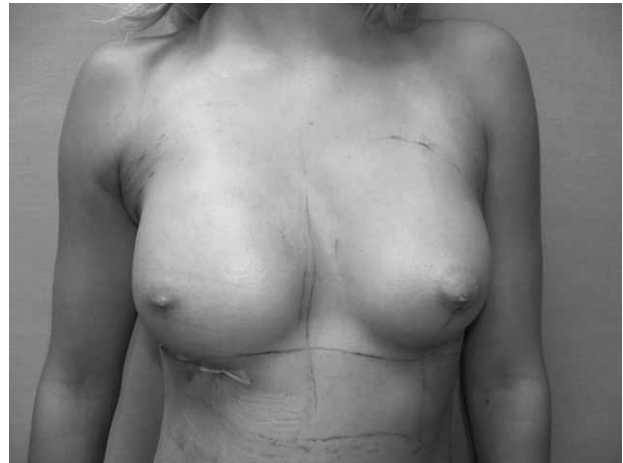


Fig. 4.

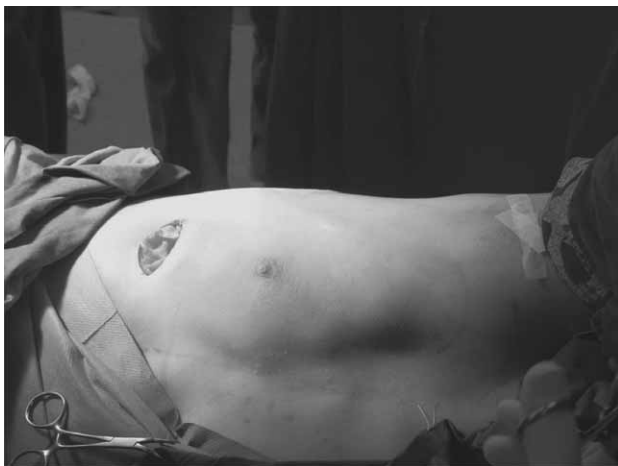

Fig. 2.

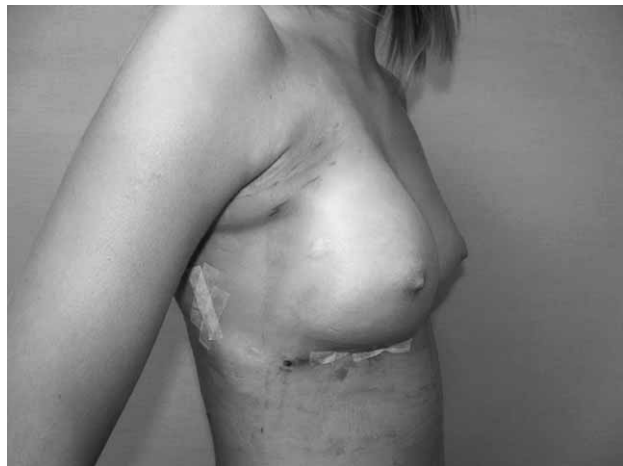

Fig. 5.

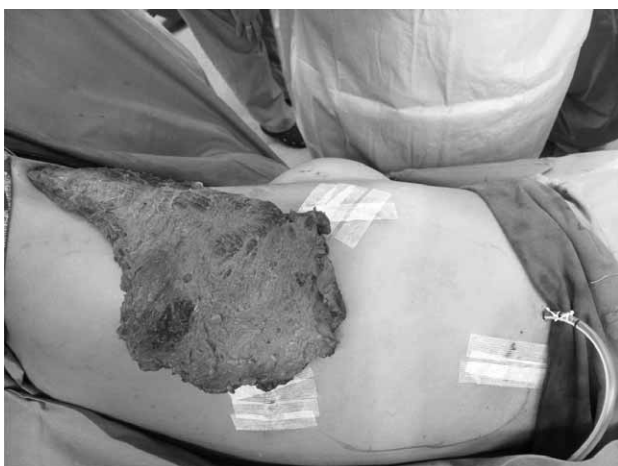

Fig. 3.

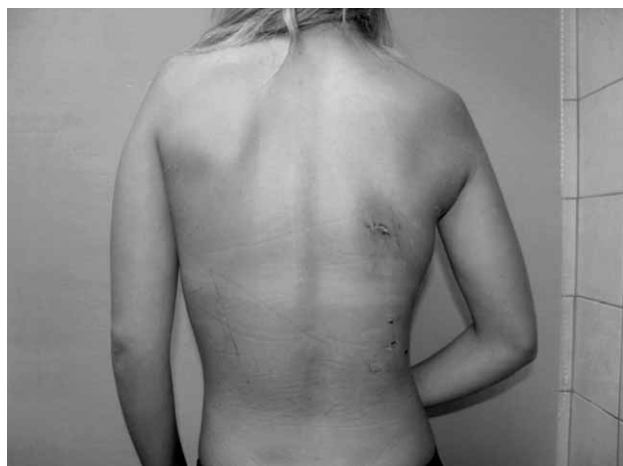

Fig. 6.

patient was placed on left lateral decubitus position and draped.

Incision was made through submammary scar of right breast and expander was removed (Figure 2).

A 5-cm axillary incision was created. Dissection was carried down through subcutaneous tissues until the anterior edge of the latissimus dorsi muscle was seen. Anteriorly, a plane was created endoscopically between the breast fascia and the chest wall. Three more incisions were made, all 2.5 cm wide, first under inferior angle of scapula, second in the middle axillary line and the third one on the lower pole of latissimus dorsi muscle (Figure 3).

Subcutaneous dissection over the latissimus dorsi muscle was then performed endoscopically. The thoracodorsal and serratus neurovascular bundles were identified and preserved. We re-created the deltopectoral fold by rotating the muscle anteriorly and its insertion reattached to the humeral fascia with simple interrupted suture. Next, the aponeurotic edge of the muscle was rotated and sutured to the lateral edge of the sternum. A

225 gr Natrelle 410 MF implant was then placed beneath the transferred latissimus dorsi. Two drains were placed in the back and under implant.

We managed to recover breast symmetry by improving submammary and deltopectoral folds with LS muscle and with implant to fill in emptiness of upper pole (Figure 4, Figure 5).

Discussion and Conclusion

Repair of the breast aplasia in Poland syndrome gives the best results in combination of latissimus dorsi flap with anatomic implant. The latissimus dorsi dissection in this procedure was found to be arduous and time-consuming. The anterior submuscular dissection was easily performed, but it was difficult to identify and maintain the proper subcutaneous latissimus dorsi fascia dissection plane. Still aesthetic result is superb comparing to a long scar on back in usual latissimus dorsi harvesting (Figure 6).

REFERENCES

1. COCHRAN JH JR, PAULY TJ, EDSTROM LE, DIBBELL DG, Ann Plast Surg, 6(5) (1981) 402. — 2. LONGAKER MT, GLAT PM, COLEN LB, SIEBERT JW, Plast Reconstr Surg, 99(2) (1997) 429. — 3. FOKIN A, ROBICSEK F, Ann Thorac Surg, 74(6) (2002) 2218. — 4. MOELLEKEN BRW, MATHES SA, CHANG N, Surg Clin North Am, 69 (1989) 977. — 5.

DATTA D, KINGSTON JE, J Hand Surg, 19B(5) (1994) 659. — 6. SHAMBERGER RC, WELCH KJ, UPTON J, J Pediatr Surg, 24 (1989) 760. — 7. MESTAK J, ZADOROZNA M, ČAKRTOVA M, Acta Chir Plast, 33 (1991) 137.

Z. Veir

University of Zagreb, Zagreb University Hospital Center, Department of Plastic and Reconstructive and Breast Surgery, Kišpatićeva 12, 10 000 Zagreb, Croatia
e-mail: veir.zoran@gmail.com

REKONSTRUCIJA DOJKE KOD PACIJENTICE SA POLANDOVIM SINDROMOM SA ENDOSKOPSKI ASISTIRANO PODIGNUTIM LATISSIMUS DORSI REŽNJEM

SAŽETAK

Opisujemo drugu fazu rekonstrukcije dojke kod mlade djevojke koja pati od prirodene aplazije desne dojke te te desnog velikog i malog pektoralnog mišića u sklopu Polandovog sindroma. Povoljan estetski rezultat postignut je kombiniranom rekonstrukcijom dojke autolognim tkivom (*latissimus dorsi* režanj) i silikonskom protezom. Ukupno bolji estetski dojam postignut je endoskopski asistiranim podizanjem režnja širokog leđnog mišića u smislu estetski povoljnijih manjih ožiljaka davajuće regije od klasičnog načina.