

Intercondylar Distances of the Human Temporomandibular Joints

Biserka Lazić¹, Berislav Tepavčević², Jadranka Keros³, Dragutin Komar¹, Tonči Staničić⁴ and Zoran Azinović⁴

¹ Department of Prosthodontics, School of Dental Medicine, University of Zagreb, Zagreb, Croatia

² Private Dental Practice, Zagreb, Croatia

³ Department of Dental Anthropology, School of Dental Medicine, University of Zagreb, Zagreb, Croatia

⁴ Department of Dental Pathology, School of Dental Medicine, University of Zagreb, Zagreb, Croatia.

ABSTRACT

In a sample which included subjects of the Croatian population we made measurements of intercondylar distances between the temporomandibular joints in radiographs. A total of 101 subjects of both sexes ranging in age from 20 to 80 years, mostly residents in Zagreb, were evaluated. We measured the intercondylar distances from the condyle centers in the postero-anterior cranial radiographs which had previously been examined and traced on acetate paper. The measuring points were digitized prior to measurements. A special system of coordinates was devised for each radiograph. The results of our measurements were assessed by ANOVA analysis. The intercondylar distance between the two temporomandibular joints was within the range of 110 and 145 mm, with the mean of 126 mm. In men the intercondylar distance was within the range of 116 and 145 mm, with the mean of 130.2 mm. In women the distance ranged from 110 to 138 mm, with the mean of 123.5 mm. There was a significant difference between the two sexes. From a review of the literature, it is apparent that the results of our measurements do not support the results of similar studies assessed by a number of researchers in other countries. The intercondylar distance in the Croatian sample was 5.25% larger than the maximal values of the same parameters in other populations suggesting larger craniofacial skeletons. The development of this radiographic assessment method should improve evaluation of subjects seeking treatment.

Key words: temporomandibular joints, intercondylar distance, radiographic analysis, cephalometric analysis, temporomandibular dysfunction

Introduction

Each condyle is inclined at an angle of approximately 10° with regard to the line which crosses the centers of both condyles. The medial pole of the condyle is higher than the lateral pole thus forming an angle of 10 to 15 degrees to a horizontal line in the frontal plane. The lateral view of the condyle shows that the condyle is convex, and well rounded¹⁻⁷. It is covered by connective and cartilaginous tissue. Space investigations have suggested that if the condyle has a hinge axis, it is convex. It is also positioned in a deep concave fossa. Some investigators believe that if lateral movements prevail, the anterior surface becomes flat again and so does the associated fossa. The posterior surface of the condyle is flatter than the anterior surface. It is triangular in shape and it is not covered by cartilage⁷⁻¹⁵. According to Tylman¹⁵ 75% of the condylar surface has a convex shape, while 25% of pa-

tients exhibit either a slightly flattened or a completely flat condyle. Toshikatsu¹⁶ reported three shapes of the lateral view of the condyle: reniform (39.2%), elliptical (38.3%) and trapezoidal (18.3%).

There is an association between the condylar shape and the Angle's classification. After measuring the intercondylar distance between the lateral poles of the condyles, which is the largest distance, the significant differences were observed between the subjects with an Angle class II occlusion versus subjects with Angle class III. The distance from the posterior contour of the condyle and the anterior wall of the auditory canal were also different. Such findings suggest that smaller intercondylar distances are to be found in subjects of Angle class III than in those with normal occlusion. In addition, the condyle of Angle class III subjects is positioned more an-

teriorly with regard to the osseous part of the external auditory canal.

Such a shape of the temporomandibular joints enables the performance of either symmetrical mandibular movements (depression, elevation, protrusion, retrusion) or non-symmetrical (lateral) movements.

From a review of the literature it is apparent that there is a considerable lack of all-inclusive information on the reliability of the identification of some points that are so relevant to submentovertex cephalometrics (SMV) in order to establish the condyle angles. Submentovertex is a reference point at the base of skull used in preparing radiographic projections of the skull and its associated structures. The establishment of the condylar axis and measurement of the horizontal inclination is subject to numerous errors. They partly occur due to different condylar shapes which were described by Oberg and co-workers as rectangular, round towards oval, and pear shaped with medial and lateral parts that have become thin.

Krenkel and Grunert¹⁸ radiologically examined 126 patients. They assessed 126 SMV radiographs. They found great differences in condyle shapes which they attributed to changes that had occurred in the course of film processing. They reported that different condyle shapes could pose problems in an attempt of identification as well as in the definition of the longitudinal axis.

The longitudinal axis was defined by a straight line which joined the medial and lateral poles. Some other researchers have defined the longitudinal axis by means of a visual control of the condyle in axial position. These techniques have proved to be inadequate due to their apparent limitations. For example, the rounded condyles and the lines which joined the poles significantly deviated either from the central condylar point or from the thinned parts on the medial and lateral deviations which were distant from the longitudinal axis. In addition the condylar poles, particularly the lateral ones, could not be easily identified by means of SMV projections due to their superior position.

Williamson and coworkers¹⁹ studied the errors on certain SMV values (confidence limits). In their experiment, they employed 3 different methods in order to determine both the longitudinal axis and the condylar inclination on the SMV radiographs.

The selected points were relevant to definition of the sagittal, transverse, and angular positions of the mandibular condyle in regard to the cranial base in the same approach as it had already been defined and recognized on the SMV radiographs.

The aim of the study was to develop method for improving evaluation of subject seeking treatment.

Materials and Methods

In order to make a radiographical diagnosis of the temporomandibular joints the following criteria must be satisfied:

- Knowledge of different articular structures as visualized on the x-ray images depending on the different planes.
- Diagnostic recognition of the condylar region as well as that of the articular eminence and its adjacent structures.
- Encircling of all the structures on the x-ray image so that the values can be numerically calculated. The condylar region is restricted by the space below, in front of, and behind the condyle in the articular fossa at centric occlusion^{20–23}.

Subjects

The intercondylar distances, calculated by measuring the distances from the condyle centres, were studied in a sample of 101 subjects from 20 to 80 years of age. 43 men ranged in age from 26 to 80 and 58 women from 20 to 80. All the subjects were asymptomatic with regard to their temporomandibular joints, but had to be radiologically examined for specific diagnostic analyses procedures of the skull and its associated structures.

Radiographs of the patients' skulls were made using a postero-anterior plane (projection). The patients were lying in a prone position with their arms under the chest and their heads pulled towards the chest. The static images of the temporomandibular joints were made in the maximally opened mouth position. At the same time, the line between the angle of the eye and the tragus was perpendicular to the film.

The central ray was inclined at the angle of 30° cranially thus entering the great occipital foramen and coming out at the inferior rim of the orbit. All the images were made with the same device and exposed in the same radiographic cabinet using the Axial Tome # 5000 X-ray machine (Axial Tome Corp. San Carlos, California, USA). The x-ray apparatus was operated at 80 KV with a constant current of 15 mA and the exposure time of 2 seconds.

Standard protocol for examining radiographs was followed.

Radiographic analysis

Radiographs were traced (0.3 mm) on acetate paper. The measuring points were digitized by means of the Summasketch II digitizer (Summagraphics Corp. Austin, Texas, USA) interfaced with the personal computer. Microsoft Visual Basic for Windows (Microsoft Corp. Washington DC, USA) software was used.

An individual approach was taken to treating images so that a customized system of coordinates was devised for each image. First, the two points of reference, which were positioned at a standardized place on the upper left-hand as well as on the right-hand corner of each image, were established. By joining the two points of reference on every image an axis was developed which subsequently became the axis of the Cartesian System on every image. Simultaneously, the x-axis was adjusted to the previously established x-axis of the digitizer. In this

way, the two lines could run parallel to each other. The upper left-hand point of reference was considered to be the beginning of the y-axis. Prior to this, a line, which was perpendicular to the plane that joined the two points of reference, had been considered to be the y-axis. The distance from the condyle centre, the intercondylar distance, was measured and subsequently numerically calculated for every image. Confidence limits were checked by three investigators. They had to track a certain number of randomly selected x-ray images on acetate paper using a pencil. They repeated a procedure 5 times within 24 hours. Subsequently, every image was digitized by the same researcher. The difficulty of standardizing the position of the head leads to projection errors on the x-ray images was then calculated. Errors were assessed by calculating standard deviations (SD) for every image. Moreover, standard deviations were calculated for all the images. The results of the study were assessed by ANOVA analysis. The error of the method was numerically calculated by one of the investigators using a continual digitalization of the point 0.2 mm in diameter on the acetate paper.

Results and Discussion

For the cranial segment of the arch, the distance between the osseous condylar structures and the medial plane is within the range of 5 to 7.5 mm measured from the lateral pole of the condyle. Radiological visualization of either the articular fossa or the articular eminence depends on the selection of dorsal and cranial planes. The larger the angle for the cranial plane, and the smaller the angle for the dorsal plane, the greater the radii in the articular fossa and in the articular eminence will be. The span between the articular fossa and the articular eminence corresponds to one third of the distance of the joint when measured laterally. It also corresponds to the sagittal depth of approximately 7.5 mm measured from the lateral rim of the zygomatic process on the temporal bone.

At low angular values in the cranial plane, a shadow shaped like a sickle appears in the articular fossa. The shadow is positioned more cranioposteriorly at low dorsal values but it changes its position more anteriorly at high dorsal values^{23–26}.

Despite different visualizations, which depend on the plane of the articular fossa, the plane of the articular eminence as well as on the plane of the condyle, the quotients of the anterior width of the articular region with regard to the posterior width remain almost unchanged. This suggests that these parts of the temporomandibular joint are equally liable to changes. On the other hand, the relationships between the various parameters and ratios of the distances (spans) remain unchanged.

The sagittal discrepancy of the condylar cross-section is best defined on the x-ray image. It is not distorted, and can be easily recognized on the image if the enlargement, caused by the plane included in the relation target – focus – film – object, is negligibly small.

The vertical discrepancies are visualized in a reduced size, which is the result of the cosine of the angle of the cranial plane that has been used. The transverse discrepancy of the condyle is visualized as a vertical discrepancy, which is either enlarged or reduced in size when the oblique lateral plane is used. There is only one difference between the transverse discrepancy and the vertical discrepancy. The former employs a more adequate procedure whereas the latter does not. If there is a medial discrepancy of the condyle, it is visualized on the image as an enlargement of the articular space. The lateral discrepancy of the condyle is visualized as a reduction of the articular space. The relationship between the condyle and the articular fossa is not distorted with regard to the borders of the anterior condylar rim. The transverse discrepancy caused by occlusion poses some diagnostic problems but this is irrelevant to measurement of the intercondylar distance since it always remains unchanged^{26–28}.

In a dorsocaudal discrepancy, the condyle cannot be positioned more anteriorly or posteriorly due to technical problems (deficiencies of the apparatus).

The results of the measurements of the intercondylar distance in a part of the included subjects of both sexes are presented in Table 1 and Figure 1.

TABLE 1
DESCRIPTIVE STATISTICAL PARAMETERS OF
INTERCONDYLAR DISTANCE (mm)

Sex	Age	No.	X mm	SD	Min–Max
M	26–80	43	130,2	0,8094	116–145
F	20–80	58	123,5	0,5246	110–138
Total	20–80	101	126,3	0,7383	110–145

It is apparent that the intercondylar distance was within the range of 110.0 mm to 145.0 mm, the mean being 126.3 mm. Standard error of the arithmetic mean was 0.1, standard deviation was 0.7, and variability coefficient was 5.8. The intercondylar distance in men was within the range of 116.0 mm to 145.0 mm, with the mean of 130.0 mm. Standard error of the arithmetic mean was 0.12, standard deviation was 0.8 and variability coefficient was 6.2. In women the intercondylar distance was within the range of 110.0 mm to 138.0 mm, with the mean of 123.5 mm. Standard error of the arithmetic mean was 0.1, standard deviation was 0.52 and variability coefficient was 4.3.

The results of this study reveal that the examined groups were homogenous. They also show that the measurements were made accurately. The value of the variability coefficient is relatively low (6.2% in male subjects and 4.2% in female subjects). Assuming that our sample was a substantial representative of a part of the Croatian population, the mean values are within the range of 127.0 mm to 133.4 mm in men, 120.7 mm to 125.3 mm in women, respectively. The assessments were made at the probability rate of 95%.

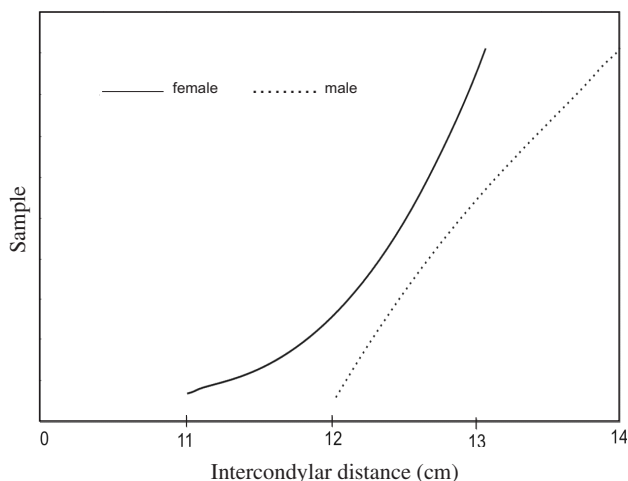


Fig. 1. Intercondylar distance according to gender in the overall sample.

Due to the large size of the sample even distributions of the sample can lay the foundation for further radiologic and cephalometric examinations of the Croatian population.

Conclusion

There is one question that arises from our discussion: Why were the intercondylar distances measured from

the condyle rotation centre instead from the exterior pole? Evaluating the sagittal cross-section may give the impression that it is easy to establish the centre of the condyle. However, the condyle is not round in shape. It is cylindrical so it is more difficult to establish its centre. The anthropologists, unlike the prosthodontists, measure the intercondylar distance from the exterior pole of the condyle in order to determine more precisely the border of an x-ray image. According to Saler²⁸, the mean value of the bicondylar width of the mandible is in caucasians 120 mm, in Caucasians, the intercondylar distance being within the range of 90 mm to 140 mm.

When studying the intercondylar distance, we have to distinguish between the centre of condylar rotation and the centre of mandibular rotation. In geometry, the centre of rotation can be found only in the sphere. Unlike spheres, condyles are not round but ellipsoid so that the centre is not a real centre of the condyle but a geometric intersection of the longest condylar axis with the shortest one. Yet, what is most essential for the purpose of the study is that the point is suitable for measuring the intercondylar distance^{29–32}.

The results of our study are not supported by results of other studies. From a review of the literature it is apparent that the mean values of the intercondylar distances, typical of residents in Zagreb, are by 5.25% bigger than those obtained by other researchers worldwide. This suggests that subjects of Zagreb have larger or broader craniofacial skeletons.

REFERENCES

- KRIŽAN, Z.: Pregled glave, vrata i leđa. (Školska knjiga, Zagreb, 1978) — 2. WILLIAMS, P. L., R. WARWICK, M. DYSON, L. H. BANNISTER: Gray's Anatomy. (Churchill Livingstone, Edinburgh, 1989). — 3. MCMINN, R. M. H.: Last's Anatomy, Regional and Applied. (Churchill Livingstone, New York, 1990). — 4. MOORE, K. K.: Clinical Oriented Anatomy. (Williams and Wilkins, Baltimore, 1992). — 5. PANSKY, B.: Gross Anatomy. (McGraw-Hill, New York, St. Louis, 1996). — 6. HJORSTJO, C. H., Fortschr. Kiefer Gesichtschir., 9 (1960) 16. — 7. HJORSTJO, C. H., Acta Univ. Lund., 2 (1964) 24. — 8. KYDOL, W. L., A. SANDER, Dent. Res., 40 (1961) 3. — 9. MONGINI, F.: Min. Stom., 17 (1968) 814. — 10. PREISKEL, H., Brit. Dent. J., 129 (1970) 372. — 11. KEROS-NAGLIĆ, J., Z. KAIĆ, O. MUFTIĆ, Coll. Antropol., 5 (1981) 201. — 12. MATSUMOTO, M. A., Brit. Dent. J., 5 (1994) 115. — 13. JEROLIMOV, V., P. KOBLER, J. KEROS, T. STANIČIĆ, I. BAGIĆ, Coll. Antropol., 22 (1998) 169. — 14. ŽABAROVIĆ, D., V. JEROLIMOV, V. CAREK, D. VOJVODIĆ, K. ŽABAROVIĆ, D. BUKOVIĆ, Coll. Antropol., 24 (2000) 37. — 15. TYLMAN, S. D.: Theory and Practice of Crown and Fixed Partial Prosthodontics. (Mosby, St. Louis, 1970). — 16. TOSHIKATS, M. A., Nih. Univ., 1 (1980) 22. — 17. OBERG, T., G. E. CARLSSON, C. M. FAJERS, Acta Odontol. Scand., 29 (1971) 349. — 18. KRENKEL, C., I. GRUNERT, Oral Rehabil., 16 (1998) 417. — 19. WILLIAMSON, E. H., C. W. WILSON, Am. J. Orthod., 70 (1976) 200. — 20. CRAWFORD, S. D.: Angle Orthod., 69 (1999) 15. — 21. BRAUN, S., J. S. HICKEN, Angle Orthod., 70 (2000) 383. — 22. BENSON, B. W., N. L. FREDERIKSEN, Oral Surg. Oral Med. Oral Pathol. Oral Radiol. and Endod., 86 (1998) 360. — 23. GALLO, L. M., K. FUSHIMA, S. PALLA, J. Dent. Res., 79 (2000) 1566. — 24. LEWIS, R. P., Am. J. Orthod. Dentofac. Orthop., 120 (2000) 294. — 25. WILLIAMSON, P. C., P. W. MAJOR, B. NERBBE, K. E. GLOVER, Oral Surg. Oral Med. Oral Pathol. Oral Radiol. and Endod., 86 (1998) 360. — 26. GIESEN, E. B., T. M. VAN EIJDEN, J. Dent. Res., 79 (2000) 957. — 27. THUROV, R. C., Am. J. Orthod. Dentofac. Orthop., 117 (2000) 298. — 28. SALLER, K., Leftenden der Anthropologie. (G. Fisher, Stuttgart, 1964). — 29. AULL, A. E., J. Prosth. Dent., 13 (1963) 469. — 30. BROTMAN, D. N., J. Prosth. Dent., 10 (1960) 436. — 31. HATCHER, D. C., Maxillofacial imaging. In: MCNEILL, C. (Ed.): Science and Practice of Occlusion. (Quintessence Publishing Co., Chicago, 1997). — 32. MAKI, K., T. OKANO, T. MOROHASHI, S. YAMADA, Y. SHIBASAKI, J. Dent. Maxillofac. Radiol., 26 (1997) 39.

B. Lazić

Department of Prosthodontics, School of Dental Medicine, University of Zagreb, Gundulićeva 5, 10000 Zagreb, Croatia
e-mail: lazic@sfgz.hr

RASPON CENTARA KONDILA ČELJUSNOG ZGLOBA

SAŽETAK

Poznavanje standardnih dimenzija i parametara donje čeljusti, posebice morfometrijskih značajki čeljusnih zglobova, izuzetno je značajno u antropologiji, paleontologiji i sudskoj medicini, ali i u svim granama stomatologije, posebice protetici, ortodontici i kirurgiji. Nedostatak morfometrijskih izmjera za neke parametre u našoj populaciji ponukao nas je da na većem broju rendgenograma načinimo mjerenja raspona kondila čeljusnih zglobova. Uzorak je činio 101 ispitanik obaju spolova od 20 do 80 godina. Ova su mjerenja rađena na postero-anteriornim snimkama glave koje su pregledane i precrtane, a mjerne točke digitalizirane. Izrađen je poseban sustav koordinata za svaku radiografsku snimku. Međukondilarna je udaljenost čeljusnog zgloba 110 mm do 145 mm uz prosječnu vrijednost od 126,3 mm. U muškaraca su te vrijednosti 116 do 145 mm s prosjekom od 130,2 mm, a u žena 110 mm do 138 mm s prosjekom 123,5 mm. Uočljive su razlike u odnosu na spol, a rezultati našeg mjerenja pokazuju da je u našoj populaciji interkondilarni raspon za 5,25% veći od maksimalne vrijednosti u recentnoj literaturi.