

TEMPOROMANDIBULAR JOINT DEVELOPMENT AND FUNCTIONAL DISORDERS RELATED TO CLINICAL OTOLOGIC SYMPTOMATOLOGY

Tomislav Badel¹, Ivana Savić-Pavičin², Dijana Zadavec³, Miljenko Marotti³, Ivan Krolo³ and Đurđica Grbeša⁴

¹Department of Prosthodontics, ²Department of Dental Anthropology, School of Dental Medicine, University of Zagreb; ³Department of Diagnostic and Interventional Radiology, Sestre milosrdnice University Hospital Center;

⁴Department of Histology and Embryology, School of Medicine, University of Zagreb, Zagreb, Croatia

SUMMARY – Temporomandibular disorders (TMDs) are a form of musculoskeletal pain of the temporomandibular joint (TMJ) and/or masticatory muscles of nonspecific etiology. In this study, the relationship between embryonic and anatomic-topographic similarities of the TMJ and the ear was analyzed, i.e. secondary otologic symptoms that can be closely connected to TMJ disorder. Nonspecific otologic symptoms are not primary diagnostic symptoms of TMD, but may cause diagnostic confusion due to patients' inability to correctly locate the origin of pain. The most common otologic symptoms that can be related to TMDs are otalgia, tinnitus and vertigo. Otorhinolaryngologists have to differentiate between primary otologic symptoms and those caused by TMJ disorders. In TMD diagnosis, manual techniques are used to determine the arthrogeenic or myogenic form, whereas in the diagnosis of arthrogeenic disorders magnetic resonance imaging is indicated as the highly specific imaging method of joint disk and osteoarthritic changes. Symptomatic treatments for TMD as well as the etiologic diagnosis of the pain require multidisciplinary cooperation between dentists and medical specialists.

Key words: *Temporomandibular joint disorders; Earache; Tinnitus; Magnetic resonance imaging; Diagnosis, differential*

Temporomandibular Disorders

Functional disorders including pain in the temporomandibular joint (TMJ) and/or masticatory muscles, pathologic sounds in TMJ and limited mouth opening are all called temporomandibular disorders (TMDs). Although they are major diagnostic symptoms, TMDs are not classified as a syndrome. Besides the ones mentioned, accompanying nonspecific otologic symptoms and tension-type headaches may also occur, thus definitive diagnosis cannot be given¹⁻³. The

prevalence of clinical symptoms in adult population is from 12% to 42.7% and the need for treatment from 3% to 9%⁴⁻⁶.

TMDs are musculoskeletal disorders, which can be difficult to locate for patients, especially in an earlier stage. TMDs belong to a group of myogenic (tendomyopathies of masticatory muscles) and arthrogeenic (discopathy, osteoarthritis of TMJ) disorders. Untreated acute pain can evolve into a chronic form and become a separate illness. Psychosocial factors, as in other musculoskeletal disorders, have a dominant role and therefore the clinical and radiological findings tend to be disproportionate to the symptoms⁷⁻¹¹.

The aim of this study was to analyze the interrelationship of otologic symptoms and TMD symptoms

Correspondence to: *Tomislav Badel, PhD*, Department of Prosthodontics, School of Dental Medicine, University of Zagreb, Gundulićeva 5, HR-10000 Zagreb, Croatia
E-mail: badel@sfzg.hr

Received March 10, 2011, accepted May 3, 2011

based on embryonic development and morphological similarities of the ear and TMJ.

Temporomandibular Joint and Review of the Disorders

TMJ is a synovial joint; in fact, there are two of them, one on each side, and it is the only one connecting temporal bone with the mandible. It is a ginglymoid joint because of its ability to rotate, and also an arthrodial one because of its gliding movements. Other characteristics of TMJ are fibrous-cartilaginous joint surfaces separated by articular disk and two-sided simultaneous articulation, while the position and movements of the joint depend on occlusal relations between dental arches¹².

Studies of TMDs were initiated by J. B. Costen, an English otorhinolaryngologist, who in 1934 started describing clinical cases of patients with heterogeneous otologic symptoms and connected them to distal tooth loss (denture support zones). Costen's syndrome is a mechanistic theory in which the cause of pain is dorsocranial condylar displacement with compression of the auriculotemporal nerve⁸. Afterwards, there was another theory focusing on the non-centric, i.e. non-physiologic position of the condyle within the articular fossa, and on occlusal disorder (tooth loss) based on the analysis of TMJ radiological images (Fig. 1). These views used to be the fundamentals of dental prosthodontics and prosthodontic treatment planning¹³.

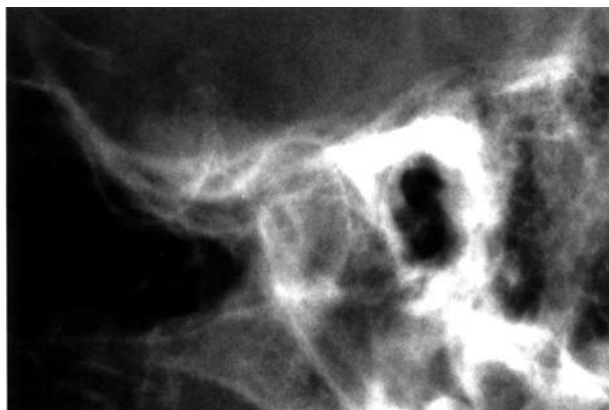


Fig. 1. Transcranial eccentric image of the temporomandibular joint in closed mouth position.

Evolutionary Development of the Temporomandibular Joint

TMJs of anthropomorphous apes are distinctively flat; the articular fossa is wide and shallow, while the articular eminence is wide and low. The fossil remains of hominids show a differentiated morphology of the TMJ, as a reflection of the continuing process of adjustment to living conditions and functional demands of the stomatognathic system¹⁴.

Reduction of the frontal area of the stomatognathic system, which was conditioned by evolutionary development, consequently brought changes to the form and function of certain parts of it. A balanced position of the cranium on the spinal column during upright walk was achieved by anterior reduction of the structures of the masticatory system. A typical feature of human evolution is the connection between the development of articular eminence and the combined rotational-translational movements in TMJ. A developed and pronounced articular eminence prevents condylar luxation on mouth opening because the completely rotational movement is replaced by a sliding movement due to spatial reduction in this area of cranial base, the retromandibular space^{15,16}.

Embryonic Development of the Temporomandibular Joint

Upper and lower jaw bones as well as temporal bones derive from the mesenchyme developing from neural crest cells during the fourth week of embryonic development. Out of this mesenchyme, pharyngeal arches develop in the head and neck area and they participate in facial development. After 4-5 weeks of development, the stomodeum is surrounded by an even numbered mandibular process (ventral part of the first pharyngeal arch), even numbered maxillary process (dorsal part of the first pharyngeal arch), and by a frontal process from above^{17,18}.

In the mandibular process, Meckel's cartilage is formed. The tympanic and mandibular process of Meckel's cartilage is completely developed in the 16th week of embryonic development. The thickened posterior ending of the tympanic cartilage is the primordial cartilage called the malleus. Malleus is in direct contact with the primordial cartilage called the incus by means of a flat articulation plane. From the 8th until the 16th week of development, the primordial car-

tilages function as the primary temporomandibular or malleoincudal joint; auditory ossicles develop from the latter. This joint can perform only simple rotation or buccal movements, which appear in the 8th week of development. All these movements are important for the development of condylar cartilage. Later, the malleus is separated from Meckel's cartilage and ossified to become the middle ear ossicle¹⁹.

Meckel's cartilage is important for the topographic organization and differentiation of the facial structures during embryonic and fetal development. The mandibular primary growth center starts developing from the 12th week in the mandibular process of Meckel's cartilage. It has a morphogenetic role in lower jaw development because it marks the beginning of the intramembranous ossification of the mandible. The volume of Meckel's cartilage decreases after the 18th week and later it disappears during mandibular ossification. Meckel's cartilage is replaced by the body of the mandible and secondary condylar cartilage. A characteristic of mandibular development is bone derivation from the mesenchyme by intramembranous

ossification laterally from Meckel's cartilage, while the development of carrot-shaped condylar cartilage is placed posteriorly²⁰.

TMJ development takes place mostly between the 7th and 20th week of intrauterine life and a particularly sensitive period is morphogenesis between the 7th and 11th week (Fig. 2). A particular feature of TMJ development compared to other joints in the human body is mutual approximation of the initial condylar and temporal base (blastema). There are three stages in TMJ development: blastemic stage (7th-8th week; development of the condyles, articular fossa, articular disk and capsule), cavitation (9th-11th week; beginning of lower joint space development and condylar chondrogenesis), and maturation stage (after the 12th week)^{21,22}.

The tiny eminences on the ascending ramus of the mandible are the bases of the condylar and the coronoid processes. In the 9th week, chondrogenesis begins from the mesenchyme cells, laterally from Meckel's cartilage, in the middle of the condylar blastema. In the 10th week, the condylar head and the entire coni-

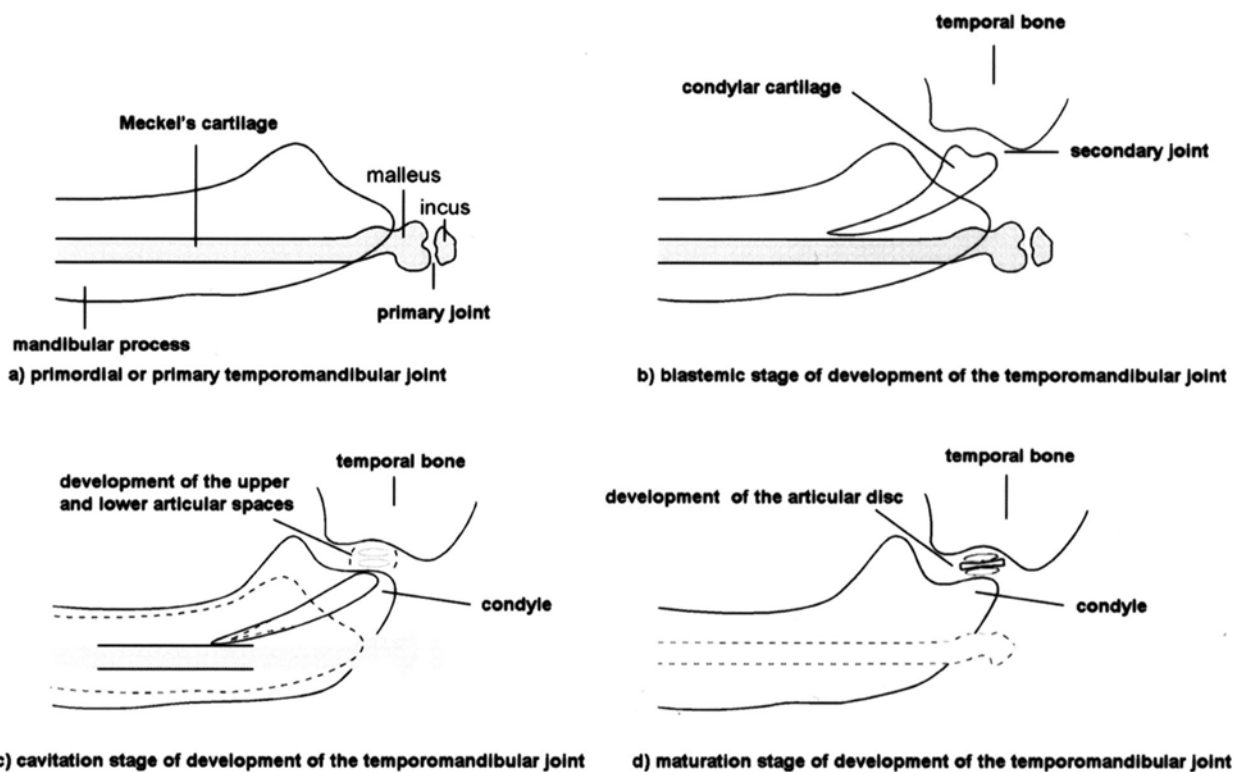


Fig. 2. Stages of embryonic development of the temporomandibular joint: schematic diagram.

cal condyle are apically surrounded by the lower jaw body, which is ossified intramembraneously. Enchondral ossification of the condylar cartilage in the anterior part begins in the 17th week and after the 20th week the cartilaginous form of the condyle is present only on the surface²¹⁻²³.

The existence of temporal bone is visible from the 8th and 9th week. It is situated above the most distal part of Meckel's cartilage and above the base of the malleus and incus auditory ossicles. During the 8th week, the zygomatic process of the temporal bone is ossified. In the 10th week, there is medial thickening of the disk with mildly pronounced concave contours. In the period of the 11th and 12th week, the articular fossa can be concave, convex or completely flat. The articular fossa spreads cranially from the condyle in anterior direction and from the 12th week it has a concave shape. The extension of the articular eminence and postglenoid process appears after the 26th week^{18,21-23}.

After the 7th week, mesenchymal thickening is visible, positioned cranio-laterally from the future condyle, out of which the articular disk develops. Due to the forming of articular spaces, the articular disk is thinner in the middle section, which later creates a characteristic biconcave shape. From the 12th week, it is in its permanent position between the temporal bone and the condyle. Its cartilaginous structure is clearly visible between the 15th and 20th week²².

The mesenchymal development of the articular capsule starts in the 8th week and stretches from the squamous part of the temporal bone towards the articular disk and the condyle. In the 11th week, the capsule is positioned between the zygomatic arch of the temporal bone and the condyle and it is attached to the outer portion of the articular disk^{18,22}.

The upper and lower articular spaces develop from several cracks in the thickened mesenchyme, from which the condyle, the articular disk and the capsule develop. Lower articular space starts developing earlier but slower than the upper one, in the 9th week, and follows the condylar base shape. The upper articular space starts forming in the 11th week between the zygomatic process of the temporal bone and the articular disk. It grows laterally and anteriorly between the 12th and 16th week of development. The articular spaces are disproportionate until the 26th week^{21,22}.

The secondary TMJ is fully developed after the 14th week of intrauterine growth, anteriorly from the otic capsule, and after the 16th week it assumes the primary joint function. The ossified parts of the primary joint (malleus and incus) become part of the middle ear. Only two other rudimentary oto-mandibular ligaments remain to be developed, without functional significance. The disco-malleolar ligament connects the anterior malleolar ligaments and ends in the posterior threads of the articular disk. The malleo-mandibular ligament is a remainder of Meckel's cartilage and it goes through the tympanosquamous fissure^{24,25}.

Otorhinolaryngology and Temporomandibular Disorders

Otorhinolaryngology and dental medicine are related fields and therefore have a complex relationship in TMD diagnosis. One of the reasons for that is the closeness of embryonic ear development and TMJ development. Another reason is their morphological proximity and the intertwining of the innervation field of the shared nerves^{12,26-28}.

Otalgia or ear pain can be an indicator of TMJ disorder if there are no appropriate otoscopic findings. Peroz²⁹ found a statistically significant connection between otalgia and TMD diagnoses. Keersmaekers *et al.*³⁰ found otalgia in as much as 42% of TMD patients. A study by Seedorf and Jüde³¹ showed a 7.1% prevalence of otalgia as the main symptom in a group of patients with TMD. Badel found otalgia in 51.2% of patients with discopathy (articular disk displacement) using magnetic resonance imaging (MRI)³². In patients with TMD, Tuz *et al.*³³ determined a 63% prevalence of otalgia as the most common otologic symptom. Musculoskeletal pain is often difficult to locate and therefore some patients cannot precisely limit the primary source of pain (TMJ area) from the secondary areas where the pain is spreading (ex. the preauricular area, particularly towards the outer auditory tube)³⁴. In the research of the causes of otalgia, there is a significant connection with degenerative disease of the cervical spine (in 88% of patients) as well as a connection with TMDs in 46% of patients³⁵.

Nasal secretion can be related to TMD when there is irritation of the outer ear caused by trigeminal innervation. Frequent use of cotton sticks to clean the ear may cause bacterial superinfection and secretion as a consequence²⁶.

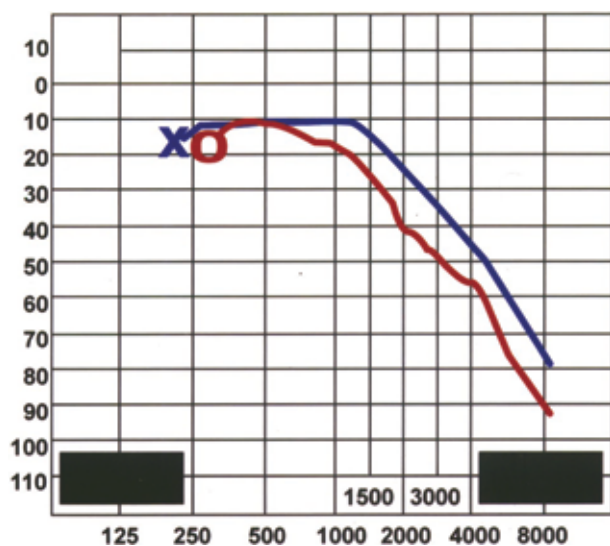


Fig. 3. Pure-tone audiogram: bilateral steep diagram of hearing loss in higher frequencies (X and blue curve stand for the left ear; O and red curve stand for the right ear).

Ear pressure is most often caused by auditory tube dysfunction, i.e. the lack of elevation of tensor muscle of velum palatinum and equalizing of air pressure between the pharynx and the middle ear. Hearing difficulty is a symptom that cannot be closely connected to TMD, possibly as a consequence of mild auditory tube dysfunction and tension of pterygoid muscles^{12,30,36}.

Vertigo is a symptom related to nervous system and vascular disorders as part of a cervical or cervi-

cocranial syndrome, with TMD as an accompanying musculoskeletal disorder³⁷. Tuz *et al.*³³ determined a 50% prevalence of vertigo in patients with TMDs. Vertigo is usually associated with otologic symptomatology, especially its acute manifestations²⁶.

Ear noise or tinnitus cannot be explained by an outside source of the noise. However, objective tinnitus can be explained because the symptoms can be quantified. Noise can spread from the TMJ and the patient primarily feels it in the ear. Tuz *et al.*³³ found tinnitus in 59.1% of patients with TMDs. Bernhardt *et al.*³⁸ determined a statistically significant prevalence of more than two symptoms of TMDs in patients with tinnitus (60%) compared to the control group (36.5%). In the population of patients with TMDs, Upton and Wijskera³⁹ found tinnitus incidence retrospectively in only 7.28%. Ren and Isberg⁴⁰ determined a significant connection between anterior disk displacement and tinnitus in patients with TMJ disorder. Subjective tinnitus is described by patients without the possibility to confirm it; it is usually of unclear etiology (for example, cervicocranial syndrome), but it can also be an accompanying symptom of other ear diseases²⁶.

Differential Diagnosis of Temporomandibular Pain

Techniques of manual examination are used clinically in TMD diagnosis. MRI of TMJs can complement clinical diagnostic findings⁴¹. MRI is a radio-

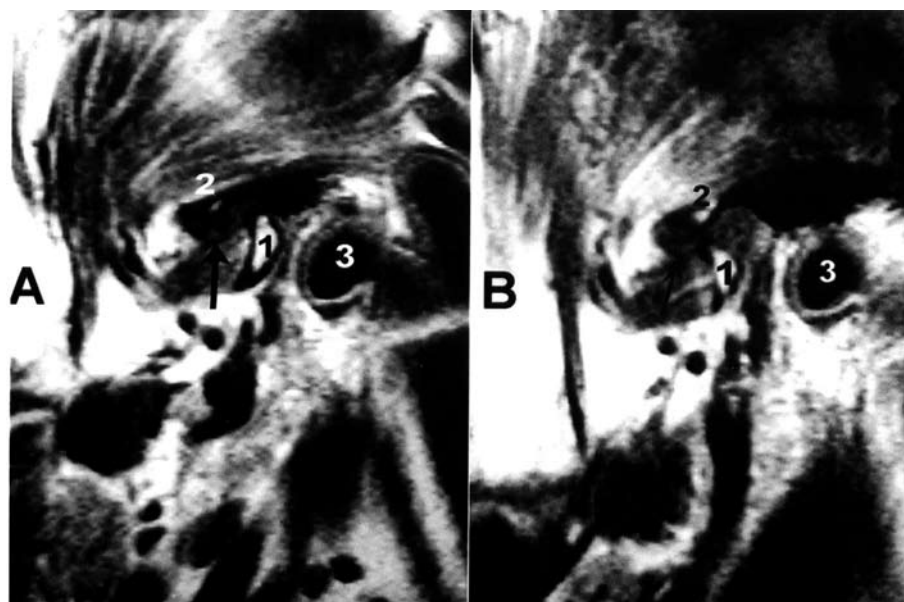


Fig. 4. Magnetic resonance image of the left temporomandibular joint with anterior disk displacement (arrow) in closed (a) and without reduction in open (b) mouth position (1, condyle; 2, articular eminence; 3, external auditory tube).

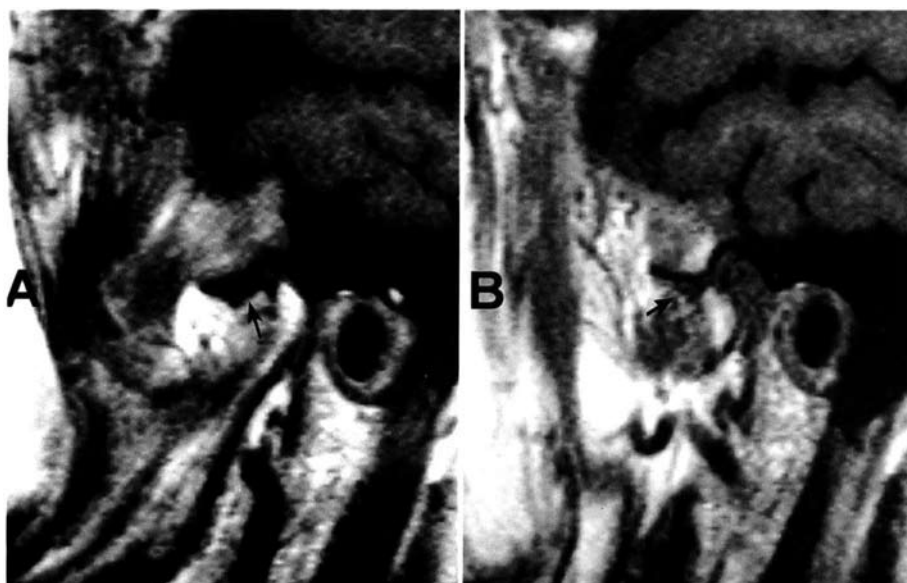


Fig. 5. Magnetic resonance image of the right temporomandibular joint with anterior disk displacement (arrows) and with reduction in closed (a) and open (b) mouth position.

logical diagnostic, high-resolution method without invasive and ionizing effects on the human body, which enables a layered view of hard tissues and, most importantly, soft tissues of intra-articular structures. Anterior disk displacement is the most common TMJ disorder. MRI can also show osteoarthritic changes of osseous structures⁴¹⁻⁴³. In the study of TMD diagnosis and treatment, certain patients showed primarily unrecognized symptoms of TMJ disorder⁴⁴.

Otorhinolaryngologists as well as dentists should recognize clinical signs and symptoms of TMDs in daily practice. An example from the gathered data shows that in a 72-year-old female patient, symp-

toms of acute TMJ disorder were primarily diagnosed by pure-tone audiometry. Although the audiogram showed a steep bilateral hearing loss (Fig. 3), target diagnosis determined an anterior disk displacement in the left TMJ. Displacement without reduction means that in open mouth position, the disk is also placed anteriorly. In addition to discopathy of the left joint, MRI also helped determine osteoarthritic changes of articular planes: deplaning and subchondral sclerosis (Fig. 4). Asymptomatic anterior disk displacement with repositioning (in open mouth position, the disk takes the physiologic position) was found in the right TMJ (Fig. 5).

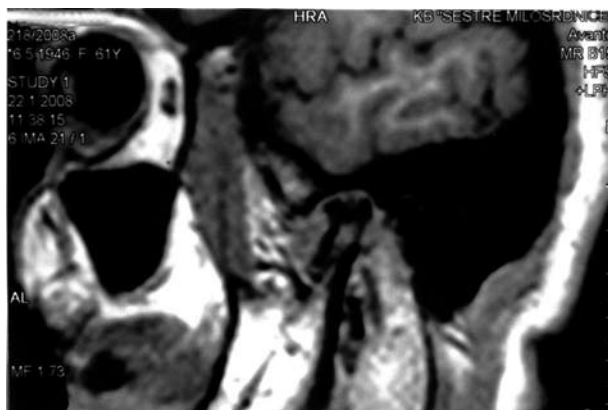


Fig. 6. Magnetic resonance image of the right temporomandibular joint with pronounced pseudocystic changes and loss of condylar head structure.

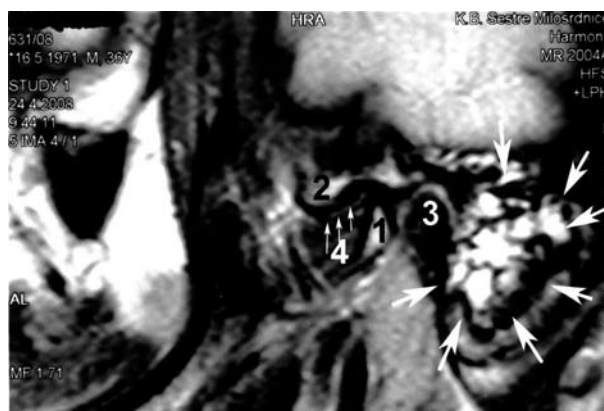


Fig. 7. T2 weighted magnetic resonance image of a temporomandibular joint showing an inflammatory process in the petrous bone region marked by arrows (1, condyle; 2, articular eminence; 3, external auditory tube; 4, articular disk).

MRI as a method of examining TMJs of asymptomatic subjects has shown a relatively high prevalence of anterior disk displacement even in subjects who did not have any symptoms (20%–45% of the examined population)⁴⁵. It is one of the aspects of musculoskeletal disorders, i.e. radiological findings have no significance unless they are supported by previous clinical diagnosis.

Otologic and temporomandibular symptomatology can coexist simultaneously and independently; a retired female patient was suffering from chronic tinnitus due to workplace noise exposure⁴⁶. Because of pain in the right TMJ, she first visited an otorhinolaryngologist and then she was referred to a prosthodontic clinic. MRI determined bilateral osteoarthritis of the TMJs with pronounced pseudocystic changes in the right symptomatic joint (Fig. 6).

However, there is a rare reversed sequence of differential diagnosis wherein timely and targeted diagnosis is important in determining the real cause of pain. A patient who was routinely referred to a dentist by an otorhinolaryngologist was suffering from pain, which could be confounded with a much more serious pathologic process outside TMJ. MRI findings as cofindings in TMJ imaging were useful in discovering the pathologic process in the ear region (Fig. 7).

Radiological imaging of TMJs can also help diagnose sinus mucosal hypertrophy and sinus polyps, but they are usually secondary findings in the dominant symptomatology caused by TMDs (Fig. 8).

In 1937, otorhinolaryngologist W.W. Eagle described the styloid process syndrome (Eagle's syn-

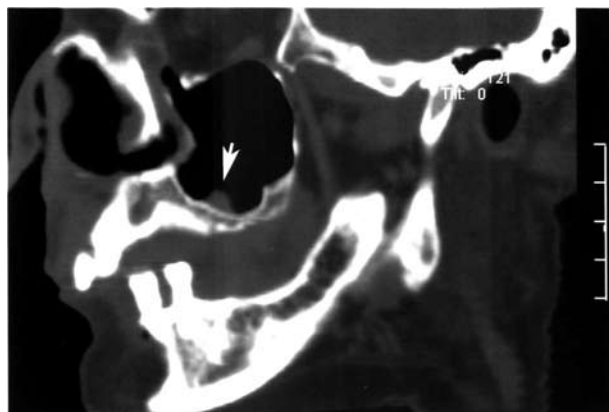


Fig. 8. Computed tomography image of a temporomandibular joint with osteoarthritis and polypoid mucosal thickening (arrow) at the bottom of the maxillary sinus, with appropriate pneumatization and sharp structure of the sinus wall.

drome). Increased length and volume of the styloid process cause cervicofacial pain and swallowing difficulty, which originate under the ear and the retromandibular region. The prevalence of Eagle's syndrome is around 1% because the enlarged styloid process is mostly asymptomatic⁴⁷⁻⁴⁹.

Stylomandibular ligament ossification and enlargement of the styloid process are primarily diagnosed by orthopantomography and they cause nonspecific pain in the wider retromandibular area and the face as well as headache (Fig. 9). Indications and surgery fall into the domain of maxillofacial surgeons.

Treatment of Temporomandibular Disorders

Treatment of TMDs is nonspecific (symptomatic) because causal relationship between the potential etiologic factors has not been determined. Therefore, dental treatments based on unconditional tooth restoration (also known as '32 teeth syndrome') should be avoided. On the contrary, there are more indications for biomedical principles of treatment, which can also be applied to other musculoskeletal disorders^{2,32}.

Pharmacotherapy by nonsteroidal antirheumatics is an accompanying treatment for alleviating acute disturbances. Symptomatic treatment means and methods are the main characteristics of TMD treatment. Dentists are most familiar with occlusal splint fabrication, which is a biomechanical means of neuromuscular function regulation in the stomatognathic system and a kind of orthosis for TMJs^{50,51}.

Physical therapy is also a treatment of choice. Cognitive-behavioral therapy aimed at controlling

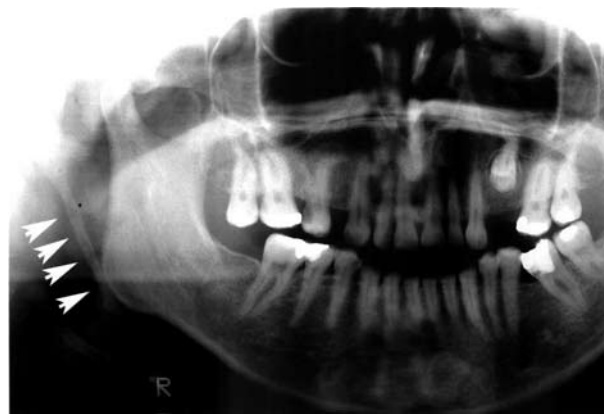

Fig. 9. Elongated styloid process (arrows) shown on an orthopantomogram.

chronic pain intensity is recommended for patients with chronic temporomandibular pain⁵². Namely, initial treatment may be complicated due to worsened psychological condition (stress, anxiety), which makes clinical findings disproportionate to pain intensity⁵³. Due to these reasons, the basic principle of TMD treatment is the use of noninvasive and reversible methods of treatment. Some studies have noted favorable therapeutic effects of TMD treatment on the reduction of otologic symptoms⁵⁴.

Discussion and Conclusion

The term Costen's syndrome as well as the direct cause-and-effect relationship between the auriculotemporal nerve and condylar head should be completely substituted by a modern biomedical perspective of TMDs, which also includes biopsychosocial factors^{55,56}. Green⁵⁷ uses the term idiopathic etiology of TMDs because it is contradictory and multifactorial. In contemporary literature, the relation between prosthodontic treatment and otologic symptomatology is mentioned only sporadically⁵⁸.

Although otologic symptoms are not mainly typical of TMJs, otorhinolaryngologists should consider them because their incidence can be up to 10%. In patients with recurring tinnitus, examination should be focused on both the stomatognathic system and the cervical spine⁵⁹⁻⁶¹.

The difficulty in TMD diagnosis lies in precise localizing of the disturbance, with simultaneous coexistence of other accompanying disturbances in the ear and throat region^{62,63}. Subjective tinnitus is explained by a pathophysiological mechanism, which triggers neuroplastic changes in the sensory pathways and is caused, in case of a TMD, by chronic stimulation of the auriculotemporal nerve⁶⁴.

TMDs should become one of the differential diagnoses in daily medical practice. Some of the patients will be further referred to an otorhinolaryngologist due to otologic symptoms. Even in general dental medicine, these patients should be recognized and treated for TMDs or referred to specialists on time.

References

1. LASKINDM. Temporomandibular disorders: the past, present, and future. *Odontology* 2007;95:10-5.
2. BADEL T, PANDURIĆ J, MAROTTI M, KROLO I. Funkcijski poremećaji u žvačnomu sustavu. *Med Jadertina* 2005;35:81-6.
3. PALLA S. Myoarthropatischer Schmerz: oft verkannt. *Schmerz* 2003;17:425-31.
4. ANDRADE AV, GOMES PF, TEIXEIRA-SALMELA LF. Cervical spine alignment and hyoid bone positioning with temporomandibular disorders. *J Oral Rehabil* 2007;34:767-72.
5. BADEL T, KRALJEVIĆ S, PANDURIĆ J. Kliničko istraživanje poremećaja čeljusnog zgloba u populaciji mlađih muškaraca. *Med Jadertina* 2004;34:15-21.
6. BADEL T, PANDURIĆ J, MAROTTI M. Temporomandibularni poremećaji s aspekta javnoga zdravstva. *Hrvatski časopis za javno zdravstvo (on line journal)* 2006;7 <http://www.hcjz.hr/clanak.php?id=12937>. Accessed: 02 02 2010
7. TANAKA E, DETAMORE MS, MERCURI LG. Degenerative disorders of the temporomandibular joint: etiology, diagnosis, and treatment. *J Dent Res* 2008;87:296-307.
8. TÜRP JC. Temporomandibular pain – clinical presentation and impact. Berlin: Quintessenz-Verlag, 2000.
9. DURHAM J. Temporomandibular disorders (TMD): an overview. *Oral Surg* 2008;1:60-8.
10. van SELMS MK, LOBBEZOO F, VISSCHER CM, NAEIJE M. Myofascial temporomandibular disorder pain, parafunctions and psychological stress. *J Oral Rehabil* 2008;35:45-52.
11. Von KORFF M, MIGLIORETTI DL. A prognostic approach to defining chronic pain. *Pain* 2005;117:304-13.
12. OKESON JP. Management of temporomandibular disorders and occlusion. 5th ed. St. Louis: Mosby, 2003.
13. GERBER A, STEINHARDT G. Kiefergelenkstörungen Diagnostik und Therapie Fachgebiet: Prothetische Zahnheilkunde, Funktionstherapie. 1st ed. Berlin: Quintessenz-Verlag, 1989.
14. HELFGER E-H. Funktionelle Phylogenese des Kiefergelenkes. *Dtsch Zahnärztl Z* 2000;55:563-5.
15. DELAIRE J. L'évolution de la mâchoire inférieure et de l'articulation des mâchoires, des reptiles à l'homme. *Rev Stomatol Chir Maxillofac* 1998;99:3-10.
16. KIESER JA. Basicranial flexion, facial reduction and temporomandibular joint dysfunction. *Med Hypotheses* 1997;49:409-11.
17. SADLER TW. Langman's medical embryology. 11th ed. Philadelphia: Lippincott Williams & Wilkins, 2010.
18. AVERY JK. Development of cartilage and bones of the craniofacial skeleton. In: AVERY JK, editor. Oral development and histology. 3rd ed. Stuttgart-New York: Thieme, 2001:44-59.

19. BONTEMPS C, CANNISTRÀ C, HANNECKE V, MICHEL P, FONZI L, BARBET JP. The first appearance of Meckel's cartilage in the fetus. *Bull Group Int Rech Sci Stomatol Odontol* 2001;43:94-9.
20. LEE SK, KIM YS, OH HS, YANG KH, KIM EC, CHI JG. Prenatal development of the human mandible. *Anat Rec* 2001;263:314-25.
21. MERIDA-VELASCO JR, RODRIGUEZ-VAZQUEZ JF, MERIDA-VELASCO JA, SANCHEZ-MONTESINOS I, ESPIN-FERRA J, JIMENEZ-COLLADO J. Development of the human temporomandibular joint. *Anat Rec* 1999;255:20-33.
22. RADLANSKI RJ, SEPADI L, BONTSCHNEV NE. Development of the human temporomandibular joint. Computer-aided 3D-reconstructions. *Eur J Oral Sci* 1999;107:25-34.
23. AVERY JK. Essentials of oral histology and embryology: a clinical approach. 2nd ed. St. Louis: Mosby, 2000:29-41, 156-64.
24. MARTINEZ G, CALTABIANO C, LEONARDI R, CALTABIANO M. Histomorphology of secondary cartilage in human fetal mandibles. *Minerva Stomatol* 1997;46:39-43.
25. GOLA R, CHOSSEGROS C, CHEYNET F. Oto-mandibular ligaments: disco-malleolar and malleo-mandibular ligaments. *Rev Stomatol Chir Maxillofac* 1997;98:66-71.
26. OTT P. Myoarthropathien und Ohrsymptome. In: PALLA S, editor. Myoarthropathien des Kausystems und orofaziale Schmerzen. Zürich: ZZMK der Universität Zürich, 1998:139-41.
27. MERRILL RL. Differential diagnosis of orofacial pain. In: LASKIN DM, GREEN CS, HYLANDER WL, editors. Temporomandibular disorders. An evidence-based approach to diagnosis and treatment. Chicago: Quintessence, 2006:299-317.
28. FANGHÄNEL J, GEDRANGE T. On the development, morphology and function of the temporomandibular joint in the light of the orofacial system. *Ann Anat* 2007;189:314-9.
29. PEROZ I. Otagie und Tinnitus bei Patienten mit kranio-mandibulären Dysfunktionen. *HNO* 2001;49:713-8.
30. KEERSMAEKERS K, De BOEVER JA, Van Den BERGHE L. Otagia in patients with temporomandibular joint disorders. *J Prosthet Dent* 1996;75:72-6.
31. SEEDORF H, JÜDE HD. Otagien als Folge bestimmter kranio-mandibulärer Dysfunktionen. *Laryngorhinootologie* 2006;85:327-32.
32. BADEL T. Temporomandibularni poremećaji i stomatološka protetika. Zagreb: Medicinska naklada, 2007.
33. TUZ HH, ONDER EM, KISNISI RS. Prevalence of otologic complaints in patients with temporomandibular disorder. *Am J Orthod Dentofacial Orthop* 2003;123:620-3.
34. ELY JW, HANSEN MR, CLARK EC. Diagnosis of ear pain. *Am Fam Physician* 2008;77:621-8.
35. JABER JJ, LEONETTI JP, LAWRASON AE, FEUSTEL PJ. Cervical spine causes for referred otalgia. *Otolaryngol Head Neck Surg* 2008;138:479-85.
36. PARKER WS, CHOLE RA. Tinnitus, vertigo, and temporomandibular disorders. *Am J Orthod Dentofacial Orthop* 1995;107:315-8.
37. GROSS M, ELIASHAR R. Otolaryngological aspects of orofacial pain. In: SHARAV Y, BENOLIEL R, editors. Orofacial pain & headache. Edinburgh: Mosby Elsevier, 2008:91-107.
38. BERNHARDT O, GESCH D, SCHWAHN C, BITTER K, MUNDT T, MACK F, KOCHER T, MEYER G, HENSEL E, JOHN U. Signs of temporomandibular disorders in tinnitus patients and in a population-based group of volunteers: results of the Study of Health in Pomerania. *J Oral Rehabil* 2004;31:311-9.
39. UPTON LG, WIJSKERE SJ. The incidence of tinnitus in people with disorders of the temporomandibular joint. *Int Tinnitus J* 2004;10:174-6.
40. REN YF, ISBERG A. Tinnitus in patients with temporomandibular joint internal derangement. *Cranio* 1995;13:75-80.
41. BUMANN A, LOTZMAN U. Funktionsdiagnostik und Therapieprinzipien. Stuttgart, New York: Thieme, 2000.
42. LEWIS EL, DOLWICK MF, ABRAMOWICZ S, REEDER SL. Contemporary imaging of the temporomandibular joint. *Dent Clin North Am* 2008;52:875-90.
43. LARHEIM TA, WESTESSON P-L. TMJ imaging. In: LASKIN DM, GREEN CS, HYLANDER WL, editors. Temporomandibular disorders. An evidence-based approach to diagnosis and treatment. Chicago: Quintessence, 2006:149-79.
44. BADEL T, PANDURIĆ J, MAROTTI M, KOCIJAN LOVKO S. Poremećaj čeljusnog zgloba pacijentice s otalgijom. *Acta Stomatol Croat* 2006;40:175-81.
45. BADEL T, PANDURIĆ J, MAROTTI M, KERN J, KROLO I. Metrička analiza temporomandibularnog zgloba magnetskom rezonancijom u asimptomatskih ispitanika. *Acta Med Croat* 2008;62:455-60.
46. TZANEVA L, SAVOV A, DAMIANOVA V. Audiological problems in patients with tinnitus exposed to noise and vibrations. *Cent Eur J Public Health* 2000;8:233-5.
47. SANDEV S, SOKLER K. Sindrom stiloidnog nastavka. *Acta Stom Croat* 2000;34:445-50.
48. KURMANN PT, van LINTHOUDT D. Syndrome de Eagle: une cause rare de cervicalgies latérales isolées. *Praxis* 2007;96:297-300.
49. CASALE M, RINALDI V, QUATTROCCHI C, BRESSI F, VINCENZI B, SANTINI D, TONINI G, SALVINELLI F. Atypical chronic head and neck pain: don't forget Eagle's syndrome. *Eur Rev Med Pharmacol Sci* 2008;12:131-3.
50. BADEL T, PANDURIĆ J, KRALJEVIĆ S, DULČIĆ N. Inicijalno liječenje protetskih pacijenata michiganskog udlagom. *Acta Stomatol Croat* 2003;36:207-10.
51. BADEL T, ROŠIN-GRGET K, KRAPAC L, MAROTTI M. Principi farmakoterapije temporomandibularnih poremećaja. *Medicus* 2008;16:241-50.

52. MEDLICOTT MS, HARRIS SR. A systematic review of the effectiveness of exercise, manual therapy, electrotherapy, relaxation training, and biofeedback in the management of temporomandibular disorder. *Phys Ther* 2006;86:955-73.
53. BADEL T, KEROS J, MAROTTI M, KERN J, KOCIJAN LOVKO S, ROŠIN GRGET K. Therapy of temporomandibular joint displaced disc according to anxiety. *Period Biol* 2008;110:101-5.
54. WRIGHT EF. Otologic symptom improvement through TMD therapy. *Quintessence Int* 2007;38:564-71.
55. FERNANDES PRB, de VASCONSELLOSHA, OKESON JP, BASTOS RL, MAIA MLT. The anatomical relationship between the positions of the auriculotemporal nerve and mandibular condyle. *J Craniomandib Pract* 2003;21:165-71.
56. TÜR P JC. Springer Lexikon Medizin. Buchbesprechung. *Dtsch Zahnärztl Z* 2005;60:192.
57. GREEN CS. Concepts of TMD etiology: effects on diagnosis and treatment. In: LASKIN DM, GREEN CS, HYLANDER WL, editors. *Temporomandibular disorders. An evidence-based approach to diagnosis and treatment*. Chicago: Quintessence, 2006:219-28.
58. dos REIS AC, HOTTA TH, FERREIRA-JERONYMO RR, de FELÍCIO CM, RIBEIRO RF. Ear symptomatology and occlusal factors: a clinical report. *J Prosthet Dent* 2000;83:21-4.
59. SEIFERT K. Tinnitus und Kauapparat. *Manuelle Medizin* 2002;5:306-9.
60. COX KW. Temporomandibular disorder and new aural symptoms. *Arch Otolaryngol Head Neck Surg* 2008;134:389-93.
61. KUTTLA S, KUTTLA M, Le BELL Y, ALANEN P, SUONPÄÄ J. Recurrent tinnitus and associated ear symptoms in adults. *Int J Audiol* 2005;44:164-70.
62. JEON YD, LEE JI, CHO BO, ROTARU H, KIM JC, KIM SG. Statistical correlation between pharyngitis and temporomandibular joint disease. *Oral Surg Oral Med Oral Pathol Oral Radiol Endod* 2005;99:677-81.
63. TAKES RP, LANGEVELD AP, BAATENBURG de JONG RJ. Abscess formation in the temporomandibular joint as a complication of otitis media. *J Laryngol Otol* 2000;114:373-5.
64. SALVINELLI F, CASALE M, PAPARO F, PERSICO AM, ZINI C. Subjective tinnitus, temporomandibular joint dysfunction, and serotonin modulation of neural plasticity: causal or casual triad? *Med Hypotheses* 2003;61:446-8.

Sažetak

RAZVOJ TEMPOROMANDIBULARNOG ZGLOBA I FUNKCIJSKI POREMEĆAJI POVEZANI S KLINIČKOM OTOLOŠKOM SIMPTOMATOLOGIJOM

T. Badel, I. Savić-Pavićin, D. Podoreški, M. Marotti, I. Krolo i Đ. Grbeša

Temporomandibularni poremećaji (TMP) su oblik mišićno-skeletne boli temporomandibularnog zgloba (TMZ) i/ili žvačnih mišića nespecifične etiologije. U ovoj studiji analizirao se odnos embrijskih i anatomsko-topografskih sličnosti TMZ i uha, odnosno sekundarnih otoloških simptoma koji se mogu usko povezati s TMP. Nespecifični otološki simptomi nisu primarni dijagnostički simptomi TMP, ali mogu izazvati dijagnostičke probleme zbog nemogućnosti bolesnika da točno lociraju izvor boli. Najčešći otološki simptomi koji se mogu povezati s TMP su bolovi u uhu, šum u uhu i vrtoglavica. Otorinolaringolozi moraju razlikovati primarne otološke simptome i one uzrokovane poremećajima u TMZ. U dijagnostici TMP primjenjuju se ručne tehnike kako bi se utvrdio artrogeni ili miogeni oblik, dok je u dijagnostici artrogenih poremećaja indicirana magnetska rezonancija kao visoko specifična metoda slikovnog prikazivanja zglobnog diska i osteoartritičnih promjena. Simptomatsko liječenje TMP, kao i etiološka dijagnostika boli zahtijeva multidisciplinarnu suradnju stomatoloških i medicinskih specijalista.

Ključne riječi: Čeljusni zglob, poremećaji; Bol u uhu; Šum u uhu; Magnetska rezonancija; Dijagnostika, diferencijalna/