

ECHOCARDIOGRAPHY IN DETECTING IMPLANTABLE CARDIOVERTER DEFIBRILLATOR LEAD ENDOCARDITIS: CASE REPORT

Josip Vincelj^{1,2}, Bruno Baršić³, Igor Rudež⁴, Daniel Unić⁴ and Mario Udovičić⁴

¹Department of Cardiovascular Diseases, Dubrava University Hospital; ²University of Applied Health Studies; ³Dr Fran Mihaljević University Hospital for Infectious Diseases; ⁴Department of Cardiac Surgery, Dubrava University Hospital, Zagreb, Croatia

SUMMARY – Lead endocarditis is an infrequent but potentially lethal complication of implantable cardioverter defibrillator (ICD) implantation. We report a case of a 53-year-old man with ICD who was admitted to our hospital because of fever, chills, shivering, headache and malaise. Transthoracic echocardiography detected a structure highly suspect of vegetation located on the ICD lead. Transesophageal echocardiography showed a 20x12 mm mobile vegetation attached to the ICD lead in the right atrium. The infection was caused by methicillin-resistant *Staphylococcus epidermidis* (MRSE), which was isolated from blood cultures. Treatment consisted of surgical removal of the ICD lead and placement of new epicardial ICD leads. Three years afterwards, the patient remained asymptomatic. To our knowledge, this is the first such case reported from Croatia.

Key words: *Defibrillators, implantable – adverse effects; Endocarditis; Prosthesis-related infections; Methicillin-resistant Staphylococcus epidermidis; Echocardiography*

Introduction

Lead endocarditis occurs in less than 1% of permanent pacemaker (PM) and implantable cardioverter defibrillator (ICD) implants. ICD endocarditis may consist of pocket infections, lead infections, lead infections complicated by valve endocarditis, or a combination of these¹. It is a potentially lethal complication and mortality rates of 30% to 35% have been reported. Transthoracic echocardiography (TTE) may identify lead vegetation, but it has not been established as a major diagnostic criterion for ICD lead endocarditis due to its low sensitivity. Transesophageal echocardiography (TEE) allows for exploration of the entire pacing system from the superior vena cava to the right

ventricle². TEE is a useful diagnostic technique for detection and characterization of lead infection.

We describe a case of recurrent staphylococcal bacteremia due to ICD lead endocarditis.

Case Report

A 53-year-old man was admitted to Dr Fran Mihaljević University Hospital for Infectious Diseases with high fever of up to 40.5 °C lasting for three days, accompanied by chills, shivering, headache and malaise. Later, it was revealed that he had experienced similar episodes of fever, shivering and malaise, recurring daily for half an hour on average over the last four months, for which he did not seek medical assistance.

His past medical history was significant for prior implantation of three bare metal stents (BMS) in the left descending artery, left circumflex coronary artery and right coronary artery due to angina pectoris four

Correspondence to: *Josip Vincelj, MD, PhD, FESC*, Department of Cardiovascular Diseases, Dubrava University Hospital, University of Applied Health Studies, Av. G. Šuška 6, HR-10000 Zagreb, Croatia

E-mail: jvincelj@kdb.hr

Received May 13, 2010, accepted May 23, 2010

years before, which was followed by implantation of another three BMS because of in-stent restenosis a year later. Finally, one more year later an ICD was implanted for recurrent sustained ventricular tachycardia.

On admission, the patient was febrile with body temperature of 38.8 °C, hypotensive (blood pressure 80/55 mm Hg), diaphoretic and exhausted. Physical examination revealed no abnormalities. Electrocardiogram (ECG) recorded sinus rhythm with a heart rate of 110 bpm with single premature ventricular beats and nonspecific T-wave changes. Chest x-ray was normal. TTE detected a structure highly suspect of vegetation located on an ICD lead, followed by TEE that showed 20x12 mm mobile vegetation attached to the ICD lead in the right atrium (Fig. 1).

Laboratory test results revealed elevated erythrocyte sedimentation rate (84 mm/h), while leukocyte

count was $8.6 \times 10^9/L$, erythrocyte count $4.5 \times 10^{12}/L$, hemoglobin 119 g/L, CRP 185.2 mg/L, bilirubin 32.5 $\mu\text{mol}/L$ and $\gamma\text{-GT}$ 138 mmol/L. Urine was normal on routine and microscopic examination and urine cultures remained sterile. Therapy with intravenous amoxicillin and potassium clavulanate was initiated, and after the collection of blood cultures, it was exchanged for a combination of rifampicin, gentamicin and vancomycin. Since methicillin-resistant *Staphylococcus epidermidis* (MRSE) isolated from blood culture was proven sensitive to vancomycin, the other two antibiotics were discontinued after a week.

Under antibiotic treatment, the patient gradually became subfebrile and then afebrile in the last two days. Since urgent surgical treatment was indicated, he was transferred to Cardiac Surgery after altogether 18 days of antibiotic treatment. On the second day of transfer, the patient underwent surgical ICD lead ex-

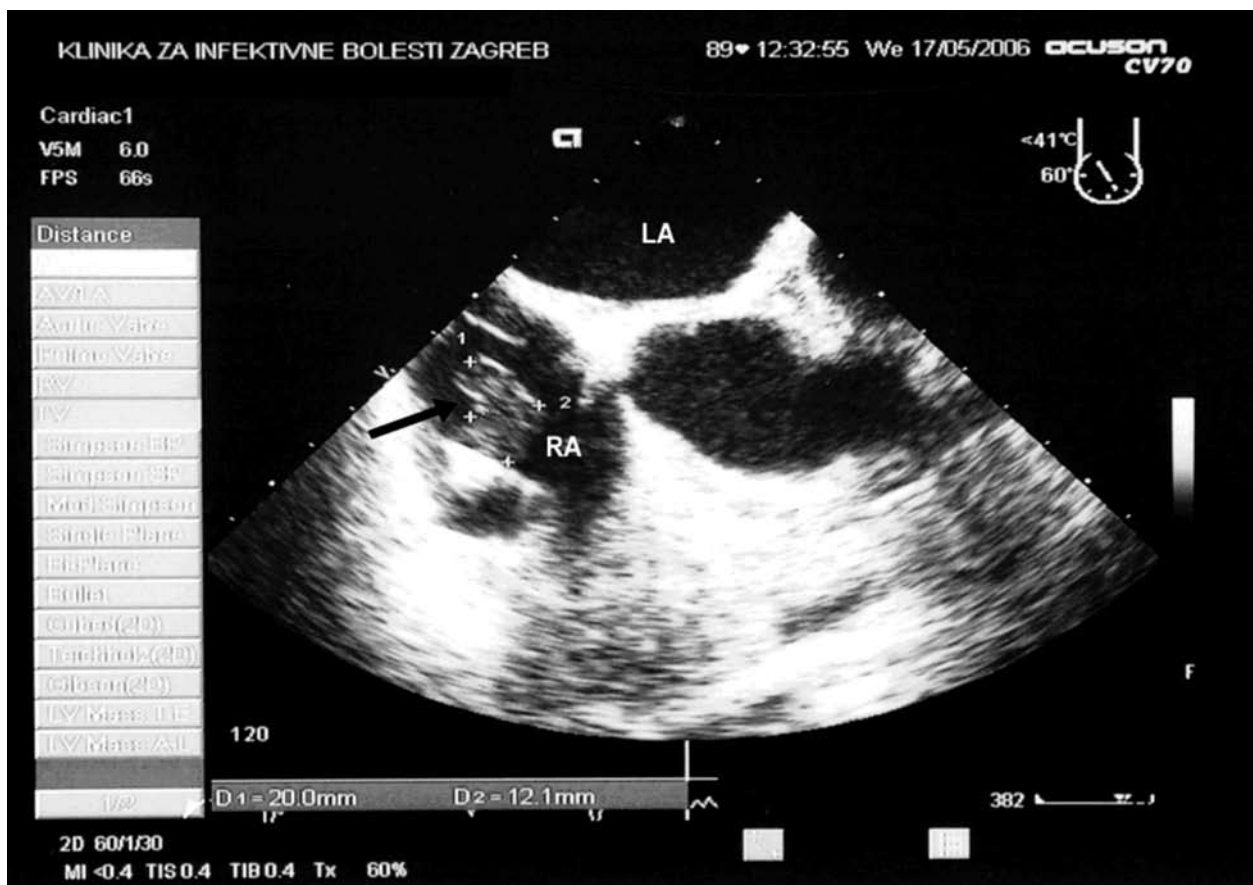


Fig. 1. Transesophageal echocardiogram showing large vegetation attached to the implantable cardioverter defibrillator lead in the right atrium (arrow); RA, right atrium; LA, left atrium.

traction (Fig. 2). It was followed by valvuloplasty of tricuspid valve with ring implantation (Edwards Lifesciences Anuloplasty Ring 32 mm) due to valve endocarditis and epicardial reimplantation of ICD leads. Microbiological analysis of the extracted lead identified MRSE as the causative organism of endocarditis. Echocardiographic survey after the procedure showed normal function of the left ventricle and heart valves. Vancomycin therapy was continued for 14 days post-explantation. Postoperative period was uneventful and 36 months later the patient remained asymptomatic. To our knowledge, this is the first case of implantable cardioverter defibrillator lead endocarditis reported from Croatia.

Discussion

Lead endocarditis after pacemaker and ICD implantation is a rare but potentially lethal complication. It is therefore necessary to complete diagnostic work-up as fast as possible, isolate the pathogenic agent and apply appropriate antimicrobial therapy followed by removal of the infected material.

Lead endocarditis can appear at different points in time after the implantation. Early-onset endocarditis is defined as endocarditis occurring within 12 months after implantation, and late-onset endocarditis is defined as endocarditis after 12 months of implantation³. The mean time interval between the implantation of a permanent PM or ICD and the first appearance of symptoms of endocarditis is 2.9 years. Lead endocarditis may occur in the early or late postoperative period, but only a small number of patients (16.9%) present with an early infection within less than two months of the implantation³. In our patient, this interval was 2 years.

Whenever ICD or permanent PM lead endocarditis is suspected, TEE is the diagnostic modality of choice for detection of vegetations⁴. The sensitivity of TTE is significantly lower (23%-30%) compared with TEE (91%-96%) in the diagnosis of permanent PM and ICD lead endocarditis^{3,5}.

Like the endocarditis of heart valves, the endocarditis of PM and ICD leads is also diagnosed by the use of Duke criteria; hence, positive blood cultures and vegetation noted on the lead will confirm the diagnosis^{3,6}. Our patient was febrile, had a positive blood culture with isolated causative organism from

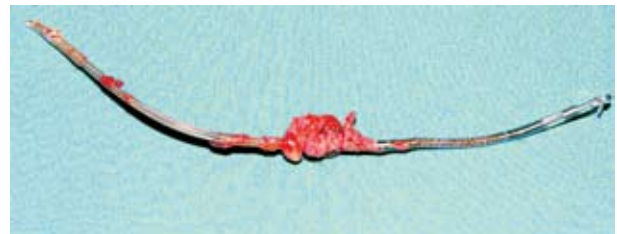

Fig. 2. Vegetation attached to the implantable cardioverter defibrillator lead recorded immediately after surgery.

MRSE group and vegetations were found on the lead and on the tricuspid valve.

It took three days from the onset of fever that led to hospitalization to the definite diagnosis. The fact that the patient had had recurrent episodes of fever for 4 months before admission (during which he had never sought medical assistance), suggested recurrent bacteremia. Finally, the lead vegetation culture was positive and the pathogenic agent was identified by microbiological analysis.

Antibiotic therapy is mandatory before and after lead extraction, and its intravenous administration for 4 weeks is considered to be sufficient. Patients who do not undergo lead extraction are required to receive prolonged antibiotic therapy for 6 weeks. The majority of patients are subjected to lead extraction, whether percutaneous or surgical. The way of lead extraction is determined by the size and mobility of the vegetation as well as by possible valve endocarditis. For smaller (<10 mm) and less mobile vegetations, the method of choice is percutaneous extraction, while larger and more mobile vegetations along with concomitant valve endocarditis are an indication for surgical intervention. After surgical removal, reimplantation of a permanent PM or an ICD is accomplished by the placement of epicardial leads, while after percutaneous extraction it is done by transvenous approach of lead placing. In our case, a very large and mobile vegetation together with accompanying valve endocarditis mandated surgical approach and use of epicardial leads. The overall time interval from the diagnosis to surgical treatment was 19 days.

The treatment of PM and ICD lead endocarditis is based on the combination of antibiotic therapy and surgical intervention. Literature data indicate that best results are achieved by antibiotic therapy before and after lead removal. If percutaneous or surgical ex-

traction is not performed, then prolonged antibiotic therapy is required, although with worse outcome and higher mortality rates^{2,7}.

There are two possible origins of PM and ICD lead endocarditis. The first one is bacteremia, which can cause colonization of the lead by pathogen agents, and the second one is local infection of the area around generator and its distal progression along the lead^{4,7}. Thorough inspection of the generator implantation area is mandatory for early prevention, timely detection and possible treatment of a potential lead infection. Since no infection of the generator implantation area was detected in our patient, we assumed bacteremia to be the source of infection.

In conclusion, the application of TTE and TEE in patients with suspected ICD lead endocarditis enables making an accurate and early diagnosis, which is essential for timely therapy initiation and better outcome. ICD lead endocarditis can be safely managed by surgical lead extraction with reimplantation of epicardial patch leads after intravenous antibiotic therapy.

References

1. COREY GR, LALANI T. Risk of intravascular cardiac device infections in patients with bacteraemia: impact on device removal. *Int J Antimicrob Agents* 2008;325:526-9.
2. del RIO A, ANGUERA I, MIRO JM, *et al.* Surgical treatment of pacemaker and defibrillator lead endocarditis. *Chest* 2003;124:1451-9.
3. KERUT EK, HANAWALT C, EVERSON CT. Role of echocardiography laboratory in diagnosis and management of pacemaker and implantable cardiac defibrillator infection. *Echocardiography* 2007;24:1008-12.
4. WASSON S, AGGARWAL K, FLAKER G, REDDY HK. Role of transesophageal echocardiography in detecting implantable cardioverter defibrillator lead infection. *Echocardiography* 2003;20:289-90.
5. DUMONT E, CAMUS C, VICTOR F, *et al.* Suspected pacemaker or defibrillator transvenous lead infection: prospective assessment of a TEE-guided therapeutic strategy. *Eur Heart J* 2003;24:1779-87.
6. HABIB G. Management of infective endocarditis. *Heart* 2006;92:124-30.
7. BADDOUR LM, BETTMANN MA, BOLGER AF, *et al.* Nonvalvular cardiovascular device-related infections. *Circulation* 2003;108:2015-31.

Sažetak

ECHOKARDIOGRAFIJA U OTKRIVANJU ENDOKARDITISA IZAZVANOG UGRADNOM ELEKTRODE IMPLANTABILNOG KARDIOVERTER DEFIBRILATORA: PRIKAZ SLUČAJA

J. Vincelj, B. Baršić, I. Rudež, D. Unić i M. Udovičić

Endokarditis elektrode je rijetka no potencijalno smrtonosna komplikacija ugradnje implantabilnog kardioverter defibrilatora (ICD). Prikazujemo slučaj 53 godine starog muškarca s implantiranim ICD-om koji je hospitaliziran zbog febriliteta, groznice, tresavice i općeg lošeg stanja. Transtorakalnim ultrazvukom srca je otkrivena tvorba vrlo sumnjiva na vegetaciju na elektrodi ICD-a, da bi transezofagusnim ultrazvukom bila prikazana vegetacija veličine 20x12 mm pričvršćena za elektrodu ICD-a u desnom atriju. Uzročnik endokarditisa je bio meticilin rezistentni *Staphylococcus epidermidis* (MRSE) koji je izoliran u hemokulturi. Liječenje se sastojalo od kirurškog odstranjenja elektrode ICD-a i njene zamjene novim, epikardijalnim elektrodama. Tri godine kasnije bolesnik je i dalje bez tegoba. Prema našim saznanjima, ovo je prvi ovakav slučaj dosad opisan u Hrvatskoj.

Ključne riječi: *Defibrilatori, ugradbeni – štetni učinci; Endokarditis; Infekcije kod ugradnje proteze; Infekcije uzrokovane bakterijom MRSE; Ehokardiografija*