

A Probable Case of Hand-Schueller-Christian's Disease in an Egyptian Mummy Revealed by CT and MR Investigation of a Dry Mummy

Mislav Čavka^{1,2}, Anja Petaros³, Gordana Ivanac^{1,2}, Lejla Aganović⁴, Ivor Janković⁵, Gert Reiter⁶, Peter Speier⁷, Sonja Nilles-Vallespin^{8,9} and Boris Brkljačić^{1,2}

¹ University of Zagreb, Dubrava University Hospital, Department of Diagnostic and Interventional Radiology, Zagreb, Croatia

² University of Zagreb, School of Medicine, Zagreb, Croatia

³ University of Rijeka, School of Medicine, Department of Forensic Medicine and Criminalistics, Rijeka, Croatia

⁴ University of California, San Diego Department of Radiology, San Diego, CA, USA

⁵ Institute for Anthropological Research, Zagreb, Croatia

⁶ Siemens AG Healthcare, Graz, Austria

⁷ Siemens AG Healthcare, Erlangen, Germany

⁸ Royal Brompton Cardiovascular MR Unit, London, UK

⁹ Harefield NHS Foundation Trust, London, UK

ABSTRACT

The challenging mission of paleopathologists is to be capable to diagnose a disease just on the basis of limited information gained by means of one or more paleodiagnostic techniques. In this study a radiologic, anthropologic and paleopathologic analysis of an ancient Egyptian mummy through X-rays, CT and MR was conducted. An Ancient Egyptian mummy (»Mistress of the house«, Archeological Museum, Zagreb, Croatia) underwent digital radiography, computed tomography and magnetic resonance imaging employing 3-dimensional ultra-short-echo time (UTE) sequence, that allows to image ancient dry tissue. Morphological observations on the skull and pelvis, the stages of epiphyseal union and dental wear indicated that the remains are those of a young adult male. Multiple osseous lytic lesions were observed throughout the spine as well as on the frontal, parietal, and occipital bone, orbital wall and the sella turcica of the sphenoid. Considering the sex and age of the individual and the features of the lesions, the authors propose the diagnosis of Hand-Schueller-Christian's disease. This is the first study to have effectively used MR images in the differential diagnosis of a disease. It also confirmed the CT value in revealing central nervous system involvement just by detecting skeletal lesions. Although the mummy was previously dated to 3rd century B.C. based on the properties of the sarcophagi, the sex of the mummy suggests that it was most probably transferred into these sarcophagi in later times. The mummification techniques used and radiometric data (C14) dated it to 900-790. B.C.

Key words: paleoradiology, paleopathology, MR, CT, mummies, Croatia, ancient Egypt

Introduction

Ancient remains are a valuable tool to explore the history of diseases and provide answers to questions about the evolution and epidemiology of various diseases and syndromes, and their etiology over time^{1,2}. These lessons from the past not only allow us to interpret living conditions in ancient times, but also to understand how the modern world impacts our health. The challenging mission of the paleopathologist is to be capable to diagnose a

disease solely on the basis of limited information gained by means of paleodiagnostic techniques. Along with paleogenetics and paleohistology, paleoimaging is one of the most valuable means of studying mummified remains and diseases³. Although plain radiography gives abundant information on the insight of a mummy, soft tissues and body cavities could not be well imaged until the emergence of computed tomography (CT) in 1970's. De-

tailed surface reconstructions became available with the advent of advanced units and postprocessing software in 1990's, as new imaging diagnostic techniques have progressively been tested and applied in studies of mummies, paleopathologists also attempted to subject them to magnetic resonance (MR) imaging. The first effort in

1983 yielded disappointing results, because conventional MR techniques rely on the presence of free water in soft tissues that is lacking in mummified tissues⁴. After that, clinical MR has been rarely applied to mummified specimens, and mostly in cases with rehydrated or melted frozen soft tissues⁵. In 2007, for the first time, Ruhli et

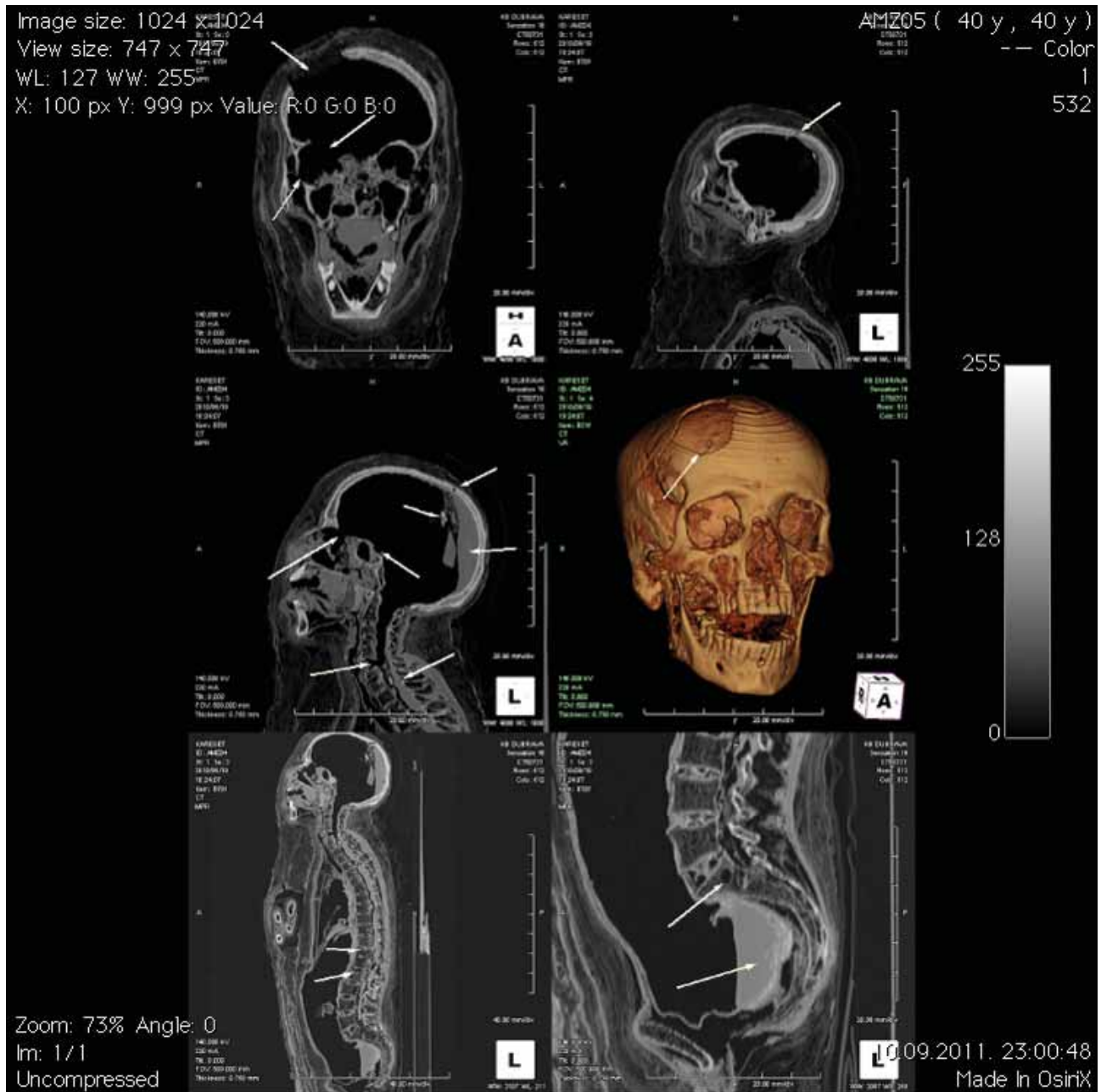


Fig. 1. a) CT oblique coronal plane through head. Large defect of frontoparietal bone and unilateral orbital wall destruction; b) CT sagittal plane through head. Focal discrete lytic lesion in the skull. Bone fragments and resin like fluid in the posterior fossa. Defect of the cribriform plate and shallow sella turcica. Bone fragments in spinal channel. Anteposition of body of C5 in respect to C6; c) CT sagittal plane through head. Focal discrete lytic lesions in the skull. Bone fragments and resin like fluid in the posterior fossa. Defect of the cribriform plate and shallow sella turcica. Bone fragments in spinal channel. Anteposition of body of C5 in respect to C6; d) CT, volume rendering technique (VRT). Large defect of frontoparietal bone; e) CT sagittal plane through spine. Two collapsed vertebral bodies; f) CT sagittal plane through sacrum. Lytic lesions.

al. presented exceptional MR images of dry mummified tissues, gained by the use of an ultra-short-echo time (UTE) sequence⁶.

The results of this study presents a probable case of Hand-Schueller-Christian's syndrome in a young adult Egyptian mummy diagnosed by the above-mentioned imaging methods. As this is the second study to have successfully obtained MR images with UTE sequence of a dry mummy, the authors will discuss its usefulness in the examination of the case.

Materials and Methods

In collaboration with the Archeological Museum in Zagreb, an Egyptian mummy, known by the name Kareset, was subjected to radiological analysis at the Department for Diagnostic and Interventional Radiology of the Dubrava University Hospital, Zagreb, Croatia. The two polychrome wooden anthropomorphic sarcophagi that held the remains suggested that the mummy belongs to the 3rd century BC, while the direct radiocarbon dating placed it back to the 900–790 BC. The name Kareset was inscribed in hieroglyphics on the sarcophagi, along with the inscription »mistress of the house«, that indicates a married woman⁷.

Digital radiographs of the whole body were done in frontal and lateral views (RadSpeed Sapphire, Shimadzu Europa GmbH, Duisburg, Germany). Axial CT slices were obtained using 16×0.75 collimation and images were reconstructed at 0.75-mm section thickness and 0.7 mm reconstruction increment using MDCT unit (Sensation 16; Siemens Healthcare, Erlangen, Germany). The scanning parameters were 220 mA and 140 kV.

Three-dimensional (3D), spoiled gradient echo based UTE images⁸ of the mummy were acquired on a 1.5-T scanner (Magnetom Avanto, Siemens Healthcare, Erlangen, Germany) employing manufacturer's head and spine array coils, contrast-determining parameters echo time, repetition time and flip angle were chosen 0.07 ms, 15 ms and 45°, respectively. The 40000 radial projections used to reconstruct 256 slices of 1.3×1.3×1.3 mm³ isotropic resolution, resulted in an imaging time of 10 min per 3D slab.

Postprocessing was performed on Leonardo workstation (Siemens AG Medical Solutions, Erlangen, Germany) and Aquarius workstation (Terarecon Inc, San Mateo, USA).

Anthropological analysis included the determination of sex, age at death and pathological conditions. Sex was determined by morphological characteristics of skull and pelvic bones^{9,10}. Age at death was estimated combining different methods, including the fusion of the secondary ossification centers, dental wear and age-related degenerative changes at the margin of articular surfaces.

Results

Anthroposcopic analysis of X-ray and CT images of the skull and pelvis indicated the mummy was a male, while moderate dental wear, unerupted third molars and the lack of degenerative articular changes suggested that the individual was between 20 and 30 years of age.

Head scans showed a large defect (Figure 1a-1d) of the fronto-parietal bone and several scattered focal discrete lytic lesions without a sclerotic rim in the skull (Figure 1b, 1c). The scans also depicted unilateral orbital wall destruction (Figure 1a). Midline CT images showed a defect of the cribriform plate of the ethmoid and a shallow sella turcica of the sphenoid (Figure 1c). Bone fragments mixed within a resin-like fluid were present in the posterior cranial fossa (Figure 1c, 2a, 2b).

Cervical dislocation with anteposition of C5 relative to C6 and minor skeletal fragments trapped in the spinal canal were revealed by the CT scans of the neck (Figure 1c). Two vertebral bodies were collapsed and lytic lesions were observed along the spine (Figure 1e, 1f).

The examination of the thoracic and abdominal regions evidenced four linen wrappings that should correspond to four visceral packets positioned within the bodily cavities in the mummification process, suggesting that the corpse was embalmed at the time of the 21st Dynasty or later (Figure 3a, b). A vertical incision sealed with tangled linen, used probably to prevent fluid leakage, was found in the lower left abdomen (Figure 3c). An elongated thin cloth wrap was inserted within the pubic arch as an extension of the phallus (Figure 3d, 4b). Another cluster of resin-like fluid was observed in the pelvic cavity (Figure 1f, 4a).

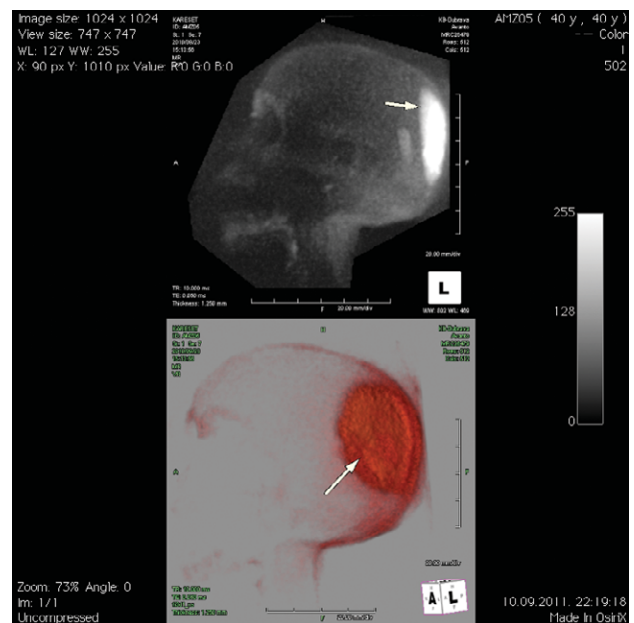


Fig. 2. a) MR, maximum intensity projection (MIP). Resin like fluid in the posterior fossa; b) MR,VRT. Resin like fluid in the posterior fossa.

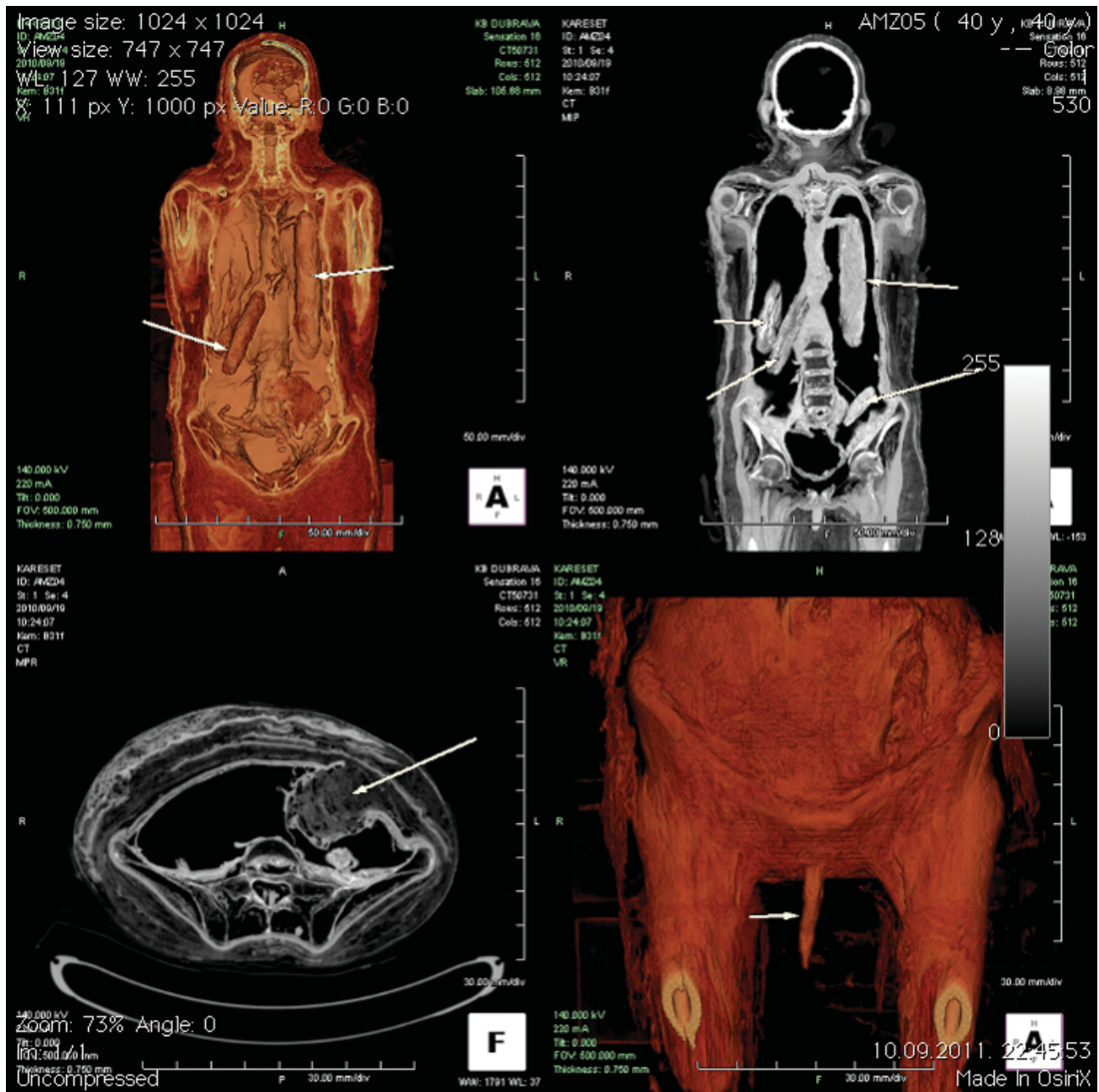


Fig. 3. a) CT, VRT. Two linen wrappings; b) CT, MIP. Four linen wrappings; c) CT, axial plane through lower abdomen. Incision with tangled linen, used for abdominal exvisceration; d) CT, VRT. Phallus prolongation.

Data produced by the UTE sequence completed the paleoradiologic examination. MRI helped to examine the condition of the intervertebral discs, which showed no pathological lesions (Figure 5a, b).

Discussion

Anthropological analysis concluded that the remains were likely that of a young adult male. Along with the features of the skull and the pelvic indicating a male indi-

vidual, the presence of the phallic structure left no doubt regarding the mummy's sex. It is most likely that the corpse of a young male, from the period between 950–790 BC was transferred into a 3rd century BC sarcophagus of a married woman called Kareset. When and why was done remains unknown.

The CT and MR examination shed more light on the story of Kareset. Although the skull defect was probably used as an auxiliary way for brain extraction, the hal- lowed ethmoid indicates a transnasal brain removal. The

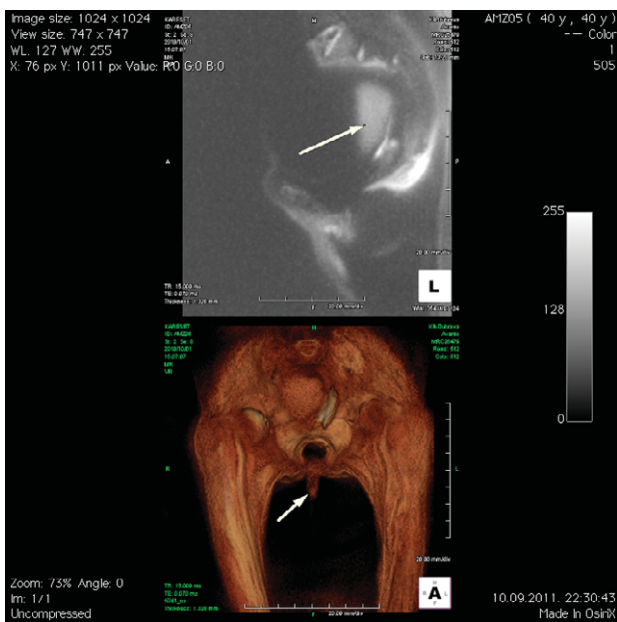


Fig. 4. a) MR, MIP. Resin like fluid in pelvic cavity; b) MR, VRT. Phallus.

presence of other lytic lesions scattered in the skull and the spinal column suggested a pathological origin of the defect, which was probably subsequently enlarged to facilitate brain removal. The embalmers also probably caused the observed spinal dislocation. Lytic skeletal and other lesions suggest a rather unusual condition in these ancient remains: Hand-Schueller-Christian's disease.

Hand-Schueller-Christian's disease is one of the three syndromes associated with Langerhans cell histiocytosis, a disease caused by uncontrolled monoclonal proliferation of the Langerhans cells whose etiology is still undefined. It sporadically occurs in young adults (1:560000), more frequently in males^{11,12}. Unlike eosinophilic granuloma, the most common of the three syndromes, which is restricted to bone, Hand-Schueller-Christian's is a multiorgan disease. Lytic bone lesions, exophthalmus and diabetes insipidus are the most commonly described symptoms, but all together appear only occasionally (1:10)¹³. The last two are the product of granulomatous infiltration of the central nervous system compressing the posterior pituitary gland and the orbital content^{11,14}. In the present case, the shallow sella turcica suggests a pituitary involvement that could have lead to diabetes insipidus, while the fractured orbit might be the result of orbital diffusion of granulomatous deposits. The collapsed vertebrae are also one of the known clinical presentations of Langerhans histiocytosis.

Although these findings are in line with the triad of symptoms associated with Hand-Schueller-Christian disease, other conditions must be taken into consideration. The punched out lytic lesions might also be caused by multiple myeloma or metastases. However, no bone marrow infiltration was observed and there were no organs that could confirm soft-tissue extensions or allow biopsy.

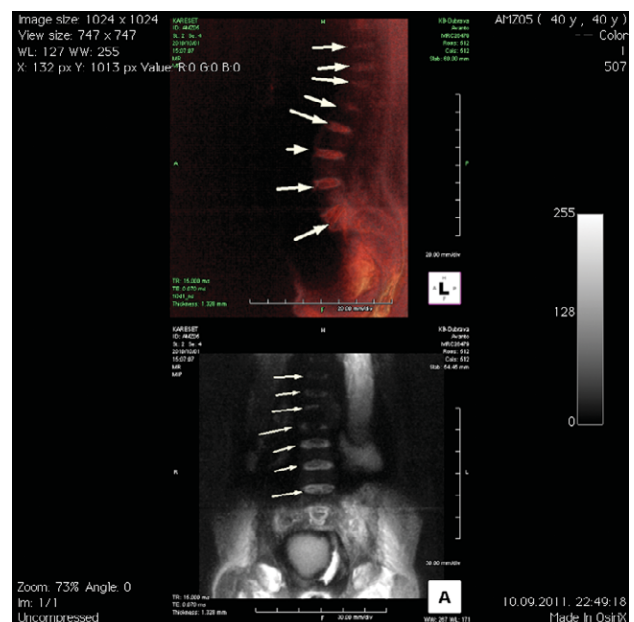


Fig. 5. a) MR, VRT. Inter vertebral disks; b) MR, MIP. Inter vertebral disks.

Central nervous system involvement has been suggested solely on the ground of skeletal alterations: orbit fracture suggesting orbital infiltration and shallow sella turcica suggesting diabetes insipidus. The fracture of the orbit could just be a byproduct of transnasal excrebration. However, the massive destruction of both, the medial and the inferior wall of the orbit, leads to a conclusion that it was more likely caused by a pathological condition than by a traumatic event. Except by Langerhans histiocytosis, vertebral collapse in adults could be caused by myeloma, osteonecrosis, or spondylitis. MR played a crucial role in establishing a diagnosis, as it allowed us to evaluate the condition of the intervertebral disc spaces, which are preserved in Langerhans histiocytosis, but not in spondylitis¹³. Moreover, in the future, MRI could be used to make a differential diagnosis between discitis and neoplastic spinal lesions or to help interpret the substances used during embalming, through different signals gained by resins or other material present in bodily cavities.

Conclusion

This is the third case of Hand-Schueller-Christian's disease described in Egyptian remains, and the first to be described and diagnosed by CT and MR imaging¹⁵. Although the presence of soft tissue in mummies makes them extremely valuable to paleopathologists, in this case no organs were left in the body and thus the diagnosis was based exclusively on radiologic findings of skeletal lesions. Our study, second only to that of Ruhli et al, made use of the UTE sequence on a dry mummy and confirmed it is possible to gain satisfactory MR images of mummy tissues, artifacts (resins), which allows a differ-

ential diagnosis that would not be possible using only CT or X-ray imaging.

Acknowledgements

Authors wish to thank Igor Fućkan of the Department of Diagnostic and Interventional Radiology in Dubrava University Hospital, Igor Uranić and Jacqueline

Balen of the Archaeological museum in Zagreb, Maja Šešelj of the Wright State University, Dayton, and Petra Rajić-Šikanjić of the Institute for anthropological research, Zagreb, for their help and suggestions during the preparation of the manuscript. The analyses were partially supported by the Ministry of Science, education and sports of the Republic of Croatia (grant No. 196-1962766-2740).

REFERENCES

1. CZARNETZKI A, BLIN N, PUSCH CM, *Lancet*, 362 (2003) 1000.
2. DAVID AR, ZIMMERMAN MR, *Nat Rev Cancer*, 10 (2010) 728.
3. LYNNERUP N, *Yearbook of Physical anthropology*, 50 (2007) 162.
4. NOTMAN DNH, *Paleopathol Newsl*, 43 (1983) 9.
5. NOTMAN DN, AUFDERHEIDE AC, *Experimental mummification and computed imaging*. In: *Proceedings (First World Congress on Mummy Studies, Tenerife, 1992)*.
6. RUHLI FJ, NIELLES-VALLESPIN S, BONI T, SPEIER P, *JAMA*, 298 (2007) 2618.
7. URANIC I, *Aegyptiaca Zagrabiensa*. (Arheološki muzej, Zagreb, 2007).
8. NIELLES-VALLESPIN S, WEBER MA, BOCK M, BONGERS A, SPEIER P, COMBS SE, WÖHRLE J, LEHMANN-HORN F, ESSIG M, SCHAD LR, *Magn Reson Med*, 57 (2007) 74.
9. WEA (Workshop of European Anthropologists Recommendation for age and sex diagnosis of skeletons), *J Hum Evol*, 9 (1980) 517.
10. BUIKSTRA J, UBELAKER D, *Standards for data collection from human skeletal remains*. (Arkansas Archaeological Survey, Fayetteville, 1994).
11. BRADFORD HOOVER K, ROSENTHAL DI, MANKIN H, *Skeletal Radiol*, 36 (2007) 95.
12. STULL MA, KRANSDORF MJ, DEVANEY KO, *RadioGraphics*, 12 (1992) 801.
13. LICHTENSTEIN L, *AMA Arch Pathol*, 56 (1953) 84.
14. KALTSAS GA, POWLES TB, EVANSON J, PLOWMAN PN, DRINKWATER JE, JENKINS PJ, MONSON JP, BESSER GM, GROSSMAN AB, *J Clin Endocrinol Metab*, 85 (2000) 137.
15. STROUHAL E, *OSSA*, 3–4 (1977) 11.

M. Čavka

University of Zagreb, Dubrava University Hospital, Department of Diagnostic and Interventional Radiology, Av. Gojka Šuška 6, 10000 Zagreb, Croatia
e-mail: mislav.cavka@yahoo.com

VJEROJATAN SLUČAJ HAND-SCHUELLER-CHRISTIAN BOLESTI EGIPATSKE MUMIJE OTKRIVEN CT I MR SNIMKAMA MUMIFICIRANOG TIJELA

SAŽETAK

Dijagnosticirati bolest na temelju ograničenih informacija dobivenih uporabom jedne ili više paleodijagnostičkih tehnika je izazovna misija paleopatologa. U ovoj je studiji provedena radiološka, antropološka i paleopatološka analiza staroegipatske mumije uporabom roentgena (RTG), kompjuterske tomografije (CT) i magnetske rezonancije (MR). Staroegipatska mumija (»Gospodarica kuće«, Arheološki muzej u Zagrebu, Hrvatska) podvrgnuta je pregledu digitalnom radiografijom, kompjuteriziranom tomografijom i magnetskom rezonancijom upotrebom 3-dimenzionalne »ultra-short-echo time« (UTE) sekvencije, koja omogućava oslikavanje starog osušenog tkiva. Morfološka opažanja na lubanji i zdjelici, stadiji epifizealnog sraštavanja i potrošnja zubi upućuju da se radi o ostacima mladog odraslog muškarca. Multiple koštane litičke lezije su pronađene na kralježnici, na frontalnoj, parijetalnoj, okcipitalnoj kosti, orbitalnom zidu i turskom sedlu. Uzevši u obzir spol, dob i karakteristike lezija, autori predlažu dijagnozu Hand-Schueller-Christianove bolesti. Ovo je prva studija u kojoj je korišten MR u diferencijalnoj dijagnozi bolesti. Studija je potvrdila korisnost uporabe CT-a u otkrivanju bolesti središnjeg živčanog sustava na temelju koštanih lezija. Iako je mumija, prema elementima sarkofaga, bila datirana u 3. stoljeće prije Krista, spol mumije nam ukazuje da je najvjerojatnije bila u njega naknadno premještena. Tehnike mumifikacije i radiometrijska analiza datiraju ju od 900.–790. godine pr. Kr.