

DEVELOPMENT OF GRAVES' DISEASE FOLLOWING RADIOIODINE TREATMENT FOR AUTONOMOUSLY FUNCTIONING THYROID ADENOMA: CASE REPORT

Jadranka Martinko¹, Maja Cigrovski-Berković¹, Branko Bečejac¹, Darko Solter² and Miljenko Solter¹

¹University Department of Endocrinology, Diabetes and Metabolism, ²University Department of Ear, Neck and Throat, Sestre milosrdnice University Hospital Center, Zagreb, Croatia

SUMMARY – A patient with development of autoimmune hyperthyroidism following radioiodine treatment for autonomously functioning thyroid adenoma is presented. This is a rare occurrence, probably as a consequence of shedding of the thyroid-stimulating hormone receptor, which is a source of antigen leading to activation of the autoimmune response in susceptible individuals.

Key words: *Thyroid neoplasms; Adenoma; Radiotherapy; Iodine radioisotopes; Graves' disease*

Introduction

Radioiodine is the treatment of choice for the hyperthyroidism caused by autonomously functioning thyroid adenoma. Side effects of such a treatment are few and primarily include radioactive thyroiditis (<5% of patients), while development of Graves' disease occurs rarely, in less than 2% of treated patients. The molecular basis of thyroid hyperfunction lays in point genetic mutations and/or antibody-induced structural changes of the thyroid-stimulating hormone receptor (TSHR), which appears to have unstable molecular integrity and thus propensity to overactivity¹. In this case report, we describe development of persistent autoimmune hyperthyroidism in a patient treated with radioiodine for the hyperfunctioning thyroid adenoma.

Case Report

A 49-year-old female patient reported to our department for the symptoms of hyperthyroidism and

palpable thyroid nodule. Initial diagnostic algorithm confirmed the early onset hyperthyroidism (T3 3.0, T4 92, and TSH 0.008) (Table 1) and thyroid scintiscan was indicative of toxic adenoma in the right thyroid lobe (Fig. 1a). The patient received radioiodine treatment (21 mCi J-131) and after 4-month follow-up euthyroidism was achieved (T3 2.2, T4 84, and TSH 1.87) (Table 1), suggesting curative effect of radioiodine. Twelve months later, the patient's symptoms recurred, but this time thyroid scintiscan unexpectedly suggested increased radioiodine accumulation in the left thyroid lobe (Fig. 1b), while endocrinological findings were suggestive of recurrent hyperthyroidism (T3 2.6, T4 127, TSH <0.002) (Table 1). The patient was treated with beta-blockers until the etiology of hyperthyroidism was confirmed. After six months of treatment, the symptoms were well controlled but repeated thyroid scintiscan undoubtedly confirmed diffuse, more intense radioiodine accumulation in the left thyroid lobe, a finding specific for autoimmune hyperthyroidism (Fig. 1c). This was supported by the laboratory finding of positive anti-TPO antibodies (338) and anti-Tg-antibodies (134), increased thyroid hormones (T3 3.5 and T4 166) and suppressed TSH (<0.004) (Table 1). TR-Ab was slightly positive (3.4). MMI in lower dose was introduced for a short time

Correspondence to: *Maja Cigrovski-Berković, MD, PhD*, University Department of Endocrinology, Diabetes and Metabolism, Sestre milosrdnice University Hospital Center, Vinogradska c. 29, HR-10000 Zagreb, Croatia
E-mail: mberkovi@xnet.hr

Received March 18, 2011, accepted November 15, 2011

Table 1. Thyroid hormone levels during the course of treatment

Timeline	T3 (nmol/L)	T4 (nmol/L)	TSH (mIU/L)
Initial	3.0	92	0.008
4 months following 1 st I131 application	2.2	84	1.87
12 months following I131	2.6	127	<0.002
1.5 year following I131	3.5	166	<0.004
Following 2 nd I131 application	2.4	98	0.25

until euthyroidism was achieved (T3 2.4, T4 98, TSH 0.25) (Table 1). Finally, two years after initial radioiodine treatment, the patient received J-131 (8 mCi) once again. Now she is hypothyroid, receiving replacement levothyroxine treatment (75 mcg of levothyroxine).

Discussion

Hyperthyroidism is a relatively common thyroid disorder occurring in 0.77/1000 female and 0.18/1000 male patients. Most commonly it is a symptom of autoimmune, Graves' disease, while other causes,

including autonomous, toxic adenoma or toxic multinodular goiter are less frequent². Up to 9% of hyperthyroid patients with nodular hyperfunctioning goiter (either multinodular or with a single hyperfunctioning node) also have positive TRAb, making it difficult to distinguish the true etiology of hyperthyroidism. In rare patients with Marine-Lenhart syndrome, autoimmunity and autonomy of thyroid nodules coexist in the same patient^{3,4}. According to scarce literature reports, transition from autonomously functioning thyroid nodules to autoimmune hyperthyroidism can result from therapeutic manipulation of the gland, either following radioiodine⁵ or thyroid surgery⁶, or can be a consequence of nodule degradation caused by infarction⁷. It is probably a direct consequence of shedding of the TSHR ectodomain, providing a source of antigen and activating the autoimmune response in prone/susceptible individuals¹. Our patient's findings showed the occurrence of atypical Graves' disease following radioiodine treatment and development of anti-TPO, anti-TGA antibodies and to a lesser extent TRAb. This may be due to a smaller thyroid size because of the previous radioiodine treatment. Unlike true Graves' disease, clinical presentation was mild and thyroid hormones only slightly elevated. The possible cause is probably radioiodine treatment, which may have triggered the autoimmune response, turning a toxic nodule into Graves' disease. We conclude that in particular patients susceptible to autoimmunity, the release of antigenic materials secondary to thyroid destruction during radioiodine treatment can trigger an autoimmune thyroid response and lead to Graves' disease development. Patients may then have a milder and gradual course of disease with attenuated symptoms.

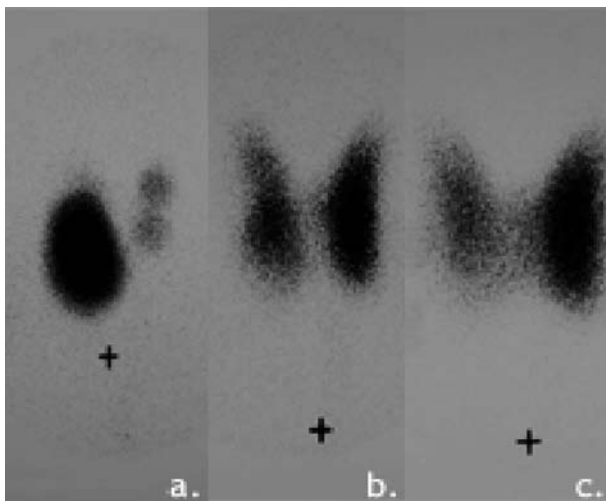


Fig. 1. (a) Toxic adenoma of the right thyroid lobe and suppressed uptake of radioiodine in the adjacent normal gland on initial scintiscan; (b) post-radioiodine scintiscan with diffuse positivity of the left thyroid lobe and to a lesser extent right thyroid lobe; (c) thyroid scintiscan after 1.5 year with further progression of the uptake in the left thyroid lobe.

References

1. DAVIES TF, ANDO T, LIN RY, TOMER Y, LATIF R. Thyrothropin receptor-associated diseases: from adenomata to Graves disease. *J Clin Invest* 2005;115:1972-83.
2. WEETMAN AP. Etiology, diagnosis and treatment of Graves' disease. *Thyroid Int* 2003;2:3-14.
3. CHARKES ND. Graves' disease with functioning nodules (Marine-Lenhart syndrome). *J Nucl Med* 1972;13:885-92.
4. INTENZO CM, DEPAPP AE, JABBOUR S, MILLER JL, KIM SM, CAPUZZI DM. Scintigraphic manifestations of thyrotoxicosis. *RadioGraphics* 2003;23:857-69.
5. ORSOLON P, LUPI A, De ANTONI MIGLIORATI G, VIANELLO DRI A. Appearance of Graves-like disease following regression of autonomously functioning thyroid nodules. Two case reports. *Minerva Endocrinol* 1998;23:53-6.
6. LAURBERG P, WALLIN G, TALLSTEDT L, ABRAHAM-NORDLING M, LUNDELL G, TORRING O. TSH-receptor autoimmunity in Graves' disease after therapy with anti-thyroid drugs, surgery, or radioiodine: a 5-year prospective randomized study. *Eur J Endocrinol* 2008;158:69-75.
7. GALLEGOS E, MEIER DA, GARCIA M. Graves' disease triggered by autoinfarction of an autonomously functioning thyroid adenoma. *J Nucl Med* 1997;38:260-2.

Sažetak

RAZVOJ GRAVESOVE BOLESTI NAKON LIJEČENJA TOKSIČNOG ADENOMA APLIKACIJOM I131

J. Martinko, M. Cigrovski-Berković, B. Bečejac, D. Solter i M. Solter

Prikazuje se slučaj bolesnice u koje se nakon aplikacije I131 za liječenje toksičnog adenoma razvila Gravesova bolest. Razvoj autoimune bolesti nakon terapije radiojodom nije uobičajeni slijed, a najvjerojatnije je posljedica otkrivanja antigenih domena na TSH-receptoru koje nastaju kao posljedica njegove manipulacije.

Ključne riječi: *Štitnjača, tumori; Adenomi; Radioterapija; Jodni radioizotopi; Gravesova bolest*

