

HORSESHOE LUNG ASSOCIATED WITH DIAPHRAGMATIC HERNIATION OF THE LIVER

Biserka Čičak¹, Iva Mihatov-Štefanović¹, Renata Vrsalović¹, Nenad Babić²
and Karmen Markičević-Ružičić¹

¹University Department of Pediatrics, ²University Department of Radiology, Sestre milosrdnice University Hospital, Zagreb, Croatia

SUMMARY – Horseshoe lung is a rare congenital pulmonary anomaly in which the caudal and basal segments of the left and right lungs are joined together behind the pericardium at the height of cardiac apex. Most patients with horseshoe lung have many other cardiovascular anomalies typical of the scimitar syndrome or the hypogenetic right lung syndrome. We report on a patient with horseshoe lung not associated with scimitar syndrome, but presented with a focal diaphragmatic herniation of the liver, such as never reported before in case of horseshoe lung without associated scimitar syndrome.

Key words: *Lung abnormalities; Lung – embryology; Lung – pathology; Hernia diaphragmatic – diagnosis; Liver diseases – diagnosis; Scimitar syndrome – diagnosis; Case report*

Introduction

Horseshoe lung is a rare congenital pulmonary anomaly characterized by fusion of the posterobasal segments of the right and left lungs behind the pericardium and in front of the aorta and the spine at the height of cardiac apex¹⁻³. The anomaly was first reported by Spencer in 1962 and it is indeed a rare clinical finding². So far, forty-odd such cases have been reported, largely associated with scimitar syndrome, with unilateral hypoplasia also frequently present, mostly of the right lung, which is without normal fissures and lobes, whereas the left lung is normally formed^{1,3}. The arterial supply of the right lung often takes place from the hypoplastic right lung artery or from an anomalous artery stemming from the descending aorta¹. In patients with horseshoe lung, tracheal and bronchial stenosis and anomalous bronchial bifur-

cation are also reported^{4,5}. Many patients with horseshoe lung and associated anomalies have respiratory symptoms, which tend to exacerbate and require surgical treatment, whereas a smaller number of patients are asymptomatic and need no surgery^{1,6,7}.

We report on a case of a boy with horseshoe lung and associated hypoplasia of the right lung, hypoplasia of the right lung artery, anomalous supply of the right lung from systemic circulation, anomalies of the right bronchial tree, but without anomalous venous drainage from the right lung to the inferior vena cava, typical of scimitar syndrome. The boy presented with focal herniation of the liver through a diaphragmatic defect, such as never reported before in case of horseshoe lung without scimitar syndrome, only in a couple of scimitar syndrome cases^{8,9}.

Case Report

Here we report on a case of a boy aged 2 years and 5 months admitted to our hospital for because of a pathological finding on his chest x-ray in the form of an ovoid formation of soft tissue density, paraverte-

Correspondence to: *Biserka Čičak, MD, MS*, University Department of Pediatrics, Sestre milosrdnice University Hospital, Vinogradska c. 29, HR-10000 Zagreb, Croatia
E-mail: biserka.cicak1@zg.t-com.hr

Received February 15, 2010, accepted August 2, 2010

brally to the right, and for further diagnostic procedures required. The boy was delivered from a pregnancy maintained by tocolytics; the birth took place in the 36th week of gestation, birth mass 2.7 kg. Upon delivery, he was kept in the maternity hospital for about ten days because of prematurity and perinatal infection. At the age of 4 months, he was hospitalized for obstructive bronchitis, bronchopneumonia and a suspected cardiac defect (atrial septal defect). Based on noninvasive procedures (echocardiography and radiocardiography), the existence of a cardiac defect was eliminated. Chest x-ray taken on that occasion showed a homogeneous shadow located in the right phrenicocardiac corner, interpreted as a pneumonic infiltrate.

Before hospitalization, the boy was treated on several occasions for obstructive bronchitis with salbutamol, antibiotics, parenteral and inhalant corticoids, and a month before admission permanent therapy was introduced with the inhalant corticoid, fluticasone propionate. Two days before admission, the boy was presented again with difficult breathing, so chest x-ray was taken at the local hospital, showing an ovoid formation of soft tissue density and open etiology at the lower contour of the cardiac shadow paravertebrally on the right, for which further treatment was recommended. On admission, the boy was well developed,

75 centiles for age, and somewhat undernourished for his age, body mass index 13.87 kg/m². Clinical status was satisfactory except for the systolic murmur at the left edge of the sternum, grade II/VI, of musical character. Blood pressure was 95/60 mm Hg. The echocardiogram was normal. Normal pulmonary venous return into the left atrium, as well as normal flow in the pulmonary artery 1.1 m/s on the valvula. Pulmonary x-ray was taken transcidentally, partly in the spinal projection and towards the right hemithorax, showing a shadow of soft tissue intensity and about 4 cm in size, on the profile image placed supradiaphragmatically and retrocardially, with open etiology (**Fig. 1**).

Thoracic and abdominal magnetic resonance imaging (MRI) indicated an atypically formed liver, whereas a portion of the right ovoid-shaped and about 3-cm diameter lobe appeared in the region of the right thorax para-aortally and paravertebrally. The shape of the described part suggested diaphragmatic herniation of the liver. The relatively wide blood vessel started from the aorta roughly at the height of the celiac trunk exit, directed dorsally and cranially along the described herniated portion of the liver parenchyma and then proceeding to the lung parenchyma where it branched out (**Fig. 2**).

Considering the finding of an aberrant artery from the abdominal aorta, which entered the lung paren-

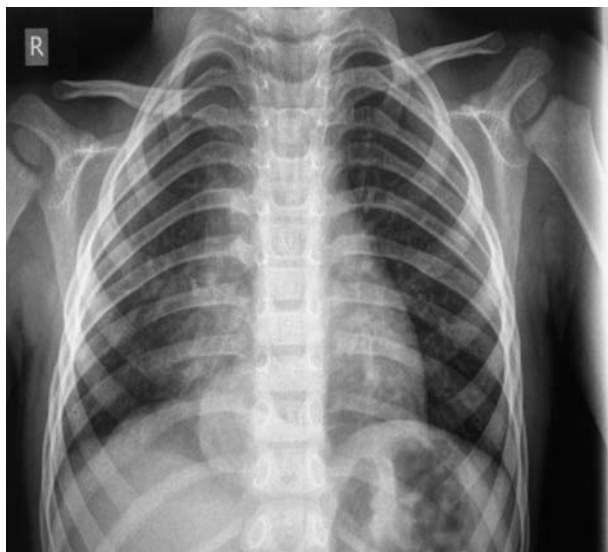

Fig. 1. Chest x-ray: ovoid shadow of about 4 cm in size and soft tissue density located supradiaphragmatically to the right.

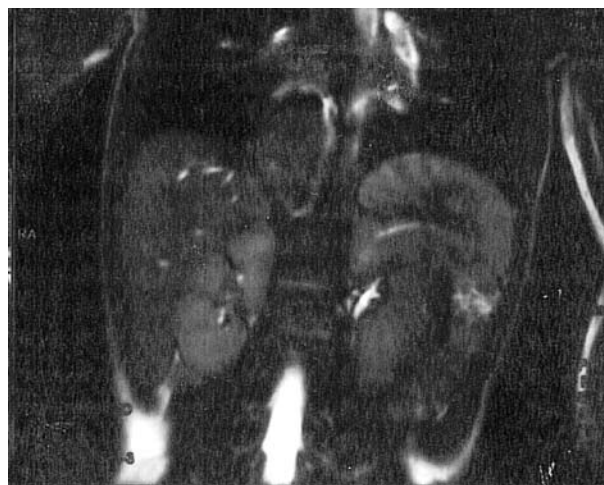

Fig. 2. Magnetic resonance imaging indicated herniation of a portion of the liver in the right thoracic base region, as well as an aberrant artery leading from the abdominal aorta and proceeding towards pulmonary parenchyma.

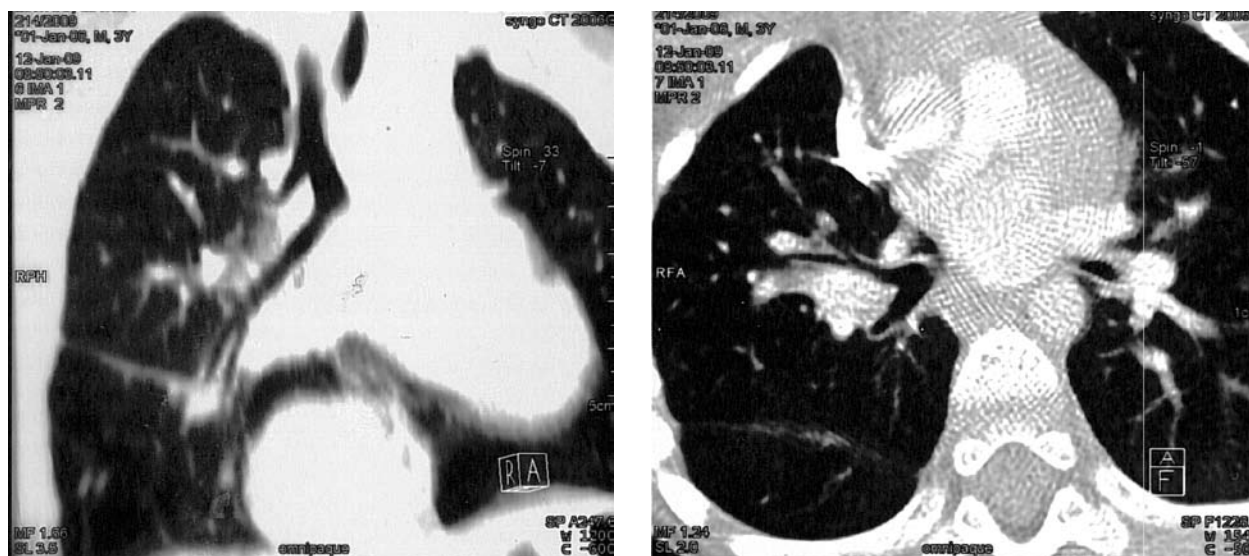


Fig. 3. Multislice computed tomography: anomalies of the right bronchial tree.

chyma, a case of pulmonary sequestration was suspected, so multislice computed tomography (MSCT) and angiography of the aorta were made. MSCT pointed to the right lung, which appeared smaller in relation to the left lung, with discrete dextroposition of the heart. Many anomalies of the right bronchial tree were present. The bronchus for the superior lobe of the right lung was branching directly from the trachea, the bronchus for the middle lobe was branching from the right main bronchus, which should normally diverge, whereas from the bronchus for the middle lobe two more caudally directed segmental bronchi were branching, with their position primarily corresponding to the bronchi for the anterior and medial segment of the inferior lobe in normal lungs (Fig. 3). The parenchyma of the right lung was normally ventilated and showed no signs of sequestration. In the caudal part of the thorax, pulmonary parenchyma extended behind the heart and was in contact with the left lung forming the horseshoe lung (Fig. 4). The described segment of the liver herniating through a diaphragmatic defect was shown in the right thorax paravertebrally and paramediastinally (Fig. 5). The right pulmonary artery was about 7 mm in diameter and a little narrower than the left one, which was 9–10 mm in diameter. As far as possible to analyze, pulmonary arteries were normally branching out into the lungs. From the aorta, at the height of celiac trunk to the right, a wide 4-mm diameter artery was branch-

ing, cranially directed, passing through the diaphragm and supplying the portion of the inferior lobe of the right lung separated by the described interlobus from the rest of the right lung (Fig. 5). In the lung base region on the right, somewhat wider pulmonary veins were observed, and the inferior pulmonary vein on the right was widened, probably due to the abundant systemic supply of this part of the lung from the aorta.

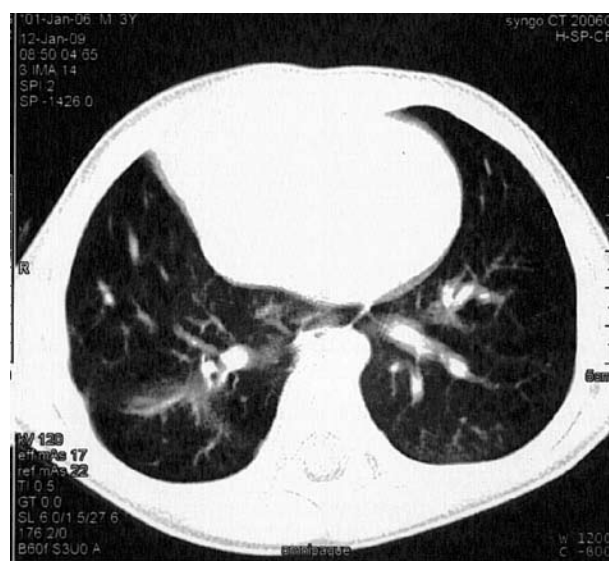


Fig. 4. Multislice computed tomography: pulmonary parenchyma isthmus in the caudal part of the thorax extending along the central line, connecting the left and right lungs, forming the horseshoe lung.

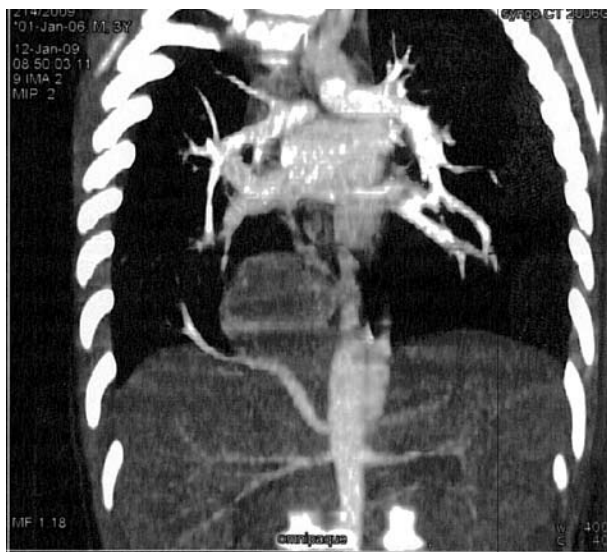

Fig. 5. Multislice computed tomography (MSCT): the herniated part of the liver in the right thorax. MSCT angiography: the anomalous systemic artery branching from the aorta at the height of the celiac trunk, 4 mm in diameter, cranially directed, passing through the diaphragm and supplying a portion of the inferior lobe of the right lung.

Normal pulmonary venous return into the left atrium with no anomalous pulmonary venous return found.

Discussion

Horseshoe lung is a rare congenital pulmonary anomaly. So far, some 40-odd cases have been reported, characterized by the pulmonary parenchyma isthmus extending behind the pericardium along the central line at the height of cardiac apex and in front of the esophagus and the spine¹⁻³. Horseshoe lung is often (in roughly 48% of cases) accompanied by unilateral hypoplasia, mostly of the right lung³. What also stems from the right lung is the isthmus, which receives blood from the right pulmonary artery, and the bronchi from the right bronchial tree^{10,11}. Pulmonary parenchyma in the isthmus is histologically normal¹². The isthmus also has its own pleural membrane, which is incomplete and allows for communication between the left and right pleural cavities¹².

Along with the hypoplastic right lung, one can also often find anomalies of the right bronchial tree and right pulmonary artery, which is usually hypoplastic,

in some cases altogether absent, and in 40% of cases normal¹³. Dextrocardia and rotation of the heart is the result of and directly proportional to the degree of hypoplasia of the right lung¹⁴.

Horseshoe lung is an exceptionally rare anomaly, which, however, is largely reported in association with scimitar syndrome^{15,16}. Out of the 40-odd cases of horseshoe lung reported to date, more than 80% occur with the scimitar syndrome^{1,6,17}, and in 15% of cases scimitar syndrome is associated with horseshoe lung^{1,14}. This syndrome is characterized by complex cardiovascular anomalies and its basic characteristic is partly anomalous venous drainage from the right lung into systemic veins, usually into the inferior vena cava^{1,14,18}. The systemic arterial supply of the right lung often occurs *via* one or more blood vessels coming from the abdominal aorta, passing through the right diaphragm and reaching the base of the right lung^{19,20}.

Congenital cardiac defects occur in 25% of patients with horseshoe lung and scimitar syndrome; in half of the cases, it is the *secundum* type atrial septal defect, and the second in frequency is ventricular septal defect. Also reported are persistent arterial duct, tetralogy of Fallot and aortic coarctation^{16,18,19}. Non-cardiac malformations reported in association with scimitar syndrome or horseshoe lung are Bochdalek hernia, hemidiaphragm eventration, accessory diaphragm, focal diaphragmatic defect, and hemivertebrae¹⁶. While chest x-ray often suffices for the diagnosis of scimitar syndrome, the diagnosis of horseshoe lung cannot be made with conventional chest x-ray. MSCT is the best noninvasive method to show the pulmonary parenchyma isthmus between the caudal parts of the lungs behind the pericardium but in front of the thoracic spine¹¹. Therefore, MSCT indicates a continuity of the right and left lungs behind the heart and is used in detecting diaphragmatic anomalies such as hernia or an accessory band^{16,21}.

Angiographic studies are used to visualize the right pulmonary arteries with a varying degree of hypoplasia¹¹. Pulmonary vascularization can be shown by means of MSCT or MRI (angiotomography or angioresonance)²¹. Cardiac catheterization and angiography are not indispensable for the diagnosis and are reserved for patients with suspected pulmonary hypertension²².

We have reported here on a case of horseshoe lung associated with mild hypoplasia of the right lung and right pulmonary artery, and the resulting discrete dextrocardia. The patient also showed many anomalies of the right bronchial tree and blood inflow from the systemic circulation into the right lung *via* an anomalous artery from the descending aorta, which caused an extracardiac left-right shunt.

The cases of horseshoe lung, reported largely within the scimitar syndrome, are also frequently associated with the above described anomalies^{11,13,15}. Such patients are often described with a congenital cardiac defect, not found in our patient. Focal diaphragmatic herniation of the liver, shown on chest x-ray as a soft tissue mass in the inferior paraspinal region, is reported in several patients with the scimitar syndrome^{8,9}.

In our patient, it was the finding of the above mentioned soft tissue mass on chest radiograph that prompted us to apply additional diagnostic procedures, MRI, MSCT, which were instrumental in detecting the above described anomalies and diaphragmatic herniation of the liver. Normal inflow of pulmonary veins into the left atrium excluded scimitar syndrome in our patient.

We find this case interesting in view of the fact that horseshoe lung findings without scimitar syndrome have been rarely reported so far. On the other hand, diaphragmatic herniation of the liver has been reported in several cases of scimitar syndrome, but never associated with horseshoe lung not involving an anomalous pulmonary venous drainage^{8,9}.

Patients with horseshoe lung may be asymptomatic, but early symptoms occur in patients with cardiac defect or serious picture of pulmonary hypoplasia or atresia^{1,17}. Children with horseshoe lung diagnosed in infancy often have serious cardiac symptomatology or respiratory insufficiency due to associated cardiac anomalies or pulmonary hypertension caused by a significant shunt^{1,6,23}. Horseshoe lung as well as scimitar syndrome can be manifested as recurrent infections, and in 50% of cases as a left-right shunt or progressive pulmonary hypertension^{5,12,24}.

Surgical treatment is indicated in cases involving persistent infections, hemoptysis, congestive cardiac disease or pulmonary hypertension caused by a significant shunt^{25,26}. Resection of a hypoplastic lung and isthmus is recommended in case of persistent chronic

infections. In cases involving a significant left-right shunt due to blood inflow from descending aorta *via* an anomalous blood vessel through the diaphragm into the right lung, treatment by ligature or embolization of the anomalous artery or lobectomy are applied^{25,26}. Anastomosis of the scimitar vein to the left atrium is recommended in the event of a significant shunt, otherwise it is not indicated^{19,20,24}.

In asymptomatic patients without pulmonary hypertension or recurrent pulmonary infections, surgical treatment is not applied, and monitoring and conservative treatment are recommended instead²⁷. The same applies to our patient who showed no signs of pulmonary hypertension or serious recurrent bronchopulmonary infections, so he has just been subjected to conservative treatment and regular follow up. What should always be kept in mind in this regard is that the asymptomatic horseshoe lung is also potentially dangerous due to the communication between the two pleural cavities, so pneumothorax, if developed in such patients, will be inevitably bilateral²².

On differential diagnosis of horseshoe lung, primary attention should be paid to pseudohorseshoe lung resulting from inflammatory changes such as necrotizing pneumonia, or from destruction of pulmonary parenchyma, which leads to compensatory hypertrophy of the other lung and largely occurs in pediatric population²⁸.

Today it is known that horseshoe lung can be compatible with normal lifestyle¹. The diagnosis of horseshoe lung can currently be easily made by means of MSCT, and such cases are considered to be more frequent but clinically less portentous than earlier thought²².

References

1. FREEDOM RM, BURROWS PE, MOES CAF. "Horseshoe" lung: report of five new cases. *AJR Am J Roentgenol* 1986;146:211-5.
2. SPENCER H. *Pathology of the lung*, 3rd ed. Oxford: Pergamon Press, 1977:83.
3. LUTTERMAN J, JEDEIKIN R, CLEVELAND DC. Horseshoe lung with left lung hypoplasia and critical pulmonary venous stenosis. *Ann Thorac Surg* 2004;77:1085-7.
4. DISCHE MR, TEIXEIRA ML, WINCHESTER PH, ENGLE MA. Horseshoe lung associated with a variant of the "scimitar" syndrome. *Br Heart J* 1974;36:617-20.

5. CIPRIANO P, SWEENEY LJ, HUTCHINS GM, ROSENQUIST GC. Horseshoe lung in an infant with recurrent pulmonary infections. *Am J Dis Child* 1975;129:1343-5.
6. TAKEDA K, KATO N, NAKAGAWA T, AOKI K, MATSUDA A. Horseshoe lung without respiratory distress. *Pediatr Radiol* 1990;20:604.
7. HASSBERG D, STEIL E, SIEVERDING L, ROSENDAHL W. Kombination von Scimitar-Syndrome und Hufeisenlunge. Ein seltener aber typischer Befund-Fallbericht und Literaturübersicht. *Klin Padiatr* 1992;204:434-43.
8. AHAMED FM, AI HAMEED F. Hypogenetic lung syndrome in an adolescent: imaging findings with short review. *Ann Thorac Med* 2008;3:60-3.
9. KUSUMOTO S, HOSHI H, KOGA K, MIZOGUCHI N, WATANABE K. Scimitar syndrome associated with diaphragmatic herniation of the liver. *Radiat Med* 1987;5:48-50.
10. HAWASS ND, BADAWI MG, AI-MUZRAKCHI AM, AI-SAMMARAI AI, JAWAD AJ, ABDULLAH MA, BAHAKIM H. Horseshoe lung: differential diagnosis. *Pediatr Radiol* 1990;20:580-4.
11. MATUSHITA JPK, MISSIAGGIA GC, PEIXOTO RMA, FILHO HMA, DIAS RS, TAVARES WC Jr, *et al.* Horseshoe lung: a case report. *Radiol Bras* 2007;40:359-61.
12. HAWORTH SG, SAUER U, BUHLMEYER K. Pulmonary hypertension in scimitar syndrome in infancy. *Br Heart J* 1983;50:182-9.
13. KITTLE CF, CROCKETT JE. Vena cava bronchovascular syndrome: a triad of anomalies involving the right lung: anomalous pulmonary vein, abnormal bronchi and systemic pulmonary arteries. *Ann Surg* 1962;156:222-33.
14. FRANK JL, POOLE CA, ROSAS G. Horseshoe lung: clinical, pathologic and radiologic features and a new plain film finding. *AJR Am J Roentgenol* 1986;146:217-26.
15. MÄNNER J, JAKOB C, STEDING G, FÜZESI L. Horseshoe lung: report on a new variant – “inverted” horseshoe lung with embryological reflections on the formal pathogenesis of horseshoe lungs. *Ann Anat* 2001;183:261-5.
16. GODWIN DJ, TARVER RD. Scimitar syndrome: four new cases examined with CT. *Radiology* 1986;159:15-20.
17. CERRUTI MM, MARMOLEJOS F, CACCIARELLI T. Bilateral intralobar pulmonary sequestration with horseshoe lung. *Ann Thorac Surg* 1993;55:509-10.
18. MORGAN JR, FORKER AD. Syndrome of hypoplasia of the right lung and dextroposition of the heart: “scimitar sign” with normal pulmonary venous drainage. *Circulation* 1971;43:27-30.
19. KIELY B, FILLER J, STONE S, DOYLE EF. Syndrome of anomalous venous drainage of the right lung to the inferior vena cava: a review of 67 reported cases and three new cases in children. *Am J Cardiol* 1967;20:102-16.
20. FOLGER GM Jr. The scimitar syndrome. Anatomic, physiological, developmental and therapeutic considerations. *Angiology* 1976;27:373-407.
21. TAKAHASHI M, MURATA K, YAMORI M, OKUNO M, NAKAGAWA M, MORIM, *et al.* Horseshoe lung: demonstration by electron-beam CT. *Br Radiol J* 1997;70:964-6.
22. DUPUIS C, VAKSMANN G, REMY-JARDIN M, FRANCCART C. Horseshoe lung and scimitar syndrome in an asymptomatic child. *Eur Heart J* 1994;15:1008-9.
23. DUPUIS C, CHARAF LA, BREVIERE GM, ABOU P. “Infantile” form of the scimitar syndrome with pulmonary hypertension. *Am J Cardiol* 1993;71:1326-30.
24. MATHEY J, GALEY JJ, LOGEAYS Y, SANTORO E, VANETTI A, MAUREL A, *et al.* Anomalous pulmonary venous return into inferior vena cava and associated bronchovascular anomalies (the scimitar syndrome). *Thorax* 1968;23:398-407.
25. WANG CC, WU ET, CHEN SJ, LU F, HUANG SC, WANG JK, *et al.* Scimitar syndrome: incidence, treatment, and prognosis. *Eur J Pediatr* 2008;167:155-60.
26. THIBAUT C, PERRAUL LP, DELISLE G, CARTIER PC, CLOUTIER A, HOUDE C, *et al.* Lobectomy in the treatment of the scimitar syndrome. *Ann Thorac Surg* 1995;59:220-1.
27. CORNO A, ROSTI L, MACHADO I. Horseshoe lung associated with anomalous pulmonary venous connection without pulmonary hypoplasia. *Cardiol Young* 1995;5:91-3.
28. SINGH N, AGARWAL R, GUPTA D. Pseudohorseshoe lung. *Can Med Assoc J* 2008;4:178.

Sažetak

POTKOVASTA PLUĆA UDRUŽENA S HERNIJACIJOM JETRE KROZ DIJAFRAGMU

B. Čičak, I. Mihatoš-Štefanović, R. Vrsalović, N. Babić i K. Markičević-Ružičić

Potkovasta pluća su rijetka kongenitalna anomalija pluća u kojoj su spojeni stražnji i bazalni segmenti lijevog i desnog pluća iza osrčja u visini srčanog vrha. Većina bolesnika s potkovastim plućima ima brojne druge kardiovaskularne anomalije tipične za sindrom *scimitar* ili sindrom hipoplastičnog desnog pluća. Prikazujemo bolesnika s potkovastim plućima koja nisu udružena sa sindromom *scimitar*, ali je prisutna fokalna hernijacija jetre kroz dijafragmu koja nije dosad opisana uz potkovasta pluća bez pridruženog sindroma *scimitar*.

Ključne riječi: *Plućne nenormalnosti; Pluća – embriologija; Pluća – patologija; Hernija dijafragme – dijagnostika; Jetrene bolesti – dijagnostika; Sindrom scimitar – dijagnostika; Prikaz slučaja*

