

# Treatment of Infected Tibial Nonunion with Bone Defect Using Central Bone Grafting Technique

Gordan Gulan<sup>1</sup>, Zdravko Jotanović<sup>1</sup>, Hari Jurdana<sup>1</sup>, Branko Šestan<sup>1</sup>, Saša Rapan<sup>2</sup>, Dušan Rubinić<sup>1</sup> and Jagoda Ravlić-Gulan<sup>3</sup>

<sup>1</sup> University of Rijeka, School of Medicine, Lovran Clinic for Orthopaedic Surgery, Lovran, Croatia

<sup>2</sup> »J.J. Strossmayer« University, Osijek University Hospital Center, Department of Orthopaedic Surgery, Osijek, Croatia

<sup>3</sup> University of Rijeka, School of Medicine, Department of Physiology and Immunology, Rijeka, Croatia

## ABSTRACT

*Treatment of infected tibial nonunion with bone defect represents a challenge for every orthopaedic surgeon. Various methods of treatment have been described for nonunions with infection, bone loss or both. One of them is the central bone grafting technique, which is a safe and effective treatment for nonunions of the tibia. The technique involves placement of autogenous cancellous bone from the iliac crest on the anterior surface of the interosseous membrane with the aim of creating a tibiofibular synostosis. We present the results of uncontrolled, retrospective and continuous series of ten patients treated by a central bone grafting technique for infected tibial nonunion with bone loss. Mean follow-up period was 12 (10–15) years. Most injuries were a result of war injuries. Clinically and radiologically confirmed bony healing with total consolidation of the graft was achieved in all patients within a period of 10–12 months without further bone grafting. The newly-formed bone mass was able to fulfil the mechanical and functional demands of everyday life activities. Once again, the central bone grafting technique has shown to be a safe, reliable and effective method of treatment for infected tibial nonunion with bone defect.*

**Key words:** tibial nonunion, infection, bone defect

## Introduction

The treatment of infected tibial nonunions is very demanding for every surgeon, especially when associated with large bone defect. Nonunion is more common in the tibia than in any other bone<sup>1</sup>, particularly after high energy trauma with soft tissue injury and bone defect<sup>2</sup>. The presence of an infection prolongs the period of treatment and makes prognosis even worse<sup>3</sup>. Patients with tibial nonunion have several problems: the treatment lasts several years, many of them have repeated surgeries, and the biggest difficulty is muscle atrophy in the lower leg. Many patients completely lose confidence in medical care after many months or even years of treatment; they are discouraged and depressed<sup>4</sup>. The outcome is doubtful and often ends in the amputation of the extremity.

Many techniques have been used in the treatment of infected tibial nonunions, such as the bone grafting, vascularised fibular graft, distraction osteogenesis and induced membrane technique<sup>5–9</sup>. Milch was the first who describe the creation of a tibiofibular synostosis as a

treatment possibility for tibial nonunion<sup>10</sup>. Eight years later, Phemister confirmed the creation of a tibiofibular synostosis after bone grafting<sup>11</sup>. Since then, many authors have used autologous bone grafts as a method of treatment for infected tibial nonunion, using posterolateral approach to the tibia with placement of bone graft on the posterior surface of the interosseous membrane<sup>12–14</sup>.

In this article we present the results of uncontrolled, retrospective and continuous series of ten patients treated by a central bone grafting technique for infected tibial nonunion with bone loss. Mean follow-up period was 12 (10–15) years.

## Material and Methods

### Patients

Ten patients were treated in our Clinic over seven years, from 1991 to 1998. Nine of them had a war injury

and one case was the consequence of a motorcycle accident. The original injuries of all patients were complex open tibial fractures and were consequently classified according to the Gustilo-Anderson open fractures classification<sup>15,16</sup> as type IIIA (eight patients) or type IIIB (two patients). They all had infected tibial nonunion with bone defect. Moreover, all wounds had purulent drainage, positive bacterial culture from the depths of the wounds and intact periosteal coverage. Three patients had a skin defect. The average width of the bone defect was 4 cm (2–7). All the injured were males, with an average age of thirty years (22–51). Eight patients had been referred from other hospitals, after an average period of 14 months (2–20). Two patients were initially treated in our Clinic with the central bone grafting technique. The eight patients were operatively treated several times: four of them had an external fixation, two had an AO plate (previously done osteosynthesis with spongioplasty because of minimal bone defect) and two were proposed for amputation. When they were admitted in our Clinic, seven patients had active osteomyelitis with a fistula and purulent discharge, and the other three had a contaminated skin defect. The lower leg skin showed signs of atrophy and dark pigmentation with scars, especially on its front and medial side.

The treatment was performed in two phases. The first stage consisted in removal of all osteosynthetic material, necrotised tissue and parts of the necrotic bone, even though it left huge bone defects. The involved tibia is than stabilized with external fixator. The wound was left open and cleaned every day with antibacterial sponges. After the appearance of granulations and a sterile smear, Thiersch split-thickness skin graft (STSG) was done in one IIIA and full-thickness skin graft (FTSG) in two IIIB patients. This technique of soft tissue coverage has been employed in an austere environment where access to complex equipment and plastic surgeons was limited because of war circumstances. In the other seven patients the wound was closed secondarily. All patients received antibiotic therapy according to bacteriologic culture re-

sults. After satisfactory STSG or FTSG adaptation and disappearance of all clinical and laboratory signs of infection, we proceeded to the second phase, when we harvested autologous cancellous grafts from the iliac crest and placed them into the bony defects. The lower extremity is postoperatively elevated by the external fixator until the oedema has subsided and the edges of the wound sealed. The patient is than discharged from the hospital with permission of walking using crutches but not allowed to bear weight on the involved leg. Partial weight-bearing is allowed when the radiographical criteria for early consolidation have been met.

### Surgical technique

We put the patient on the operating table in a lateral position, without a tourniquet. The involved leg and the ipsilateral anterior iliac crest were prepared and draped. A skin incision was made parallel and slightly anterior to the fibula. If the skin incision extended to the full length of the lower leg, attention was directed to preserving the superficial and common peroneal nerves. The crural fascia was incised in the same line and length as the skin incision.

With blunt dissection, we exposed the interval between the peroneal muscles and the extensor digitorum muscle, thus exposing the fibula and the interosseous membrane as well. The muscles and the neurovascular bundle of the anterior compartment were elevated ventrally from the anterior aspect of the interosseous membrane to expose the lateral aspect of the tibia proximal and distal to the nonunion. The tibial periosteum was then incised longitudinally just anterior to the line of attachment of the interosseous membrane. Both the interosseous membrane and the tibial periosteum were then elevated in one layer from the dorsolateral edge and the dorsal surface of the tibia. Subsequently an incision of the interosseous membrane was made close to its fibular attachment, with special care to avoid injury of fibular blood vessels. The interosseous membrane and the periosteum of the posterior tibial surface were displaced pos-

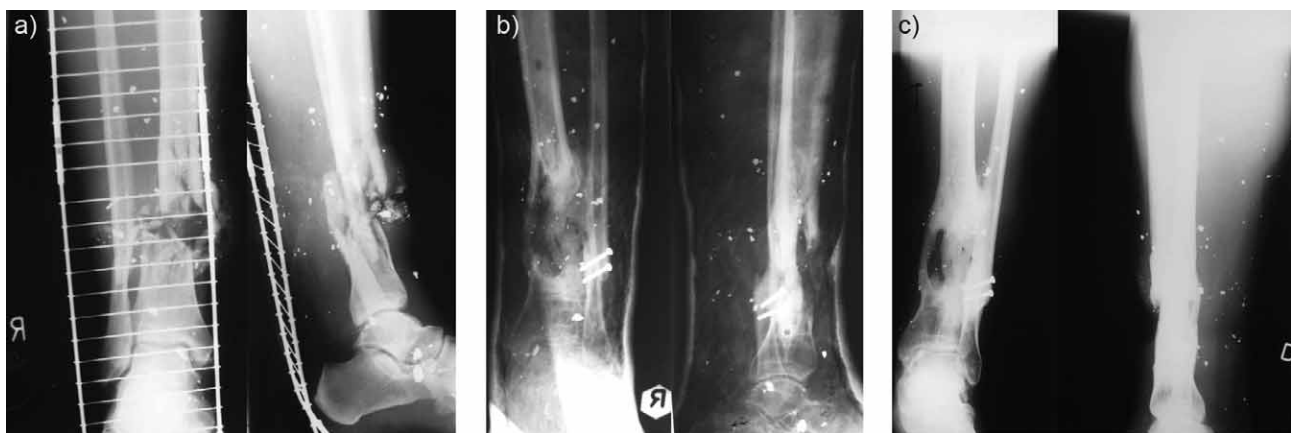


Fig. 1. A 34-year old man sustained a type IIIB open tibial fracture as a result of war injury. Anteroposterior and lateral radiographs show a) the fracture after initial injury, b) ten months after central bone grafting (stabilisation with above the knee cast), and c) five years after central bone grafting.

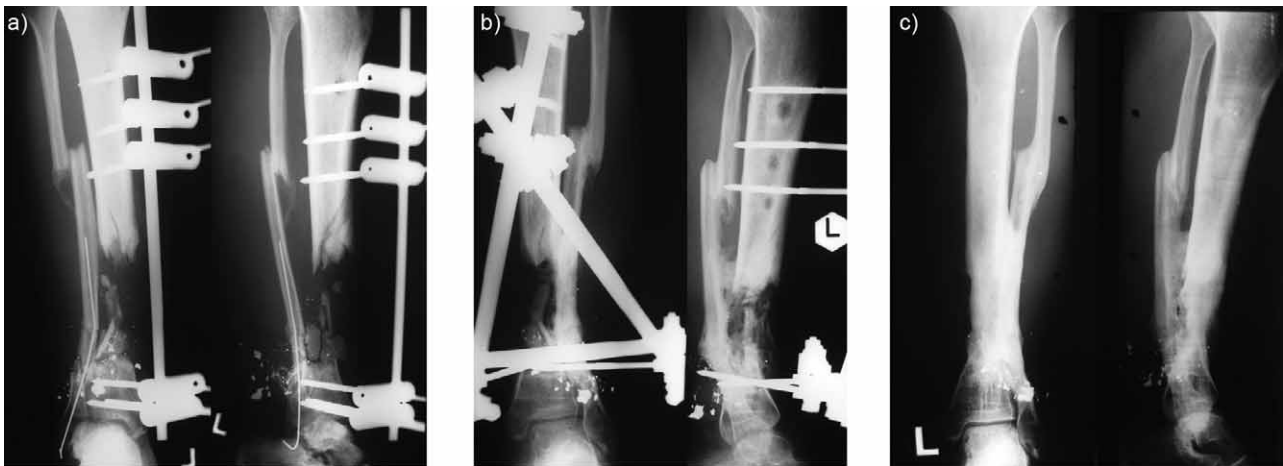


Fig. 2. A 25-year old man sustained a type IIIB open tibial fracture as a result of war injury. Anteroposterior and lateral radiographs show a) the fracture after initial injury, b) seven months after central bone grafting, and c) fifteen years after central bone grafting with marked tibial recurvatum of 25 degrees.

teriorly and the remaining periosteum was elevated from the lateral tibial surface. In this way we obtained a gutter, bounded medially by the lateral surface and lateral border of the tibia, dorsally by the interosseous membrane and periosteum of the posterior tibial surface, and laterally by the medial surface of the fibula in which the autologous cancellous bone graft was to be inserted.

After completing this phase of the operation, we used a chisel to obtain a cancellous bone graft from the outer layer of the anterior iliac crest in the form of chips of different sizes and forms, with which we filled the central space in the form of a gutter. We then proceeded to closure of the crural fascia, subcutaneous tissues and the skin without using suction drain. Stabilization of the bony fragments was performed with an above-the-knee cast (Figure 1) in eight patients, while in the two patients initially treated in our Clinic it was performed by external fixation (Figure 2).

#### *Postoperative rehabilitation protocol and assessment of the functional status*

All patients were bended until soft tissue healing. After wound healing and adequate fragment union, which was radiologically confirmed, patients were allowed partial weight-bearing to about 10 kg. When there was adequate stability, the cast was removed and the weight-bearing increased. Clinical healing is defined as the ability of full weight bearing of the leg without orthopaedic devices and without pain<sup>17</sup>. Radiological bone healing was defined with total consolidation of the graft.

#### **Results**

Nine patients achieved clinical healing on average in 9 months (7–12). Radiologically confirmed bony healing with total consolidation of the graft was achieved in all patients in 10–12 months. Between the clinical and the radiological healing, the patients used one crutch. One

patient had a purulent secretion 2 months postoperatively, with positive findings on *Staphylococcus aureus*, so the application of antibiotics was prolonged. After complete healing, this patient had no problems.

One patient had instability of the pins that were used for external fixation, which was then removed and replaced with a circular cast. He was allowed total weight bearing, and had complete clinical consolidation in 10, and radiological in 12 months. One patient had 25 degrees of tibial recurvatum (see Figure 2). He was advised supramalleolar corrective osteotomy but he refused additional surgical procedure. Another patient had 5 degrees antecurvatum of the tibia. Two patients had valgus and three varus of the talocrural joint with the lateral distal tibial angle (LDTA) ranging from 82–92°, but without further need for supramalleolar corrective osteotomy. One patient had marked tibial recurvatum of 25 degrees; other nine patients had correct tibial alignment. All patients had terminal limited dorsal and plantar flexion of the talocrural joint. None of the patients had instability of the ankle. Three patients who were provided with an above-the-knee cast had knee flexion contracture (up to 25 degrees) which was resolved with intensive physical therapy. The overall length of follow-up was 10–15 years.

#### **Discussion and Conclusion**

Rijnberg and Van Linge first described the method in which the tibia is approached laterally through the tissues. Partial detachment of the periosteum and the interosseous membrane from the tibia and the fibula with their posterior displacement creates a big enough space between the two bones for filling in bone graft and maintaining it in place. The aim of this procedure is to heal the bone at the very place of a bone defect, with the bone graft placed centrally in the space between the tibia and the fibula growing and creating new bone. The overall re-

sult of this kind of treatment is the creation of a bone bridge above, below or at the level of the bone defect<sup>4</sup>.

We chose this kind of treatment for our patients because of the previously described successful management of diaphyseal defects of the tibia<sup>4,18</sup> without the need for sophisticated skeletal fixation. Three patients had a skin defect and two of them were suggested, in another hospital, for amputation. Instead of amputation, we treated them first for their skin problems (with STSG or FTSG) and infection, and then with the central bone grafting technique, on account of absence of any significant neurological deficit, intact major muscle groups and satisfactory vascular supply, and their general status. From today's point of view, this kind of wound treatment in these three patients with skin defect may not be applicable to the contemporary orthopaedic surgeons practice. This technique has been employed in an austere environment where access to complex equipment and plastic surgeons was limited.

We slightly modified the original technique of central bone grafting<sup>4</sup>. The position of the patient on the operating table was also lateral, but we took bone graft from the anterior rather than the posterior aspect of the iliac crest. The placement of the patient in a lateral position enables approach not just to the lateral side of the lower leg and the anterior iliac crest, but also to the posterior iliac crest. So, if a bigger amount of bone graft for treating a larger bone defect is needed, it can be taken from the anterior and the posterior iliac crests in the same act. Instead of corticocancellous bone strips and soft cancellous bone<sup>4</sup>, we took only cancellous bone. Moreover, we did not use a tourniquet, as described in the original paper<sup>4</sup>, during the second phase of treatment (central bone grafting) because of the already reduced vascular supply in our patients, which is one of the possible contraindications for the use of tourniquet during surgery. The volume of the graft affects the possibility to close the crural fascia after central bone grafting. In the original paper, the volume of the graft usually makes it impossible to close the crural fascia<sup>4</sup>. In our series of ten patients, we were always able to successfully close the crural fascia. This may be due to the fact that we used only cancellous bone, which is more adaptable, rather than a combination of cancellous and corticocancellous bone, as described in the original paper, and also to the amount used, which was always sufficient to promote healing by forming bony bridges. After surgery, Rijnberg and van Linge applied a long-leg cast for unstable or proximal nonunion and a below-knee cast for stable and distal nonunion<sup>4</sup>. After wound healing, they changed the cast for a long-leg near-skin cast. With adequate stability, they removed the cast and put a custom-made brace, dis-

carding it only when there was full union. In two patients who were treated initially in our Clinic with the central bone grafting technique, we chose external fixation for stabilisation of the nonunion because of grossly mobile tibias. We thought that it would maintain the mechanical axis of the tibia better with faster reconstruction. The other eight patients were given above-the-knee casts after central bone grafting. Fatigue fractures or secondary anatomical valgus or varus deformities are a main disadvantage of this procedure. Some malalignments were observed in these patients (one patient with 25 degrees of tibial recurvatum who refused additional surgical procedure) but without greater functional distress. Except this tibial recurvatum in one patient, we have not observed any fatigue fractures or secondary anatomical valgus or varus deformities in our patients.

As we applied this method to treat our patients for infected tibial nonunion with large bone defect, we completely agree with Rijnberg and van Linge about its effectiveness. It is told to be a reliable, safe and relatively easy procedure. The method is not a new one; it dates from 1939<sup>10</sup> and has been modified over time. Faced with war injuries which unfortunately cause expansive wounds, we used the central bone grafting technique during domestic war with some modification. With today's point of view, this is a pre-war technique with little relevance today. There is no comparison with any other method of treatment. Nowadays, the technique is well described in the literature. Our variation and sample size (ten cases) may seem minor. But despite all the foregoing limitations of this study, our results show that it can be applied with great success in cases of war injuries where the bone defect size is up to 6–7 cm in length. If there is osteomyelitis, thorough debridement is required. This technique also decreases the risk of infection recurrence, mainly due to the absence of metal implants. The newly-created central bone in all ten patients satisfies the mechanical and functional requirements of the patients' everyday activities.

We can conclude that treatment of infected tibial nonunion with bone defect represents a challenge for every orthopaedic surgeon. Various methods of treatment have been described for nonunions with infection, bone loss or both. One of them is the central bone grafting technique. Although the central bone grafting technique, from today's point of view, is a pre-war technique with little relevance today, our results show that it can be applied with great success in cases of war injuries where the bone defect size is up to 6–7 cm in length. Once again, the central bone grafting technique has shown to be a safe, reliable and effective method of treatment for infected tibial nonunion with bone defect.

## REFERENCES

1. BOYD HB, *Postgrad Med*, 36 (1964) 315. — 2. WISS DA, STETSON WB, *J Am Acad Orthop Surg*, 4 (1996) 249. — 3. NICOLL EA, *J Bone Joint Surg Br*, 46 (1964) 373. — 4. RIJNBERG WJ, VAN LINGE B, *J Bone Joint Surg Br*, 75 (1993) 926. — 5. CHRISTIAN EP, BOSSE MJ,

ROBB G, *J Bone Joint Surg Am*, 71 (1989) 994. — 6. AMR SM, EL-MOFTY AO, AMIN SN, *Microsurgery*, 22 (2002) 91. DOI: 10.1002/micr.21732. — 7. MARSH JL, PROKUSKI L, BIERMANN JS, *Clin Orthop*, 301 (1994) 139. DOI: 10.1097/00003086-199404000-00022. — 8. DENDRINOS GK, KON-



- TOS S, LYRITSIS E, J Bone Joint Surg Am, 77 (1995) 835. — 9. WOON CY, CHONG KW, WONG MK, J Bone Joint Surg Am, 92 (2010) 19. DOI: 10.2106/JBJS.I.00273. — 10. MILCH H, Surgery, 27 (1950) 770. — 11. PHEMISTER DB, J Bone Joint Surg Am, 29 (1947) 946. — 12. ESTERHAI JL Jr, SENNETT B, GELB H, HEPPENSTALL RB, BRIGHTON CT, OSTERMAN AL, LAROSSA D, GELMAN H, GOLDSTEIN G, J Trauma 30(1) (1990) 49. DOI: 10.1097/00005373-199001000-00008. — 13. SIMON JP, STUYCK J, HOOGMARTENS M, FABRY G, Acta Orthop Belg, 58(3) (1992) 308. — 14. LAMB RH, Clin Orthop Relat Res, 64 (1969) 114. — 15. GUSTILO RB, ANDERSON JT, J Bone Joint Surg Am, 58-A (1976) 453. — 16. GUSTILO RB, MENDOZA RM, WILLIAMS DN, J Trauma, 24 (1984) 742. — 17. CATTERMOLE HR, HARDY JRW, GREG PJ, Br J Sports Med, 30 (1996) 171. DOI: 10.1136/bjism.30.2.171. — 18. DE MEULEMEESTER C, VERDONK R, BONGAERTS W, Acta Orthop Belg, 58 (1992) 187.

G. Gulan

University of Rijeka, School of Medicine, Lovran Clinic for Orthopaedic Surgery, Šetalište Maršala Tita 1, 51415 Lovran, Croatia

e-mail: gordang@medri.hr

## LIJEČENJE INFICIRANIH NESRAŠTAVANJA GOLJENICE UDRUŽENIH S DEFJEKTOM KOSTI METODOM SREDIŠNJEG POLAGANJA KOŠTANOG PRESADKA

### SAŽETAK

Liječenje inficiranog nesraštavanja goljenice udruženog s defektom kosti izazov je za svakog ortopeda. Opisane su različite metode liječenja nesraštavanja goljenice udružene s infekcijom, gubitkom dijela kosti ili onih koje su udružene s infekcijom i gubitkom kosti. Jedna od takvih opisanih metoda liječenja je i metoda središnjeg polaganja koštanog presadka, koja je sigurna i učinkovita metoda liječenja nesraštavanja goljenice. Ova metoda liječenja uključuje polaganje autogenog spongioznog koštanog presadka iz grebena bočne kosti na prednju površinu međukoštane opne potkoljenice s ciljem stvaranja koštanog spoja (sinostoze) između goljenice i lisne kosti. U ovom izvornom znanstvenom radu iznosimo rezultate nekontrolirane, retrospektivne i kontinuirane serije od deset bolesnika s inficiranim nesraštavanjem goljenice udruženim s defektom kosti liječenih metodom središnjeg polaganja koštanog presadka. Prosječni period praćenja bolesnika bio je 12 (10–15) godina. Većina ozljeda bila je posljedica ratnih ozljeda tijekom Domovinskog rata. Kliničko i radiološko koštano cijeljenje s konsolidacijom koštanog presadka u cijelosti je postignuto u svih deset bolesnika u periodu od 10–12 mjeseci bez naknadne potrebe za koštanim presadkom. Novostvorena koštana masa (sinostoza) bila je sposobna ispuniti mehaničke i funkcionalne zahtjeve aktivnosti svakodnevnog života bolesnika. Još jednom, metoda središnjeg polaganja koštanog presadka pokazala se sigurnom, pouzdanom i učinkovitom metodom u liječenju inficiranih nesraštavanja goljenice udruženih s defektom kosti.