

# The Carcinoid Tumour in Meckel's Diverticulum: How to Treat Young Adults with Appendicitis? – Case Report

Sanja Štifter<sup>1</sup>, Elvira Mustać<sup>1</sup>, Miljenko Lukanović<sup>2</sup>, Silvija Lukanović<sup>1</sup>, Jurica Fudurić<sup>4</sup>, Ana Šoštarić Zadro<sup>5</sup> and Zvonko Zadro<sup>3</sup>

<sup>1</sup> University of Rijeka, School of Medicine, Department of Pathology, Rijeka, Croatia

<sup>2</sup> University of Rijeka, Rijeka University Hospital Center, Surgical Clinic, Rijeka, Croatia

<sup>3</sup> University of Zagreb, School of Medicine, Department of Anatomy, Zagreb, Croatia

<sup>4</sup> Karlovac General Hospital, Department of Surgery, Karlovac, Croatia

<sup>5</sup> Karlovac General Hospital, Department of Radiology, Karlovac, Croatia

## ABSTRACT

*This case reports the concomitant and unexpected finding of carcinoid tumour within a Meckel's diverticulum presenting as an acute abdomen due to gangrenous appendicitis in a young adult male. Both Meckel's diverticula and carcinoid tumour are rare clinical entities, and carcinoid tumours occurring within a Meckel's diverticulum are even more uncommon. The initial clinical presentation of carcinoid tumours occurring in a Meckel's diverticulum is usually similar to that of appendiceal carcinoids. Carcinoid tumours are the most common primary tumour of the small bowel. They resemble appendiceal carcinoids to the extent that they are usually small, single, and asymptomatic. Surgical treatment of Meckel's diverticula is recommended procedure. By presenting this case we wished to stress the value of systematic identification and removal of the diverticulum during laparotomy and to underline the importance of exploration the Meckel's diverticulum particularly in case of young adult subjects.*

**Key words:** Meckel's diverticulum, carcinoid tumours

## Case Report

We present a case of unusual carcinoid presentation. Meckel's diverticulum is the most common anomaly of the gastrointestinal tract. Neoplasm's occurring within are extremely rare<sup>1</sup>. The accidental finding of a carcinoid tumour in Meckel's diverticulum, a very uncommon event, triggered a physiopathological and clinical analysis of this very interesting but very rare association. The value of systematic identification and removal of the diverticulum during laparotomy was underlined by some authors<sup>2</sup>. Our intention was to underline the significance of the Meckel's diverticulum exploration (which we feel is a bit underestimated) during laparoscopy, and particularly in cases of young subject. And we also as some authors favour the decision of its removal. Since, only the histological valuation excludes the presence of a carcinoid tumour that could give metastases to local or distant sites<sup>3</sup>.

Our case reports the concomitant and unexpected finding of carcinoid tumour within a Meckel's diverticulum presenting as an acute abdomen due to gangrenous appendicitis in an adult male.

The male patient was admitted to the hospital in urgency because of clinical and laboratory signs of acute abdomen. Laparotomy followed with appendectomy and removal of the Meckel's diverticulum was performed.

### *Pathology findings*

*Specimen labeled No 1.*

Appendix:

Macroscopic appearance; appendix was distended, 7cm long with transversal opening up to 1.5 cm. It's surface was partly glistening, and covered with fibrin. Histolo-

gically, all layers of the appendix were infiltrated with polymorphonuclears and the wall of appendix was partially necrotic.

#### *Specimen labeled No 2.*

Intestinum; 7cm long, with outpouch 2cm. On transversal section nodal mass was noted measuring up to 1 cm. Histologically, specimen revealed tumour under surface epithelium consisting small cells organised in the alveolar maner (Figure 1). Primary carcinoid tumour was suspected and immunohistochemically confirmed with chromogranin + positive staining (Figure 2).

### Discussion and Conclusion

Surgical treatment of Meckel's diverticula is recommended for children during exploration. However, resection is controversial in asymptomatic adults. Carcinoid tumours are the most common primary tumour of the small bowel<sup>4</sup>. They arise from enterochromaffin or enterochromaffin-like cells that are present in the gastrointestinal tract, ovaries, and lungs. When carcinoid tumours of the jejunum and ileum produce symptoms, the clinical presentation differs when compared to most other tumours in these sites<sup>5</sup>.

Both Meckel's diverticula and carcinoid tumour are rare clinical entities, and carcinoid tumours occurring within a Meckel's diverticulum are even more uncommon. The initial clinical presentation of carcinoid tumours occurring in a Meckel's diverticulum is usually similar to that of appendiceal carcinoids. The carcinoid of Meckel's diverticulum is a very rare lesion, and about 100 cases in the literature have been described. Most of these tumours are casually find out at autopsy or laparoscopy for other pathology<sup>6</sup>. They resemble appendiceal carcinoids to the extent that they are usually small, single and asymptomatic what was also present in our case. However, they have generally been likened to jejunoileal carcinoids because of their considerable potential to me-

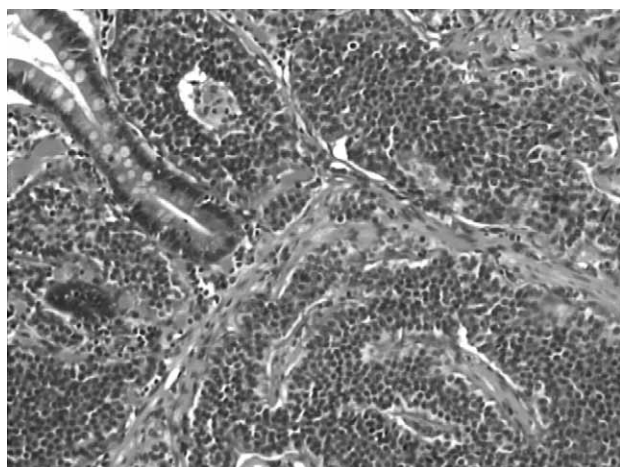


Fig. 1. Histologically, tumour consisting of small cells organised in the alveolar maner under mucosa.

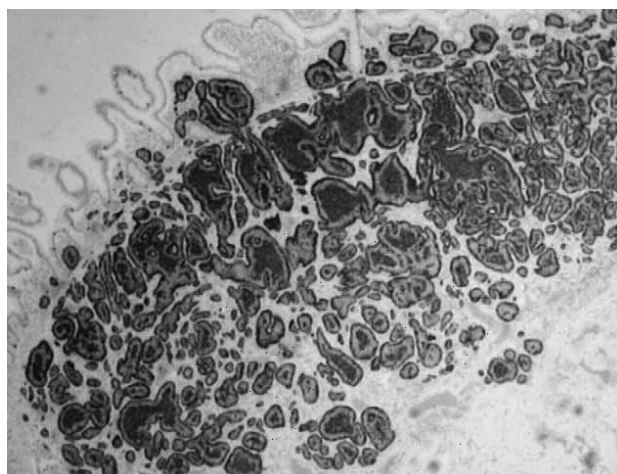


Fig. 2. Immunohistochemistry confirmed chromogranin positive staining.

tastasis. The average age of the patients is 56.6 years and corresponds to the age of patients with ileal carcinoids. Carcinoids in Meckel's diverticula also resemble ileal carcinoids in their biological behaviour more than they do appendiceal carcinoids. Tumours larger than 5 mm have a marked risk to metastasise. More than 70 percent of carcinoids in Meckel's diverticula are found at the tips of the diverticula. A carcinoid-syndrome is rarely found. In symptomatic cases intermittent intestinal obstruction with vomiting, cramps, abdominal pain and weight loss usually occurs.

Only 9% of tumours are found incidentally<sup>7</sup>. We found only one similar case of Leinati A. et al. in the literature showing young patient with appendicitis and accidental finding of carcinoid tumour in Meckel's diverticulum<sup>6</sup>.

According to different authors 70 % to 90% of all carcinoids are localized in the gastrointestinal tract and the most common sites in order of frequency are the appendix, terminal ileum, rectum, and the remainder of the colon. Carcinoids of the upper, middle and lower intestines have to be distinguished ontogenetically. Carcinoids have been included in the APUD system and usually present endocrine activity. The Capella classification takes into account the size of the tumour (2cm), the grade of invasion of surrounding structures, the grade of angi-invasion, the grade of differentiation, the biologic behaviour and the hormonal activity of the tumour<sup>8</sup>. In cases of ungllected or underestimated symptoms by patient it self tumoral endocrine activity can sometimes have devastating consequences<sup>9</sup>.

Carcinoids of the small intestine occur multiple in 30–50%. The therapy of carcinoids depends on the size of the tumour and consecutively on the risk of metastasis. A local excision or non-oncologic radical operative procedure is justified in carcinoids smaller than 1 cm. In tumours 1–2 cm in size an individual decision has to be made. Larger tumours should be operated according to oncology standards. Published series have described significant prognostic features of carcinoid tumours and

they include site of origin, stage at diagnosis, presence of high hormone levels, age, sex and increased T stage. Stage at the time of diagnosis and T stage are the most often found as independent predictors of survival in multivariate analyses.

Because of all aforementioned we find affirmative the opinion that when appendectomy is performed and Meckel's diverticulum detected during exploration it should be removed and pathohistologically examined.

## REFERENCES

1. CARPENTER SS, GRILLIS ME, *Curr Surg*, 60 (2003) 301. DOI: 10.1016/S0149-7944(02)00745-6. — 2. SUTTER PM, CANEPA MG, KUHRMEIER F, MARX A, MARTINOLI S, *Schweiz Med Wochenschr Suppl*, 89 (1997) 20. — 3. NIES C, ZIELKE A, HASSE C, RÜSCHOFF J, ROTHMUND M, *Dis Colon Rectum*, 35 (1992) 589. — 4. PAYNE-JAMES JJ, LAW NW, WATKINS RM, *Postgrad Med J*, 61 (1985) 1009. DOI: 10.1136/pgmj.61.721.1009. — 5. LEINATI A, IACOVONI P, CAVALLERO G, DEALESSI M, PERRONE F, ZANARDI F, ANSELMO E, *Minerva Chir*, 50 (1995) 501. — 6. DI CATALDO A, GRECO S, CALDARELLA P, LANTERI R, LI DESTRI G, LICATA A, *Chir Ital*, 53 (2001) 879. — 7. MACHADO N, GRANT CS, *JR Coll Surg Edinb*, 46 (2001) 180. — 8. ŠTIFTER S, ČINĐRIĆ-STANČIN M, ZAMOLO G, ČOKLO M, PETKOVIĆ M, JONJIĆ N. *Comp Clin Pathol*, 13 (2004) 29. DOI: 10.1007/s00580-004-0506-6. — 9. ANDERSON DJ, *JAOA* 100 (2000) 432. — 10. JAYMI DUMPER, MACKENZIE SHAWN, MITCHELL PHILIP, FRANCIS SUTHERLAND, LYNNQUAN, MEW DAPHNE, *Can J Surg*, 49 (2006) 353.

*J. Fudurić*

*Karlovac General Hospital, Department of Surgery, Dr. Andrije Štampara 3, 47000 Karlovac, Croatia  
e-mail: juricafuduric@yahoo.com*

## KARCINOIDNI TUMOR U MECKELOVU DIVERTIKULU: KAKO LIJEČITI MLADE ODRASLE LJUDE S AKUTNOM UPALOM CRVULJKA – PRIKAZ SLUČAJA

### SAŽETAK

Ovaj slučaj prikazuje neočekivani popratni nalaz karcinoidnog tumora unutar Meckelovog divertikula koji se prikazao pod kliničkom slikom akutnog abdominalnog zbivanja zbog gangrenozne upale crvuljka u mlade odrasle muške osobe. Oba, Meckel divertikul i karcinoidni tumor su rijetki klinički entiteti, a karcinoidni tumor unutar Meckelovog divertikula još je veća rijetkost. Početna klinička prezentacija karcinoidnog tumora u Meckelovom divertikulu obično je slična onoj karcinoida crvuljka. Karcinoidni tumori najčešći su primarni tumori tankog crijeva. Oni nalikuju karcinoidu crvuljka, obično su mali, jedne lokalizacije i asimptomatski. Kirurško liječenje Meckelova divertikula se preporučuje kao postupak. Predstavljajući ovaj slučaj željeli smo naglasiti vrijednost sustavne identifikacije i uklanjanja divertikula tijekom laparotomije i naglasiti važnost istraživanja Meckelova divertikula osobito u slučaju mladih odraslih osoba.