

GIANT MIXED-TYPE LIPOSARCOMA OF THE MESENTERY: CASE REPORT

Zoran Jukić¹, Iva Brčić², Mario Zovak³, Majda Vučić⁴, August Mijić³ and Božo Krušlin^{4,5}

¹Department of Surgery, Nova Gradiška General Hospital, Nova Gradiška; ²University Department of Pathology and Cytology, Zagreb University Hospital Center; ³University Department of Surgery, ⁴Ljudevit Jurak University Department of Pathology, Sestre milosrdnice University Hospital Center; ⁵School of Medicine, University of Zagreb, Zagreb, Croatia

SUMMARY – Primary mesenteric liposarcomas are very rare, especially when they are of mixed histologic pattern. Patient prognosis is based upon the most aggressive histologic type of liposarcoma. A case is reported of a 77-year-old man with a history of slowly increasing abdominal volume over 3 years. The diagnosis of giant intra-abdominal mass suspect of liposarcoma was confirmed by computed tomography and ultrasound scans. The patient underwent resection of 24 tumor masses weighing together 23.5 kg. The microscopic diagnosis was mixed-type liposarcoma of the mesentery. Although this type of tumor is rare, tumor tissue should be thoroughly collected and analyzed on histologic examination to reach definitive diagnosis. Recognition of the underappreciated subtype of liposarcoma is important for proper prognosis and treatment of the patient. According to our knowledge, this is the largest size of mixed-type mesenteric liposarcoma described in the English literature.

Key words: *Mixed-type liposarcoma; Mesentery; Intra-abdominal mass; Giant liposarcoma*

Introduction

Liposarcomas are the most common sarcomas in adults¹. They can be morphologically divided into three major forms: well-differentiated/dedifferentiated, myxoid/round cell, and pleomorphic liposarcoma (PLS)^{1,2}. Occasionally, some or all of these components combine and they are then called mixed-type liposarcoma². Well-differentiated liposarcoma (WDL) is a low-grade malignancy with good prognosis. PLS is the rarest and most aggressive subtype of liposarcoma. It arises most frequently in the extremities of adults, although it can occur at other sites³⁻⁸. It is a high-grade sarcoma defined histologically by the presence of pleomorphic, multivacuolated lipoblasts.

It often metastasizes to the lungs and the prognosis is poor^{1,2}. We report a case of a giant abdominal mixed-type liposarcoma originating from mesentery, followed by review of the literature.

Case Report

In October 2007, an otherwise healthy 74-year-old male presented with a history of 5-kg weight loss despite his increasing abdominal girth. Ultrasound examination showed a large, hypoechogenic abdominal mass that compressed surrounding organs. Another smaller hypoechogenic, solid lesion measuring 12.9 cm in largest diameter was found in the small pelvis. The lesion compressed urinary bladder and spread to the inguinal region. Computed tomography (CT) scan confirmed these findings. The patient declined the proposed surgical removal of the mass suspect of sarcoma. In the next 2 years, his abdomen gradually increased but he still refused surgery. At that time,

Correspondence to: *Iva Brčić, MD, PhD*, University Department of Pathology and Cytology, Zagreb University Hospital Center, Kišpatičeva 12, HR-10000 Zagreb, Croatia
E-mail: ibrccic@kbc-zagreb.hr

Received July 27, 2011, accepted April 24, 2012

additional ultrasound and CT confirmed intra-abdominal mass that increased in size. After 3 years, then 77-year-old patient presented with edema (leg swelling) and shortness of breath. On physical examination, the abdomen was markedly distended, but soft and painless.

On chest x-ray, no lesions suspect of metastasis were found. Ultrasound examination detected a large, solid abdominal mass that almost entirely occupied the abdominal cavity. CT scan showed the presence of a hiatal hernia and a giant heterogeneous, expansively growing mass in the abdominal cavity and retroperitoneum, which compressed small bowel completely to the right side. Compared to the initial CT, the mass was poorly-defined from the surrounding tissue, was more solid and attached to the underlying structures. The mass in the small pelvis was also enlarged, solid and lobulated, measuring 13.8 cm in greatest diameter. On laparotomy, many tumor masses measuring from 5 to 35 cm in largest diameter were found, filling the entire abdominal cavity. The tumors originated from the small bowel mesentery. Some of the tumors infiltrated the wall of the small pelvis and some were effacing portions of the small bowel, so that the small intestine had to be resected at two sites.

Macroscopic examination of 24 surgical specimens revealed firm, nodular tumor masses measuring from 5 to 35 cm in greatest diameter, which altogether weighed 23.5 kg (Fig. 1A, B). The largest of these masses was 35x15x15 cm in size. The cut surface

was soft, white to yellow, and partially necrotic. Microscopically, sections of the tumors were composed of multiple distinct parts. Some parts consisted of various-sized adipocytes with atypical hyperchromatic nuclei and multivacuolated lipoblasts (Fig. 2A). Other parts had many variably sized lipoblasts surrounded by fibromyxoid stroma containing spindle cells with large, hyperchromatic nuclei (Fig. 2B). Other parts consisted predominantly of highly cellular and pleomorphic spindle-shaped tumor cells with enlarged round to bizarre nuclei with variable number of pleomorphic lipoblasts (Fig. 2C, D). Mitotic count was 15/10 high-power fields (HPFs) and necrotic foci were found. Immunohistochemically, tumor cells showed positive reaction to S-100 (DAKO, Copenhagen, Denmark). Definitive diagnosis was mixed-type liposarcoma comprised of well-differentiated, dedifferentiated and pleomorphic areas.

The patient was admitted to intensive care unit and was doing well. Suddenly, eight days after the surgery, the patient's condition deteriorated and he died. Autopsy was not performed.

Discussion

In adults, the most commonly diagnosed histologic types of liposarcoma are WDL and myxoid type. WDL is a locally aggressive mesenchymal neoplasm that can be divided into three subtypes: lipoma-like, sclerosing, and inflammatory. In contrast to WDL,

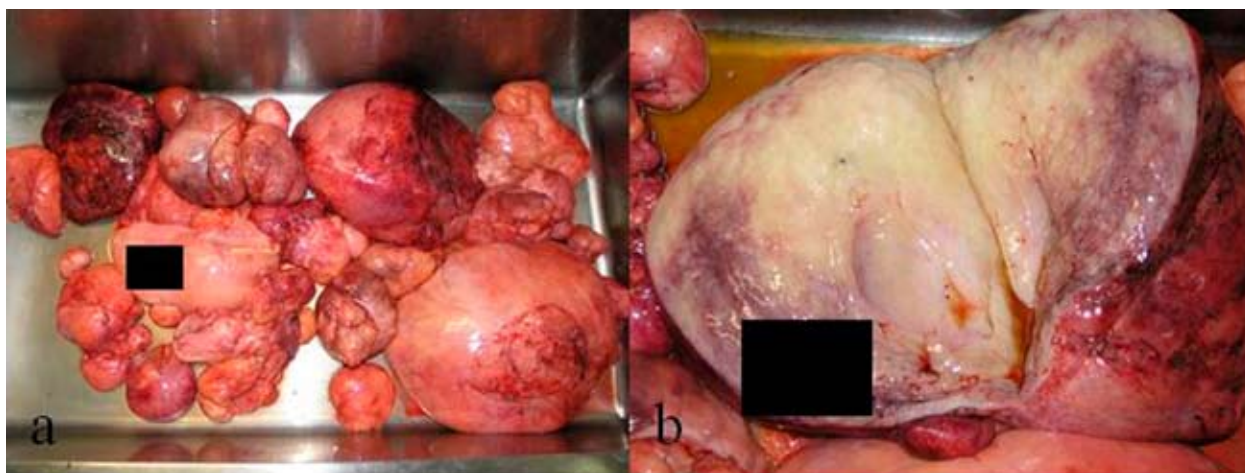


Fig. 1. Macroscopic findings: (A) all 24 tumor masses found during laparotomy; (B) cut surface was soft, white to yellow and partially necrotic.

PLS is a clinically and morphologically distinct type of liposarcoma and it is the most uncommon one. It occurs most often in the deep soft tissues of the extremities^{1,2}. Furthermore, some liposarcomas are composed of two or more histologic types and are then classified as mixed-type liposarcoma. They usually occur in retroperitoneum^{1,2}.

Different tumor sites and sizes have been reported for all types of liposarcoma³⁻⁸. Primary mesenteric liposarcomas are rarely described³. In the literature, we found reports of large liposarcomas of the abdominal cavity, but they were morphologically recognized as well-differentiated/dedifferentiated or myxoid liposarcomas. Ciraldo *et al.* describe a patient with a primary mesenteric liposarcoma with mixed histologic pattern. They isolated three tumor masses that weighed

8.54 kg and the largest one measured 30x20x15 cm. Histopathologic examination revealed predominantly myxoid liposarcoma with areas of pleomorphic, inflammatory and lipoma-like liposarcoma³. Our patient refused surgical treatment for three years, so that the tumor had time to enlarge. Finally, upon the surgery, 24 tumor masses were resected, together weighing 23.5 kg and the largest one was 30x15x15 cm in size. According to our knowledge, this is the largest mixed-type liposarcoma of the mesentery reported in the English literature. Microscopically, the tumor consisted of lipoma-like and sclerosing subtypes of WDL and PLS.

Prognosis of patients with mixed-type liposarcoma is based on the most aggressive type found in the tumor, which, in our case, was PLS. Because it is so

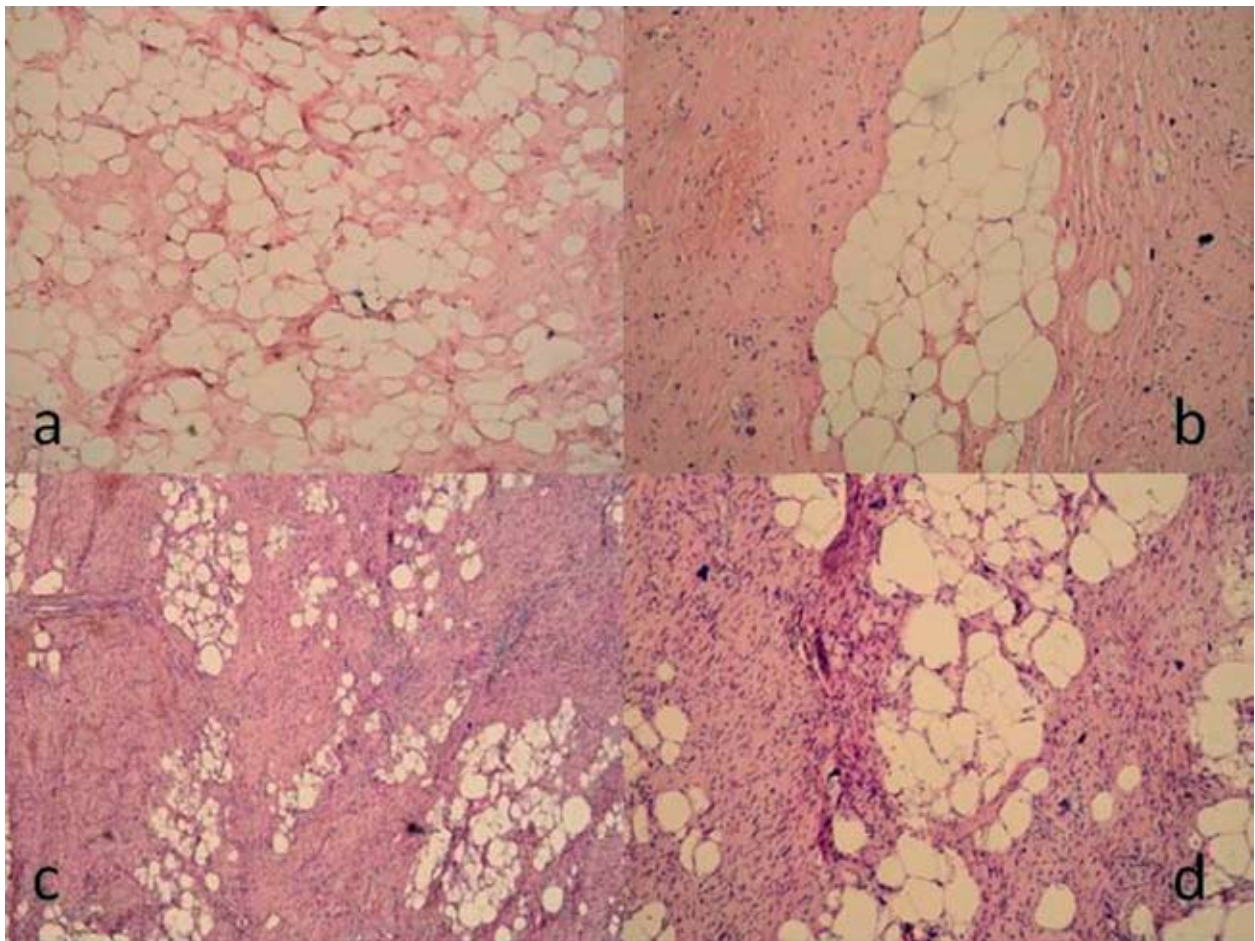


Fig. 2. Histopathologic findings (H&E sections): (A) lipoma-like well-differentiated liposarcoma (X40); (B) sclerosing subtype of well-differentiated liposarcoma with fibrous bands containing atypical cells (X40); (C) and (D) areas of pleomorphic liposarcoma (X40 and X100).

rare, there are only limited data on the PLS clinical and histopathologic spectrum. First of all, it should be differentiated from other types of high-grade sarcomas. This asks for careful inspection of the surgical specimen, adequate sampling, and afterwards an extensive search for pleomorphic lipoblasts on hematoxylin and eosin slides. The inter-observer variations in the identification of pleomorphic lipoblasts can also influence the final diagnosis and eventually the treatment of the patient. Immunohistochemistry does not play the most important role in the determination of PLS and is therefore of no help in equivocal cases. It is more useful in distinguishing PLS from other high-grade sarcomas.

Histologically, three different patterns of PLS are described. Most of these neoplasms are composed of pleomorphic spindle-shaped tumor cells and fascicles of spindle-shaped and smaller, round cells and multinucleated giant cells resembling malignant fibrous histiocytoma (MFL-like pattern). Some tumor areas in our patient consisted of this pattern. Pleomorphic, multivacuolated lipoblasts, with bizarre and hyperchromatic nuclei scalloped by cytoplasmic vacuoles can vary in number, size and shape. In some cases, sheets of pleomorphic lipoblasts are seen, whereas only scattered pleomorphic lipoblasts are found in others. A number of cases is presented as epithelioid variant of PLS, first described by Miettinen and Enzinger in 1999⁴. It is characterized by sheets and clusters of atypical epithelioid tumor cells with round nuclei, variably prominent nucleoli and eosinophilic to vacuolated cytoplasm admixed with pleomorphic lipoblasts, separated by narrow fibrous septa with capillaries. In the third variant, foci with morphological features of PLS resembling intermediate to high grade myxofibrosarcoma associated with pleomorphic lipoblasts are found.

Some studies tried to reveal clinical or histologic features of PLS that are predictive of clinical outcome. In the study by Downes *et al.*, 7 of 19 PLS cases were of epithelioid type, whereas others presented with the most common histologic picture⁶. They also concluded that no clinical or histologic feature appeared to be predictive of clinical outcome. The following features were recorded: tumor site, size and depth, predominant histologic pattern, tumor necrosis and mitotic count. In contrast, Hornic *et al.* report 57 cases of PLS, dividing them into the three previously men-

tioned patterns: 60%, 28% and 12% of cases, respectively⁷. They found that tumor depth, central location (non-extremity) and size > or =10 cm, 10 mitoses or more in 10 HPFs, areas of tumor necrosis and epithelioid morphology were associated with worse clinical prognosis. Gebhard *et al.* showed similar results⁸. Furthermore, Sato *et al.* also concluded that tumors larger than 20 cm predicted a significantly poorer prognosis⁹. In our patient, the tumor was of mixed histology, with the most 'aggressive' part being PLS with MFL-like morphology, was situated centrally, was much greater than 10 cm in diameter, had up to 15 mitoses *per* 10 HPFs and foci of necrosis. All of these features suggested poor clinical outcome.

Conclusion

Histologic classification of liposarcoma is found to be an important prognostic factor, together with tumor site and size. Therefore, correct clinical assessment, measuring and sampling of the surgical specimen, light-microscopic examination and, at the end, classification of these neoplasms is necessary for appropriate treatment of the patient.

References

1. FLETCHER CDM. Soft tissue tumors. In: FLETCHER CDM, editor. Diagnostic histopathology of tumors. London: Churchill Livingstone, 2000;1473-540.
2. WEISS SW, GOLDBLUM JR. Liposarcoma. In: WEISS SW, GOLDBLUM JR, editors. Enzinger and Weiss's Soft tissue tumors. St Louis, MO: Mosby, 2001;641-93.
3. CIRALDO A, THOMAS D, SCHMIDT S. Giant abdominal liposarcoma: a case report. The internet journal of pathology 2000. Available from URL: <http://www.ispub.com/ostia/index.php?xmlFilePath=journals/ijpa/vol1n1/lipo.xml>.
4. MIETTINEN M, ENZINGER FM. Epithelioid variant of pleomorphic liposarcoma: a study of 12 cases of a distinctive variant of high-grade liposarcoma. Mod Pathol 1999;12:722-8.
5. BRCIC L, JAKOVCEVIC A, BATELJA VULETIC L, ORLIC D, SEIWERTH S. Pleomorphic liposarcoma of the foot: a case report. Diagn Pathol 2008;3:15.
6. DOWNES KA, GOLDBLUM JR, MONTGOMERY EA, FISHER C. Pleomorphic liposarcoma: a clinicopathologic analysis of 19 cases. Mod Pathol 2001;14:179-84.
7. HORNICK JL, BOSENBERG MW, MENTZEL T, McMENAMIN ME, OLIVEIRA AM, FLETCHER CD. Pleomorphic liposarcoma: clinicopathologic analysis of 57 cases. Am J Surg Pathol 2004;28:1257-67.

8. GEBHARD S, COINDRE JM, MICHELS JJ, TERRIER P, BERTRAND G, TRASSARD M, TAYLOR S, CHATEAU MC, MARQUES B, PICOT V, GUILLOU L. Pleomorphic liposarcoma: clinicopathologic, immunohistochemical, and follow-up analysis of 63 cases: a study from the French Federation of Cancer Centers Sarcoma Group. *Am J Surg Pathol* 2002;26:601-6.
9. SATO T, NISHIMURA G, NONOMURA A, MIWA K. Intraabdominal and retroperitoneal liposarcomas. *Int Surg* 1999;84:163-7.

Sažetak

GIGANTSKI LIPOSARKOM MEZENTERIJA MIJEŠANOG TIPA

Z. Jukić, I. Brčić, M. Zovak, M. Vučić, A. Mijičić B. Krušlin

Primarni liposarkomi mezenterija su rijetki, osobito ako su miješanog histološkog izgleda. Prognoza pacijenta ovisi o najagresivnijem histološkom tipu liposarkoma. Prikazujemo slučaj 77. godišnjeg muškarca s anamnezom spororastućeg volumena abdomena tijekom 3 godine. Dijagnoza ogromne intra-abdominalne mase suspektne na liposarkom potvrđena je CT-om i ultrazvukom. Pacijentu su resecirane 24 tumorske mase koje su zajedno težile 23.5 kg. Histološka dijagnoza je bila miješani tip liposarkoma mezenterija. Iako je ovaj tip tumora rijedak, tumorsko tkivo treba pomno preuzeti i pregledati histološki kako bi se postavila ispravna zaključna dijagnoza. Pronalazak nepovoljnog tipa liposarkoma je važan zbog točne prognoze i daljnjeg liječenja pacijenta. Prema našim saznanjima, ovo je najveći opisani liposarkom mezenterija miješanog tipa u engleskoj literaturi.

Ključne riječi: *Liposarkom miješanog tipa; Mezenterij; Intra-abdominalna masa; Gigantski liposarkom*

