

Zoon Plasma Cell Balanitis: An Overview and Role of Histopathology

Zrinjka Paštar¹, Jaka Radoš², Mihael Skerlev², Jasna Lipozenčić², Davorin Lončarić²

¹Ministry of Defense, Republic of Croatia; ²Department of Dermatology and Venerology, Zagreb University Hospital Center, Zagreb, Croatia

Corresponding author:

Prof. Jasna Lipozenčić, MD, PhD

Department of Dermatology and Venerology

Zagreb University Hospital Center

Šalata 4

10000 Zagreb, Croatia

jasna.lipozenic@zg.htnet.hr

Received: 24.05.2004.

Accepted: 27.09.2004.

SUMMARY Balanitis circumspecta plasmacellularis or Zoon's balanitis is an idiopathic, benign condition of the genitalia that mostly presents as a solitary, persistent plaque on the glans of primarily uncircumcised, middle-aged to older men. Its etiology and pathogenesis remains speculative. This article provides an overview of the clinical morphology, microscopic features, differential diagnosis and therapy. Particular attention is paid to histopathologic features. Besides, a case is presented of an uncircumcised man with clinical and histologic features of balanitis circumspecta plasmacellularis who was successfully cured by circumcision. The distinction of this lesion from similar lesions is rather important, and a large group of disorders such as premalignant, infective and other inflammatory penile diseases should be definitely taken into consideration on the differential diagnosis. It seems that circumcision might be the current 'gold standard' for treatment of this disorder.

KEY WORDS balanitis plasmacellularis; Zoon; circumcision

INTRODUCTION

Plasma cell balanitis represents an entity first described in 1952 by Zoon in eight men with chronic balanitis whose condition had been previously diagnosed as premalignant erythroplasia of Queyrat (1-4). Histopathologically, Zoon noted atrophy of the epidermis and a massive band-like infiltrate of inflammatory cells in the upper dermis that was composed mostly of plasma cells. Cytologic atypia and characteristic signs of erythroplasia were absent, and the 'behavior' of the lesions was benign (1,5). As the histopathologic findings were repeatable, Zoon considered "*balanoposthite chronique circonscrite bénigne à plasmocytes*" to be a distinct entity (2,5). Subsequently it has been referred to as plasma cell balanitis of Zoon and balanitis circums-

cripta plasmacellularis. It presents as a solitary, persistent plaque on the glans of uncircumcised, middle-aged to older men (6). Its etiology and pathogenesis remain speculative (4,6).

We present a case of an uncircumcised man with clinical and histologic features of balanitis circumspecta plasmacellularis.

CASE REPORT

A 54-year-old white man presented with a history of angina pectoris, arterial hypertension, atherosclerotic occlusion in proximal segment of the right coronary artery, hyperlipidemia, hyperuricemia, stroke, and right hemiparesis. The patient had

been treated for over a year and a half by his urologist because of erectile dysfunction and chronic recurrent prostatitis. The lesion on the penis persisted for over a year as well, and was understood as acute balanitis. The penile lesion was unresponsive to several topical corticosteroid and neutral medications.

Clinical presentation seen in dermatologist office included an asymptomatic erythematous, shiny, moist, glistening and purely infiltrated plaque on the 2/3 of circumflexion of the glans penis, near coronal sulcus, 2 cm in diameter (Figs. 1 and 2), and inner surface of the prepuce. The skin, palms, soles, oral and perianal mucosa were normal. Inguinal lymphadenopathy was not present.

The patient was sexually active and presented with his sexual problems. General systemic physical examination was, despite the history, unremark-

able. Routine blood analysis and urinalysis were within the normal limits. Potassium hydroxide preparation of the lesion was negative for fungal elements. Gram's, Giemsa and silver stains of a lesional smear preparation were negative for bacteria. Cultures from the lesion were negative for bacteria, fungi and herpes simplex virus.

Biopsy was done by an urologist under topical anesthesia with lignocaine 2.5%, prilocaine 2.5% cream (EMLA®). Histopathologic examination of lesional biopsy showed atrophy of epidermis, flattening of rete ridges, moderate spongiosis, scant lymphocytes and inflammatory cells in the lower part of the epidermis (Fig. 3). Superficial erosions were noted in some parts while in one part there was loss of entire epidermis (ulceration). Zones with subepidermal clefts (separation) were also found (Fig. 4). In superficial dermis, a band-like infil-

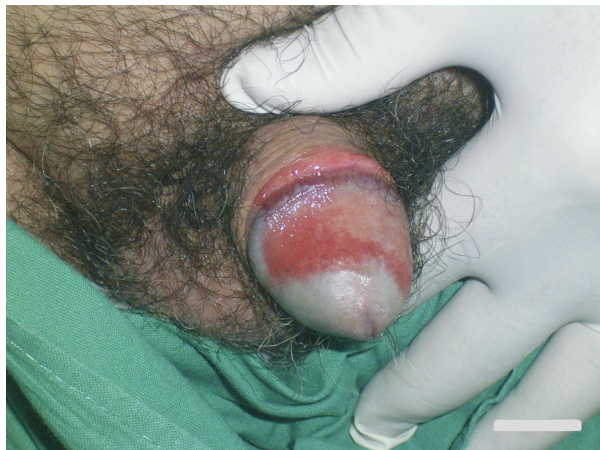

Figure 1. Erythematous, shiny plaque on the glans and prepuce.

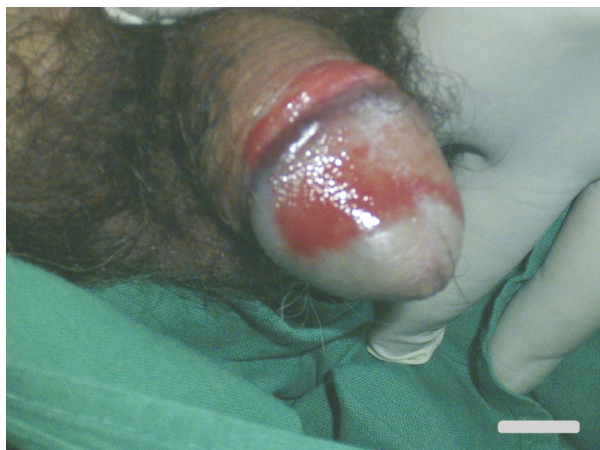

Figure 2. Glistening plaque on the glans with 'Cayenne pepper spots'.

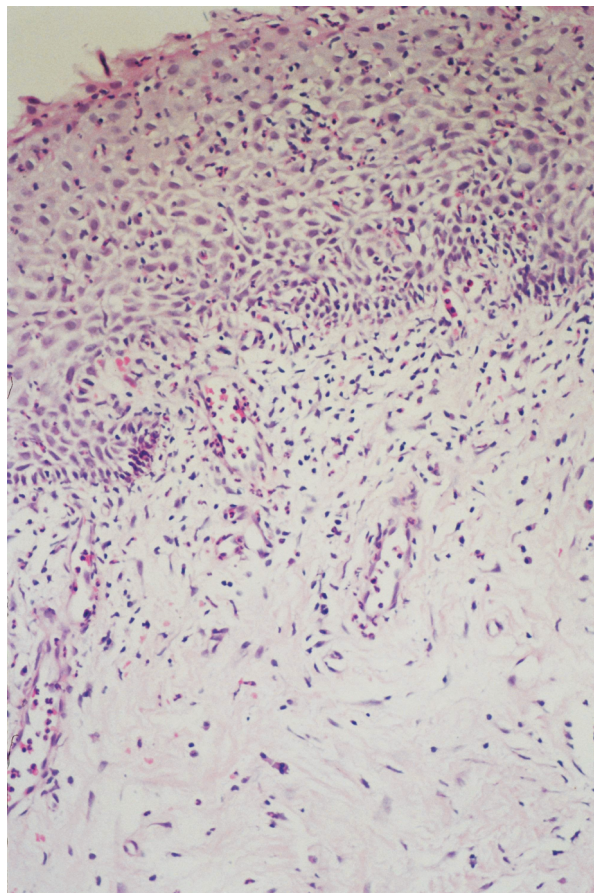


Figure 3. Moderate acanthosis, spongiosis, lymphocytes and neutrophils throughout the epidermis; edema, dilated vessels, free extravasated erythrocytes, mixed infiltrate of lymphocytes, histiocytes, plasma cells, some neutrophils and rare eosinophils in the dermis (hematoxylin-eosin stain; original magnification $\times 50$).

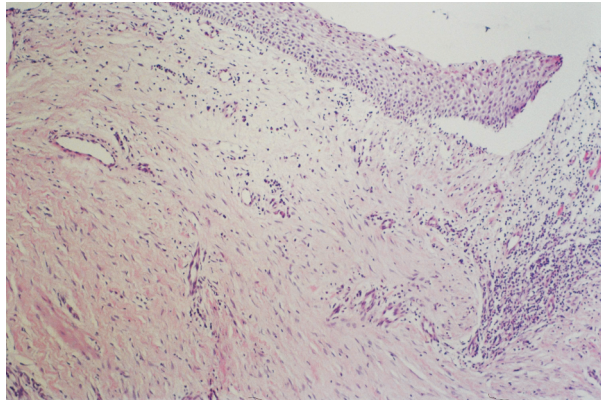


Figure 4. Atrophy of epidermis, flattening of rete ridges, subepidermal cleft at the rim, scattered lymphocytes and plasma cells, dense, band-like infiltrate of lymphocytes and plasma cells at the margin (hematoxylin-eosin stain, original magnification $\times 25$).

trate with predominance of plasma cells and some lymphocytes, neutrophils, eosinophils and edema were readily visible (Fig. 5). Dilated vessels were also present with free extravasated erythrocytes (Figs. 3-5).

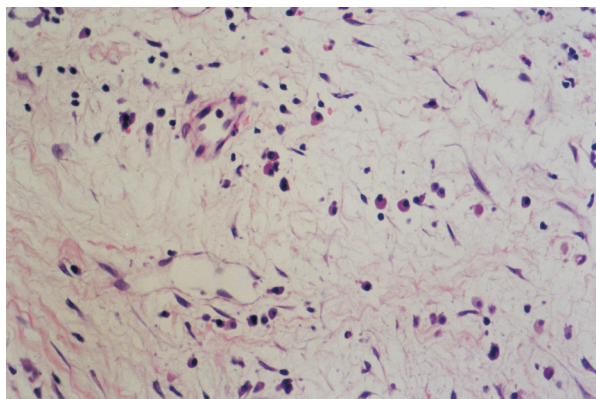


Figure 5. Detail from Figure 4. Predominant plasma cells with sparse lymphocytes and extravasated erythrocytes in edematous dermis (hematoxylin-eosin stain, original magnification $\times 100$).

The diagnosis of Zoon's balanitis was based on the clinicopathologic correlation of the morphologic features and histologic changes of the lesion. The lesion was unresponsive to topical medications, including betamethasone dipropionate and gentamicin sulfate, antiseptics and avoidance of trauma.

As for further treatment options, circumcision in local anesthesia was performed by urologist. Topical indifferent therapy was then recommended. Complete clinical resolution on glans penis was

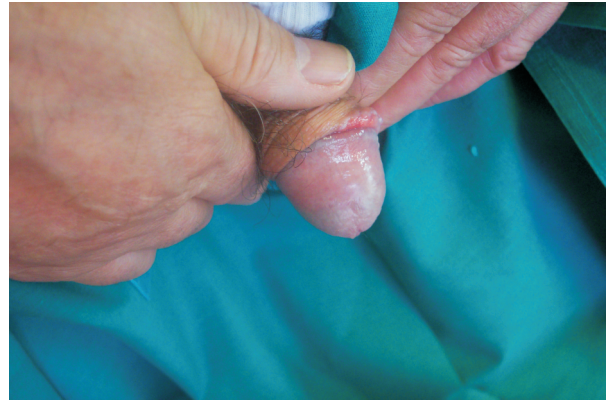

Figure 6. Complete resolution of the lesion on the glans with erythema in coronal sulcus.

seen on clinical checkup seven weeks following circumcision, whereas in coronal sulcus (Fig. 6) 'discrete' erythema could still be observed, with some synechiae following circumcision. Fourteen weeks following circumcision, complete clinical resolution was observed in coronal sulcus.

DISCUSSION

Balanitis circumscripta plasmacellularis or Zoon's balanitis is an idiopathic, benign condition of the genitalia that presents as a solitary, persistent plaque on the glans of primarily uncircumcised, middle-aged to older men (1,3,5-7). The etiology of the condition is not clearly established. It has been mostly found in uncircumcised men; besides heat, friction, hypospadias, and lack of genital hygiene are believed to be predisposing factors (1,8). Trauma may be a contributory cause, as localization of the lesions is mostly on the dorsal site of the glans and prepuce (1), which is more commonly subjected to minor trauma than the ventral site (5). Retention of smegma and formation of 'smegma stones' have been repeatedly described in patients with phimosis in whom retention of urine may lead to constant irritation of the skin (5,9).

Some authors suggest that balanitis represents a nonspecific inflammatory response to an unknown exogenous agent, and therefore is associated with plasma cell infiltration predominated by IgG producing cells, suggesting a nonspecific polyclonal stimulation of B cells, as is common in chronic infections (1,4). Chronic infection by *Mycobacterium smegmatis* (1,3,10) and human papillomaviruses (4) has been postulated, however, no ev-

idence has yet been reported for bacterial infection, and polymerase chain reaction (PCR) analysis failed to detect DNA of human papillomaviruses (4,5). The chronic infection theory is supported by the improvement of lesions after circumcision (4,11). No evidence is given for the hypothesis that Zoon's balanitis may be caused by local disturbance of the circulation, or is related to lichen aureus cause of marked hemorrhage (12), or, as Nishimura *et al.* suggest, to immediate hypersensitivity mediated by IgE class antibodies (13). Furthermore, there is no evidence to support Hyman's and Leider's speculation that 'extramedullary plasmacytic infiltrations that persists are expressions of occult multiple myeloma' (5). Solitary lesions are more common, although multiple lesions may occur in some patients as well (6).

The duration of history prior to presentation ranges from several months to a decade or more (1,3,6). The majority of lesions are located on the glans penis, while the mucosal aspect of the prepuce and coronal sulcus may also be involved (4,6,7). Analogous lesions can be found in women on the labia minora (4,7) and have been reported under a variety of synonyms such as benign plasma cell erythroplasia, Zoon's vulvitis and vulvitis chronica plasmacellularis (4,14,15). Other locations are the mouth (gingiva, hard palate, bucal mucosa) and conjunctiva (7), urethra (5,16), cheeks (5) and epiglottis (17). The clinical presentation is usually an erythematous, shiny, moist, glistening, sharply demarcated macular to slightly raised plaque(s) (1-3,5,6). The color is usually bright red, but it may be with multiple pinpoint brighter red spots, so-called 'Cayenne pepper spots' (3,6) due to microhemorrhage and hemosiderin deposition (6). Clinical variants have been reported including erosive type with bleeding, especially on the inner surface of the prepuce (5), and vegetative type (5,6). Associated symptoms are mild (subpreputial discharge, itching) or nonexistent.

Histopathologic changes affecting epidermis and dermis are distinctive. Pathologic findings of the epidermis may include atrophy (due to reduction in size and number of keratinocytes, and absence of the horny and granular cell layers) (3), acanthosis, parakeratosis, superficial erosions, subepidermal clefts, superficial acantholysis, necrotic keratinocytes, lozenge keratinocytes (individ-

ual epidermal cells in the suprabasal layers have been described as diamond-shaped keratinocytes with their horizontal axis exceeding the vertical (1,3) and therefore elongated and arranged in parallel to the skin surface (5)), spongiosis (regular widening of the intercellular spaces between individual keratinocytes throughout the epidermis, presumably due to edema, may be seen and is termed 'watery spongiosis') (3), vacuolar alteration and neutrophils in upper epidermis (exocytosis of mononuclear cells, erythrocytes, particularly in the basal and suprabasal layers of the epidermis, is occasionally seen (3)). Focal loss of superficial parts of the epidermis can be associated with neutrophils in the upper epidermis (5). Spongiosis tends to be accentuated in the lower half of the spinous zone and has no significant correlation with the presence or absence of neutrophils in the epidermis (5).

Histopathologic findings in the dermis are dense band-like or lichenoid infiltrate of plasma cells, neutrophils, eosinophils, lymphocytes and erythrocytes, prominent blood vessels, siderophages, and fibrosis (5). Plasma cells are predominant in the infiltrate and usually exceed 50% of the cells present, although the plasma cell population can be assessed as low as few plasma cells, moderately dense to dense infiltrate of plasma cells (2,3,5-7) but always detectable (5). An appreciable number of lymphocytes is constantly present. Polymorphonuclear leukocytes can be spotted in the dermis in most cases, but they are never predominant (3,5). Eosinophils are only rarely seen and are mostly sparse (3,5). Changes in the dermal vasculature can be prominent and characteristic, with vascular proliferation with singular vertical or oblique orientation of dilated individual vessels (3,5-7), and are more common in cases with a dense infiltrate (5), although this correlation did not reach statistical significance according to Weyers *et al.* (5). Hemosiderin deposits are a frequent mark but free extravasated erythrocytes are more often found in abundance in the dermal infiltrate (1-3,5,7). Fibrosis can be seen in the upper dermis and correlates with subepidermal clefts, atrophy of epidermis, hemorrhage in the superficial dermis, and predominance of plasma cell infiltrate (3,5).

The earliest histopathologic changes are thickening of the epidermis, parakeratosis and a patchy lichenoid infiltrate of lymphocytes and some plasma

cells (5). More advanced cases show atrophy of the epidermis, superficial erosions, scattered neutrophils in the upper reaches of the epidermis, scant spongiosis, extravasation of erythrocytes, and a much denser infiltrate with many plasma cells (5).

At even later stages additional findings may be subepidermal clefts, sometimes with loss of the entire epidermis, marked fibrosis of the superficial dermis, and many siderophages (5). Keratinocyte dysplasia and frank vesiculation are absent (1,3).

Disorders that clinically mimic balanitis circumscripta plasmacellularis include candidiasis, lichen planus, secondary syphilis, erythroplasia of Queyrat (squamous cell carcinoma *in situ* or Bowen's disease of the glans penis), in which it is relatively simple to histologically note dysplastic epithelium, fixed drug eruption, allergic contact dermatitis, herpes simplex virus, pemphigus vulgaris, psoriasis vulgaris and Reiter's disease. These entities may histologically show features in common with Zoon's balanitis but lack typical changes in the epidermis and dermal vessels. Balanitis of Zoon may be seen either as an isolated finding or being superimposed on the lesions of a variety of inflammatory and neoplastic skin diseases (5). Features not usually encountered in balanitis of Zoon, including eosinophilia, vacuolar alteration at the dermoepidermal junction, necrotic keratinocytes, psoriasiform hyperplasia, slight atypia, and crowding of keratinocytes, should always indicate the possibility of an unrelated underlying pathologic process (5,18,19).

Patients may require biopsy evaluation and treatment for anxiety, cosmetic disfigurement, discomfort and irritation. Treatment most often includes circumcision and nonsurgical management that consists of topical (20) and intralesional corticosteroid medications, fucidic acid cream (21) and carbon dioxide laser (22,23). Circumcision using local or general anesthesia seems to be the treatment of choice (1,2,9,11,24,25). The semi-mucosal character of the squamous epithelium that covers the inner preputial surface and the glans disappears after circumcision (1,26). Removal of this mucosal quality appears to inhibit the undetermined etiologic agent(s) (1), however, the aseptic technique applied during circumcision followed by regular cleaning during healing may also alleviate the condition (2).

Topical steroid preparations have been recommended in the UK National Guidelines on Sexually Transmitted Infections and Closely Related Conditions (27) on a par with circumcision. Topical corticosteroid creams and ointments may produce symptomatic relief in some cases (1). Topical antibiotics and antifungal therapies are almost universally without benefit (1), although the study by Tang *et al.* strengthens the evidence by presenting longterm efficacy data for Trimovate® (combined topical preparation consisting of clobetasone butyrate 0.05%, oxytetracycline 3% and nystatin 100,000 units/g) but does not raise the level of evidence or grade of recommendation (2).

CONCLUSION

Plasma cell balanitis occurs commonly in elderly uncircumcised men and is clinically presented as sharply demarcated bright red glistening patch(es) on the glans penis and prepuce. Focal erosions can be seen if the lesion is long-standing. Analogous lesions of the female genitalia under the name of vulvitis plasmocellularis share the clinical and pathologic features of balanitis circumscripta plasmacellularis (3,28). Zoon's balanitis seems to be a nonspecific response to irritant and mechanical forces acting on barely keratinized skin in a moist environment. The sequence of histopathologic changes is compatible with a thesis that balanitis of Zoon results from irritation or mild trauma affecting barely keratinized skin in a moist environment. Its morphologic features are superficial erosions, scattered neutrophils in the upper reaches of the spinous zone, slight spongiosis, and a band-like infiltrate of lymphocytes and plasma cells in superficial dermis, whereas advanced lesions show atrophy or complete loss of the epidermis, and fibrosis and deposition of hemosiderin in the upper dermis. Recognition of histopathologic features should allow for simple differentiation from premalignant (29), infective and other inflammatory penile lesions which may be more responsive to treatment. Circumcision appears to be the current 'gold standard' for treatment. Thus, careful clinical and sometimes pathohistologic monitoring is definitely required in the complex and demanding management of male external genitalia disorders.

References

- 1 Davis DA, Cohen PR. Balanitis circumscripta plasmacellularis. *J Urol* 1995;153:424-6.
- 2 Tang A, David N, Horton LWL. Plasma cell balanitis of Zoon: response to Trimovate cream. *Int J STD AIDS* 2001;12:75-8.
- 3 Souteyrand P, Wong E, MacDonald DM. Zoon's balanitis (balanitis circumscripta plasmacellularis). *Br J Dermatol* 1981;105:195-9.
- 4 Kiene P, Folster-Holst R. No evidence of human papillomavirus infection in balanitis circumscripta plasmacellularis Zoon. *Acta Derm Venereol* 1995;75:496-7.
- 5 Weyers W, Ende Y, Schalla W, Diaz-Cascajo C. Balanitis of Zoon: a clinicopathologic study of 45 cases. *Am J Dermatopathol* 2002;24:459-67.
- 6 Johnson RA. Diseases and disorders of the male genitalia. In: Freedberg IM, Eisen AZ, Wolff K, Austen KF, Goldsmith LA, Katz SI, editors. *Fitzpatrick's Dermatology in general medicine*, 6th ed. New York, NY: McGraw Hill, 2003:1091-107.
- 7 Braun-Falco O, Plewig G, Wolff HH, Burgdorf WHC. Diseases of the male genitalia. In: Braun-Falco O, Plewig G, Wolff HH, Burgdorf WHC, editors. *Dermatology*, 2nd completely revised edition. Berlin: Springer, 2000:1195-211.
- 8 Jolly BB, Krishnamurty G, Vaidyanathan S. Zoon's balanitis. *Urol Int* 1993;50:182.
- 9 Kumar B, Sharma R, Rajagopalan M, Radotra BD. Plasma cell balanitis: clinical and histopathologic features – response to circumcision. *Genitourin Med* 1995;71:32-4.
- 10 Montgomery JC. *Dermatopathology*, 1st ed., Vol. 2. London: Harper and Row, 1967:98.
- 11 Murray WJG, Fletcher MS, Yates-Bell AJ, Pryor JP, Darby AJ, Packham DA. Plasma cell balanitis of Zoon. *Br J Urol* 1986;58:689-91.
- 12 Kossard S, Shumack S. Lichen aureus of the glans penis as an expression of Zoon's balanitis. *J Am Acad Dermatol* 1989;21:804-6.
- 13 Nishimura M, Matsuda T, Muto M, Hori Y. Balanitis of Zoon. *Int J Dermatol* 1990;29:421-3.
- 14 Garnier G. Benign plasma cell erythroplasia. *Br J Dermatol* 1982;106:585-8.
- 15 Davis J, Sharpiro L, Baral J. Vulvitis circumscripta plasmacellularis. *J Am Acad Dermatol* 1983;8:413-6.
- 16 Merot Y, Harms M. Umschriebene Urethritis plasmacellularis (Zoon) der Fossa navicularis. *Hautarzt* 1983;34:18-9.
- 17 White JW, Olsen KD, Banks PM. Plasma cell orificial mucositis. *Arch Dermatol* 1986;122:1321-4.
- 18 Davis-Daneshfar A, Trueb RM. Bowen's disease of the glans penis (erythroplasia of Queyrat) in plasma cell balanitis. *Cutis* 2000;65:395-8.
- 19 Joshi UY. Carcinoma of the penis preceded by Zoon's balanitis. *Int J STD AIDS* 1999;10:823-5.
- 20 Yoganathan S, Bohl TG, Mason G. Plasma cell balanitis and vulvitis (of Zoon). A study of 10 cases. *J Reprod Med* 1994;39:939-44.
- 21 Petersen CS, Thomsen K. Fusidic acid cream in the treatment of plasma cell balanitis. *J Am Acad Dermatol* 1992;27:633-4.
- 22 Baldwin HE, Geronemus RG. The treatment of Zoon's balanitis with the carbon dioxide laser. *J Dermatol Surg Oncol* 1989;15:491-4.
- 23 Retamar RA, Kien MC, Chouela EN. Zoon's balanitis: presentation of 15 patients, five treated with a carbon dioxide laser. *Int J Dermatol* 2003;42:305-7.
- 24 Ferrandiz C, Ribera M. Zoon's balanitis treated by circumcision. *J Dermatol Surg Oncol* 1984;10:622.
- 25 Altmeyer P, Kastner U, Luther H. Balanitis/balanoposthitis chronica circumscripta benigna plasmacellularis – entity or fiction? *Hautarzt* 1998;49:552-5.
- 26 Haneke E. Skin disease and tumors of the penis. *Urol Int* 1982;37:172.
- 27 National guideline for the management of balanitis. *Sex Transm Inf* 1999;75 (Suppl 1):S85-8.
- 28 Morioka S, Nakajima S, Yaguchi H, Naito K, Iwahara K, Ogawa H. Vulvitis circumscripta plasmacellularis treated successfully with interferon alpha. *J Am Acad Dermatol* 1988;19 Part 2:947.
- 29 Skerlev M, Grce M, Sirotković-Skerlev M, Husnjak K, Lipozenčić J. Human papillomavirus male genital infections: clinical variations and the significance of DNA typing. *Clin Dermatol* 2002;20:173-8.