

From Circumscribed Scleroderma (Morphea) to Subcutaneous Panniculitis-Like T-Cell Lymphoma: Case Report

Nina Troškot¹, Liborija Lugović¹, Mirna Šitum¹, Majda Vučić²

¹Department of Dermatology and Venerology, ²Ljudevit Jurak Department of Pathology, Sestre milosrdnice University Hospital, Zagreb, Croatia

Corresponding author:

Liborija Lugović, MD, PhD

Department of Dermatology and Venerology

Sestre milosrdnice University Hospital

Vinogradska c. 29

10000 Zagreb, Croatia

liborija@yahoo.com

Received: 18.03.2004.

Accepted: 19.09.2004.

SUMMARY Subcutaneous panniculitis-like T-cell lymphoma is a rare form of non-Hodgkin lymphoma. It presents clinically as panniculitis, with erythematous, firm subcutaneous infiltrates and recurrent papulonodules. A 45-year-old male Croat presented with a 6-month history of tender erythematous subcutaneous skin lesions without systemic symptoms. Analysis of a lesion biopsy specimen showed circumscribed scleroderma (morphea). During hospitalization, skin biopsies from two subcutaneous lesions on the stomach were repeated, and pathohistologic analysis corresponded primarily to panniculitis in the context of morphea. Pathohistologic analysis and immunohistochemistry of a specimen obtained by tumor excision from the back indicated subcutaneous panniculitis-like T-cell lymphoma. Histologic analysis revealed a dense infiltrate of atypical T-lymphoid cells expressing CD8+ phenotype located in the subcutaneous tissue with histiocyte-phagocytizing apoptotic cells. Specific hematologic analysis and medical treatment were continued. This case report illustrates the importance of continuous follow-up with repeat biopsy and use of immunohistologic techniques for early diagnosis.

KEY WORDS subcutaneous panniculitis-like T-cell lymphoma, circumscribed scleroderma, morphea, immunohistochemistry

Introduction

Subcutaneous tissue is an uncommon primary localization for T-cell lymphomas, and subcutaneous panniculitis-like T-cell lymphoma (SPTCL) is a rare form of lymphoma, representing less than 1% of all non-Hodgkin lymphomas (1-3). It presents clinically as panniculitis, with erythematous, firm subcutaneous infiltrates and recurrent papulonodules. SPTCL is a cytotoxic T-cell lymphoma composed of atypical lymphoid cells of varying size, often with marked tumor necrosis and karyorrhexis (4,5).

Neoplastic cells show rearrangement of T-cell receptor genes, and are negative for Epstein-Barr viral sequences (4-6). T-cell gene rearrangement studies demonstrate a monoclonal T-cell receptor (gamma-chain) gene rearrangement, further supporting the diagnosis of SPTCL. No specific cytogenetic features have been reported.

There is no evidence that there is a true precursor lesion. Patients present with multiple subcutaneous nodules, and the most common sites of lo-

calization are the extremities and the trunk, mostly the legs (3-5). The nodules range from 0.5 cm to several centimeters in diameter. Systemic symptoms are variable.

Histopathology analysis shows that cell infiltrate spares the dermis, which is helpful in the differential diagnosis from other lymphomas involving the skin and subcutaneous tissue, although cases of gamma-delta T-cell origin may show both dermal and epidermal involvement (5). In the fat tissue, there is lobular involvement with necrosis, nuclear debris and occasionally erythrophagocytosis (3-5). The characteristic finding of SPTCL are the 'bean-bag' histiocytic cells (macrophages laden with erythrocytes), which are considered to be the products of hemophagocytosis, regularly seen in bone marrow (7).

Immunophenotype analysis of the infiltrated cells shows a mature T-cell phenotype, usually CD8-positive, with expression of cytotoxic molecules including T-cell intracellular antigen (TIA-1), granzyme B, and perforin. Most cases are derived from alpha-beta cells, although 25% of cases may be gamma-delta positive, which are often double negative for CD4 and CD8, and positive for CD56 (4,5). Curiously, the infiltrate in the initial biopsies may have a quite benign appearance.

Case Report

A 45-year-old male Croat presented with a 6-month history of tender erythematous subcutaneous skin lesions without systemic symptoms. At the end of June 2002, the patient noticed a tender, erythematous pimple in his left pectoral region, which was enlarging and gradually centrifugally spreading. Afterwards, the skin lesion appeared livid-colored, with palpable markedly hardened area. The patient denied tick bite or trauma. In September 2002, cytologic specimen of the lesion was done, and the finding indicated a mesenchymal tumor. The result of serologic test to *Borrelia burgdorferi* was negative. In November 2002, the patient was referred to the Department because of the lesion deterioration with marked pain and restriction of motion in his shoulders. Biopsy of the lesion was made, and the analysis showed circumscribed scleroderma (morphea). On hospitalization, the patient had an infiltrated 5-cm livid-brown area in his left

pectoral region, which was hard and tender on palpation, with a central postoperative 1-cm scar (Fig. 1). In his infraumbilical region, there were two 1.5-cm subcutaneous nodular lesions covered by erythematous-livid skin. Also, in his left preauricular region, there were similar skin changes of 1-cm in size. On the scalp, in the left retroauricular region, there was a 1.5-cm hairless area, with spared hair follicles and negative 'light pull' test.

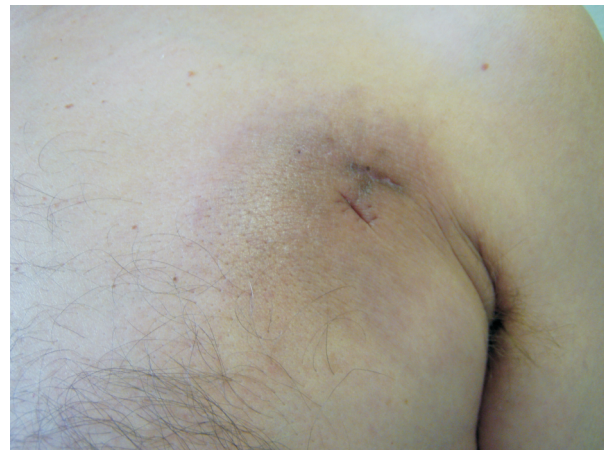

Figure 1. Skin lesion in the patient with SPTCL.

During hospital stay, skin biopsies from two subcutaneous lesions from the abdomen (in the left and right periumbilical regions) were repeated and pathohistologic analysis corresponded first of all to panniculitis in the context of morphea. Biopsy of the scalp area was also obtained, however, its analysis showed nonspecific result. The patient did not receive any therapy during hospitalization.

Analysis of the patient's blood showed mostly normal results: ANA negative, anti ds-DNA 23.80 (normal). Laboratory findings: ESR 4; L $5.1 \times 10^9/L$; E $5.01 \times 10^{12}/L$; Hb 151g/L; Htc 0.453 L/L; Plt $173 \times 10^9/L$; urine: normal finding; BG 4.4 mmol/L; total protein 74 g/l; alkaline phosphatase 80 U/L; C3 and C4 normal; rheuma test 25.9 IU/ml (normal); transaminases and hepatogram normal; fibrinogen 4.1 g/L; immunoelectrophoresis within normal limits; lung x-ray: hyperinflation of pulmonary parenchyma with basal emphysematous bullae; abdominal US normal; no axillary lymph nodes. Due to unclear results of repeated histologic analysis, tumor excision from the back was also done. Then, biopsy material was referred to another institution (Dr. Bettina Zelger, Institute of Pathology, University of

Innsbruck, Innsbruck, Müllerstr. 44, A-6020 Innsbruck, Austria) for further analysis to assist in reaching the diagnosis, and pathohistologic analysis indicated SPTCL (Figs. 2 and 3). Immunohistochemistry and T-cell intracellular antigen (TIA) marker analysis were performed at a consultative laboratory and revealed strong positive immunohistochemistry reaction (reactions performed by use of the following antibodies: anti CD4, anti-CD8 and TIA) (not shown).

Histopathology showed abundant subcutaneous tissue with hyperkeratotic stratum corneum, but no major changes in the epidermis. Rare to moderate infiltration of mononuclear cells was shown in the reticular dermis in the periadnexal space. Collagen fibers were found in the reticular dermis, which was focally thickened and with rare infiltration of

mononuclear cells between them. Subcutaneous tissue showed abundant infiltration surrounding individual fat cells, mostly composed of lymphoid cells and histiocytic cells, and focally neutrophils. Lobular septa in the fat tissue were spared.

Immunophenotype analysis of infiltrated cells showed them to be CD8-positive and CD4-negative (a mature T-cell phenotype), and the cells showed expression of cytotoxic molecules including T-cell intracellular antigen (TIA-1). This immunohistochemistry finding indicates SPTCL. The patient's treatment continued at Department of Hematology, Merkur University Hospital, and Department of Radiology, Zagreb University Hospital Center, Zagreb, where he received radiotherapy. Radiotherapy of 4750 cGy in 19 fractions was administered to the pectoral region and radiotherapy of 5000 cGy in 20 fractions to the upper abdomen. One year later, the patient was alive, not receiving any therapy but medical follow-up.

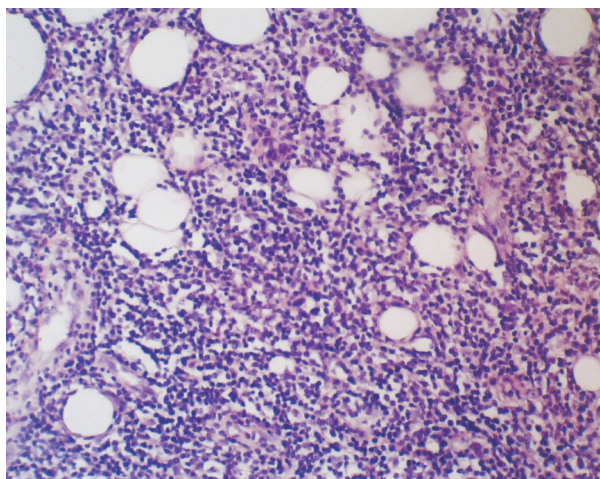


Figure 2. Dense lymphatic cell infiltration of subcutaneous fat tissue (hematoxylin-eosin, X200).

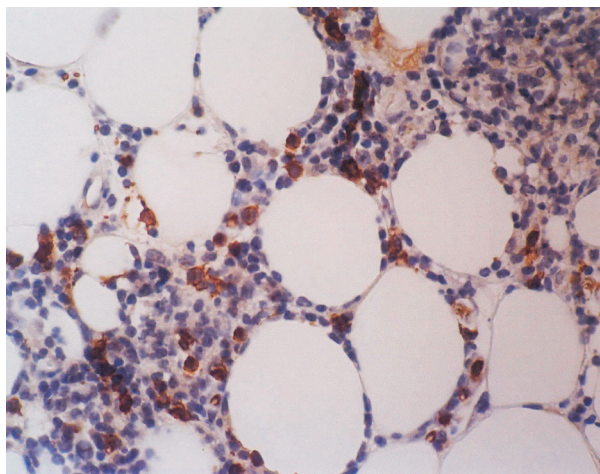


Figure 3. Immunohistochemistry of infiltration showing positive reaction for CD8 antigen marker (X400).

Discussion

Histologic analysis of inflammatory skin lesions poses a difficult task in characterizing an unknown clinical process by analysis of a single lesion, and sometimes very complex algorithms, as mentioned in the Results section (8). The changes only in the dermis/subcutaneous tissue indicate vasculitis and lymphoma, or lymphocytic, neutrophilic, eosinophilic, lymphoplasmocytic or granulomatous changes, whereas the changes mainly in the subcutaneous tissue may point to vasculitis and lymphoma or a type of panniculitis, e.g., septal and/or lobular (8). The subcutaneous lymphoid infiltrates represent a spectrum of histologic, immunophenotypic and molecular abnormalities, which range from clearly benign to clearly neoplastic (9). SPTCL has been thought to represent a very specific clinicopathologic entity, but clinical experience indicates that its histologic appearance can be closely mimicked by reactive and benign conditions. Lymphoid atypia, erythrophagocytosis, loss of certain pan T-cell markers, a reduced CD4/8 ratio, and TCR rearrangement define subcutaneous T-cell lymphoid dyscrasia, including a subset of lupus erythematosus profundus, and indeterminate lymphocytic lobular panniculitis (9).

The histopathologic picture of SPTCL shows the infiltrate of neoplastic cells to extend diffusely through the subcutaneous tissue, but the overlying dermis and epidermis are typically uninvolved. A helpful diagnostic feature is the reminding of the neoplastic cells surrounding individual fat cells (4,5). Admixed reactive histiocytes are frequently present, particularly in the areas of fat infiltration and destruction, and often vacuolated due to the ingested lipid material (4,5). The cellular constituents in SPTCL belong to different cell populations: tumor lymphoid cells, many macrophages, endothelial, fibroblasts, and fat cells. Yamazaki *et al.* in a case of SPTCL found tumor cells immunostaining positive for CD3, CD8, cytotoxic injury granule-related antigens of TIA-1 and granzyme B, but negative for CD4, CD30, CD56, EBNA-2, LMP-1, CD20cy, and CD68 (1). An ultrastructural study revealed that the lymphoma cells showed primitive cellular contacts with the neighboring tumor cells, interacted with the short villous dendrites of the opposing macrophage and fibroblast cellular membranes, and were associated with the vascular constituents, fat cells, and extracellular matrix (1,3). Our case report based on a patient with SPTCL is compatible with other cases, as the histologic analysis also revealed a dense infiltrate of atypical T-lymphoid cells expressing the CD8+ phenotype and TIA-1, located in the subcutaneous tissue with histiocyte-phagocytizing apoptotic cells (7).

The main differential diagnosis of SPTCL is to be made with cytophagic panniculitis, which can be viewed as subcutaneous involvement in the hemophagocytic syndrome. The nature of lymphocytes in panniculitis is the most helpful clue; if they are cytologically normal and polyclonal, then perhaps an inflammatory process is present (3).

The problem is in the necessity for repeat biopsy, as demonstrated in our case of SPTCL, where the first histology finding was circumscribed scleroderma (morphea), whereas the repeat biopsy revealed SPTCL. Cocciale *et al.* also report on a case of small-cell pleiomorphic non-Hodgkin lymphoma developed initially in subcutaneous tissue, followed by secondary systemic extension, where the first clinical manifestation was a scleroderma-like syndrome involving all the four limbs (2). The presentation of a case of SPTCL that has eluded diagnosis for 14 years illustrates the importance of

continued follow-up with repeat biopsy (10). Namely, multiple biopsies demonstrated either a nonspecific panniculitis or lipomembranous panniculitis with calcified lipomembranes. A review of 72 SPTCL cases from the English language literature also may be of importance to approach, diagnose and treat this rare lymphoma (10).

There are still other studies in patients with SPTCL aiming at disclosing some new data on this rare type of lymphoma (11-14).

Conclusion

Subcutaneous panniculitis-like T-cell lymphoma is a very aggressive lymphoma and most patients succumb to it within a short period of time. In spite of its aggressive natural history, the patients may respond effectively when early multidrug chemotherapy regimens are introduced.

Although SPTCL has been thought to represent a very specific clinicopathologic entity, the clinical experience shows that its histologic appearance can be closely mimicked by reactive and benign conditions. This report illustrates the importance of continued follow-up with repeat biopsy when SPTCL or another lymphoma is suspected. Physicians should be aware of this type of lymphoma and the importance of employing immunohistologic techniques for early diagnosis, which can sometimes save the patient's life.

References

- 1 Yamazaki K. An ultrastructural study of cutaneous panniculitis-like T-cell lymphoma: cytoplasmic granules and active cellular and cell-to-matrix interaction mimic cytotoxic T-cells. *Ultrastruct Pathol* 2002;26: 185-90.
- 2 Cocciale MP, Plenat F, Reichert S, Modiano P, Barbaud A, Weber M, *et al.* Chronic scleroderma-like syndrome disclosing subcutaneous T-cell lymphoma. *Ann Dermatol Venereol* 1997;124:393-6.
- 3 Braun-Falco O, Plewig G, Wolff HH, Burgdorf WHC, eds. *Dermatology*. 2nd completely revised edition. Berlin: Springer-Verlag, 2000.
- 4 Anonymous. Tumours of haematopoietic and lymphoid tissue. In: Jaffe ES, Harris NL, Stein H, Vardiman JW, eds. *World Health Organization Classification of Tumours*, 2001.
- 5 Jaffe ES, Krenacs L, Raffeld M. Classification of cytotoxic T-cell and natural killer cell lymphomas. *Semin Hematol* 2003;40:175-84.

- 6 Yung A, Snow J, Jarrett P. Subcutaneous panniculitic T-cell lymphoma and cytophagic histiocytic panniculitis. *Australas J Dermatol* 2001;42:183-7.
- 7 Ikeda E, Endo M, Uchigasaki S, Baba S, Suzuki H, Kimikawa N, *et al.* Phagocytized apoptotic cells in subcutaneous panniculitis-like T-cell lymphoma. *J Eur Acad Dermatol Venereol* 2000;15:159-62.
- 8 Hugel H. Histological diagnosis of inflammatory skin diseases. Use of a simple algorithm and modern diagnostic methods. *Pathologe* 2002;23:20-37.
- 9 Magro CM, Crowson AN, Kovatich AJ, Burns F. Lupus profundus, indeterminate lymphocytic lobular panniculitis and subcutaneous T-cell lymphoma: a spectrum of subcuticular T-cell lymphoid dyscrasia. *J Cutan Pathol* 2001;28:235-47.
- 10 Weenig RH, Ng CS, Perniciaro C. Subcutaneous panniculitis-like T-cell lymphoma: an elusive case presenting as lipomembranous panniculitis and a review of 72 cases in the literature. *Am J Dermatopathol* 2001;23:206-15.
- 11 Dargent JL, Diedhiou A, Lothaire P, Demunter A, Lespagnard L, De Wolf-Peeters C. Subcutaneous lymphoid hyperplasia arising at site of ethnic scarifications and mimicking subcutaneous panniculitis-like T-cell lymphoma. *Virchows Arch* 2001;438:298-301.
- 12 Assmann K, Nashan D, Grabbe S, Luger TA, Metz D. Persistent inflammatory reaction at the injection site of IL-2 with lymphoma-like inflammatory infiltrates. *Hautarzt* 2002;53:554-7.
- 13 McGinnis KS, Shapiro M, Junkins-Hopkins JM, Smith M, Lessin SR, Vittorio CC, *et al.* Denileukin diftitox for the treatment of panniculitic lymphoma. *Arch Dermatol* 2002;138:740-2.
- 14 Thomson AB, McKenzie KJ, Jackson R, Wallace WH. Subcutaneous panniculitic T-cell lymphoma in childhood: successful response to chemotherapy. *Med Pediatr Oncol* 2001;37:549-52.