

Laser Therapy for Solar Lentigines: Review of the Literature and Case Report

Zrinka Bukvić Mokos, Jasna Lipozenčić, Aida Pašić, Iva Fattorini¹

University Department of Dermatology and Venereology, Zagreb University Hospital Center, Zagreb, Croatia; ¹The Cleveland Clinic Foundation, Cleveland, USA

Corresponding author:

Zrinka Bukvić Mokos, MD, MS
University Department of
Dermatology and Venereology
Zagreb University Hospital Center
Šalata 4
HR-10000 Zagreb
Croatia
zrinka.bukvic@zg.htnet.ht

Received: January 17, 2006

Accepted: April 5, 2006

SUMMARY Solar lentigines are benign, brownish lesions that occur on light exposed skin surfaces from age 30 onwards, as a sign of photoaging. As they are of cosmetic importance to many patients, different therapeutic modalities have been tried to remove these unwanted spots. The recent development of short-pulsed, pigment-specific lasers has enabled physicians to selectively destroy the pigment within the solar lentigo lesions with significant clinical improvement, low risk of adverse effects, and high patient acceptance. Therefore this therapeutic option is superior to traditional treatment modalities and represents the treatment of choice in the management of solar lentigines. A case is reported of the successful use of Q-switched ruby laser in the treatment of solar lentigo on the face.

KEY WORDS: solar lentigines; laser therapy; dermoscopy

INTRODUCTION

Solar lentigines are the most common hyper-melanotic lesions of photoaged skin. They occur from age 30 onwards as benign hyperpigmented lesions on chronically sun-exposed areas of the face, back of the hands, and extensor surfaces of the forearms. The lesions vary in size from 0.2 to 2.0 cm; the intensity of their pigmentation is not related to the amount of solar radiation and they do not bleach in seasons with little sunlight. The spots increase in number with advancing age. Although lentigines are not premalignant lesions, they are significant cosmetic nuisance for many middle-aged and elderly patients (1).

A number of synonyms have been used for solar lentigines reflecting the relation with age and chronic sun exposure: sun-induced freckles, sunburn freckles, freckles in adulthood, age spots, senile and actinic lentigines. Several studies have confirmed these spots to be more prevalent with increasing age, and found them to be associated

with chronic cumulative sun exposure and cutaneous signs of aging. They are also related to the accumulation of intermittent sun exposure and painful sunburns before age 20 (2,3).

The most prominent histological features of solar lentigo include hyperpigmentation of the basal cell layer with a marked increase in the number of melanocytes and small acanthotic protrusions. Solar lentigo may be difficult to distinguish from other pigmented lesions present on the skin of almost all elderly patients, including flat seborrheic keratoses, flat pigmented actinic keratoses, ephelides and nevocellular nevi. Probably many solar lentigines are initially verruca plana-like seborrheic keratoses (1,4,5).

Solar lentigines have been treated with a number of modalities, including chemical and instrumental approaches. Topical tretinoin, depigmenting agents, and to a lesser extent alpha-hydroxy acids have been used with variable results. Surgi-

cal procedures such as liquid nitrogen cryotherapy, chemical peeling with trichloroacetic acid, phenol and alpha-hydroxy acids and dermabrasion are also widely used. Most recently, laser surgery has imposed as the treatment of choice for solar lentigines because of its ability to selectively destroy pigment without injury to surrounding tissue. The last but not the least, photoprotection from early childhood may prevent the appearance of these lesions (limitation of mid-day sun exposure, UVA and UVB sunscreens, photoprotective clothing, etc.) (3-8).

LASER PRINCIPLES

Recent technologic advancements in cutaneous laser surgery have provided a safe and reliable means for treating many cutaneous concerns and congenital defects, including pigmented lesions. The original idea of using lasers to remove pigment-containing lesions belongs to Leon Goldman, who pioneered the use of ruby laser (694 nm) in the early 1960s to treat different skin lesions, including pigmentary disorders (9). Cutaneous laser surgery was revolutionized in 1983, when Anderson and Parish proposed the theory of selective photothermolysis. The theory describes how controlled destruction of targeted lesion is possible with minimal damage to the adjacent tissues. To achieve this selective effect, 3 requirements must be achieved: first, the emitted wavelength must be absorbed preferentially by the intended tissue target or chromophore (molecules with unique absorption spectra which are responsible for imparting color to substances); second, the energies produced by laser systems should be sufficiently high to inflict thermal damage to the target; and third, the time of tissue exposure to the laser must be shorter than the thermal relaxation time (defined as the time required for the targeted side to cool to one half of its peak temperature immediately after laser irradiation) to limit the damage to the target without heat diffusion to the surrounding tissue. On the basis of these principles, laser parameters can be tailored to destruction of the tissue confined to microscopic sites of selective light absorption in the skin, such as blood cells and pigmented cells, with minimal collateral thermal damage (10).

LASER THERAPY OF SOLAR LENTIGINES

Laser therapy is superior to the traditional methods in treating solar lentigines, with a minimal risk of permanent sequels. In solar lentigines, melanin

is the chromophore which is the target for selective destruction. Early laser technologies were limited to the use of continuous wave (CW) lasers for pigment removal (ruby, argon, CO₂ systems), which yielded high rates of hypertrophic scarring and pigmentary alteration because the nonselective tissue injury involved adjacent cutaneous structures (11,12).

To obtain selective photothermolysis of melanin, solar lentigines must be treated with laser light of a wavelength appropriate to absorption characteristics of melanin. Because melanin has a broad absorption spectrum, a variety of different laser systems which emit wavelengths of 500-1100 nm may be used to remove melanin from the skin. However, treatment efficacy decreases as the wavelength increases. Ideally, the pulse duration should be shorter than the thermal relaxation time of melanin, which is relatively short, ranging from 50 to 500 ns (13).

The development of short-pulsed, Q-switched (QS) lasers (pulse duration 5-100 ns) enabled eradication of pigmented lesions with a minimal risk of untoward effects. These lasers have electro-optical shutters that permit release of stored energy within the laser cavity in short high-energy bursts, delivering power outputs as high as 109 W. The following pigment-selective, short pulse lasers are in clinical use for solar lentigo removal today: pigmented lesion pulsed dye laser (510 nm), Q-switched ruby laser (694 nm), Q-switched alexandrite laser (755 nm) and Q-switched Nd:YAG laser (1064 nm), which can be frequency-doubled to produce visible green light at a wavelength of 532 nm. Usually, a series (two or more) of laser sessions at six- to eight-week intervals are necessary to achieve complete removal of the lesion (11,12).

Pigmented lesion dye laser

The pigmented lesion dye laser emits light at a 510 nm wavelength and pulse duration of 300 ns, which enables targeting superficial melanosomes. Although no longer commercially available, this laser is effective in the treatment of lentigines and other epidermal pigmented lesions. Immediately after irradiation, an ash-grey discoloration of the skin develops, and up to 50% of patients develop purpura due to absorption of laser energy by oxyhemoglobin. A fine crust typically forms over the laser treated area and peels off after in a week (11,12,14).

Q-switched ruby laser (QSRL)

The Q-switched ruby laser (QSRL) emits visible red light at a wavelength of 694 nm, pulse duration of 28 to 50 ns, spot size of 3.5 to 6.5 mm, and repetition rate of 1 Hz. This wavelength is so well-absorbed by melanin that permanent hypopigmentation and depigmentation may occur in darker-skinned individuals. The absorption of ruby laser energy by hemoglobin is minimal. Similar to the aforementioned laser, a crust is formed at the site of laser irradiation and peels off in several days (15-17).

Q-switched alexandrite laser

This laser operates at a wavelength of 755 nm, with pulse duration of 50-100 ns, spot size of 2-4 mm, and repetition rate of 1-15 Hz. Due to its longer pulse duration, the alexandrite laser produces less tissue splatter during laser irradiation. In addition, its longer wavelength permits deeper tissue penetration and less unwanted hypopigmentation compared with QSRL. Postoperative healing is similar to that with other QS pigment-specific lasers, yet the lesion produced is considered less severe (11,12,18).

Q-switched Nd:YAG laser

It emits 1064-nm light but can also be frequency-doubled using a potassium diphosphate crystal to produce visible green light at a wavelength of 532 nm. These systems usually have pulse duration ranging from 10 to 20 ns, spot size of 1.5-4 mm, and repetition rate of 1-10 Hz. Melanin has a strong affinity for 532-nm green light, whereas the

longer 1064-nm wavelength penetrates the skin more deeply but with a lower melanin absorption coefficient. After the use of smaller spot sizes, tissue splatter usually occurs, leading to crusting that may take several weeks to fully resolve (19,20).

A recent study compared the efficacy of three lasers and liquid nitrogen in the treatment of solar lentigines. Laser therapy was found to be superior to liquid nitrogen in this indication. Furthermore, the frequency doubled QS Nd:YAG laser was more effective compared to HGM K1 krypton laser and 532 nm diode-pumped vanadate laser (21).

CASE REPORT

A 58-year-old woman with type II skin presented to our Department with uniformly a colored brown macule with sharply demarcated polycyclic borders, which persisted on her right cheek for about 30 years with slow progression. The size of the lesion was 20x17 mm (Fig. 1). There was no family history of skin diseases. The lesion was clinically evaluated as solar lentigo. However, according to the ABCD rule (**A**symmetry, irregular **B**orders, **C**olor variegation, **D**iameter larger than 6 mm), the differential diagnosis included lentigo maligna. Therefore, biopsy was performed and histological analysis revealed thickened epidermis, papillomatosis and hyperpigmentation of the basal layer of the epidermis, which was consistent with solar lentigo. The lesion was treated with QSRL at a fluence of 2,5 J/cm² using nonoverlapping 5-mm spot size. After the first session, the lesion was partially lightened (Fig. 2), and the treatment was repeated with the same parameters 6 weeks later.

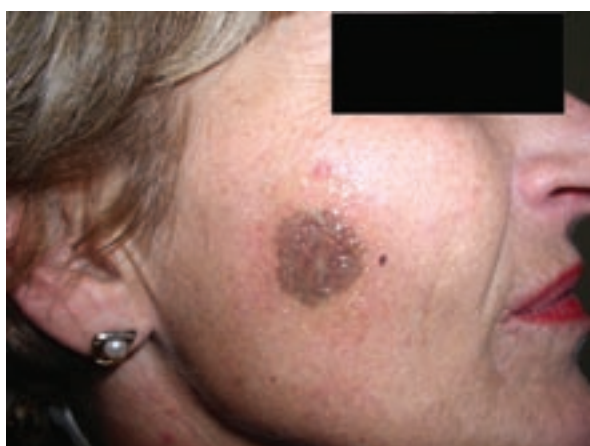

Figure 1. Solar lentigo lesion before the treatment with QSLR.

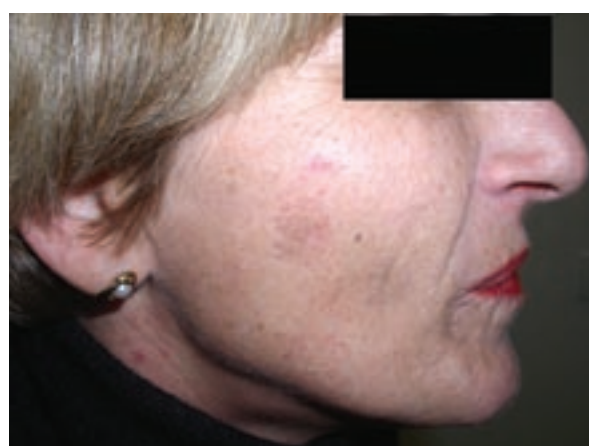

Figure 2. The result of one session with QSRL.

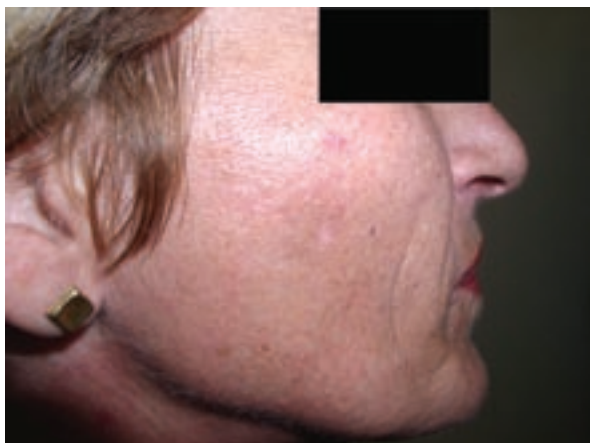


Figure 3. The result of two sessions with QSRL.

After the second treatment we observed total removal of the pigment without unwanted sequelae (Fig. 3).

CONCLUSION

Understanding the effects of laser light on the skin and using this knowledge to manufacture new usable technology have provided selective removal of different skin lesions, including solar lentigines. Nowadays, laser therapy is considered to be the treatment of choice for solar lentigines (22). However, responses to treatment with lasers are variable. Treatment failure may occur if pigment remains at a greater tissue depth than the laser can reach, or in case of repigmentation by stimulated melanocytes within adnexal epithelium. Thus, the patient should be informed on the risk of pigmentary recurrence and the need of repeat treatment. As the risk of repigmentation is enhanced with UV light exposure, photoprotection is strongly recommended (11).

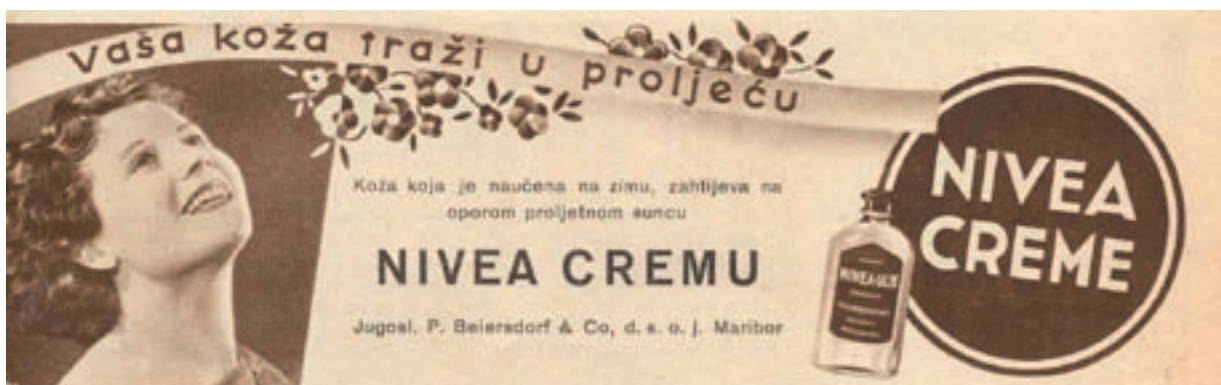The essential question in removing pigmented lesions with lasers is whether the lesion has atypical features or a malignant potential. There are no definitive answers, and decision should always be made on individual basis. Some authors recommend dermoscopy in every case of solar lentigo, regardless of the benign clinical appearance, as in their opinion solar lentigo lesions are almost always "ABCD-positive" (23). Furthermore, if there is any doubt whether the lesion is benign, then biopsy for histological evaluation is mandatory (11,24).

When patients are properly selected and standard treatment parameters are followed, the high-energy, short-pulsed lasers are safe and effective tools for removal of solar lentigines.

References

1. Braun-Falco O, Plewig G, Wolf HH, Burgdorf WH. Disorders of melanin pigmentation. In: Braun-Falco O, Plewig G, Wolf HH, Burgdorf WH, editors. *Dermatology*. 2nd completely revised ed. Berlin: Springer Verlag; 2000. p. 686-709.
2. Bastiaens M, Hoefnagel J, Westendorp R, Vermeer BJ, Nico J. Solar lentigines are strongly related to sun exposure in contrast to ephelides. *Pigment Cell Res* 2004;17:225-9.
3. Monestier S, Gudy C, Gouvernet J, Richard MA, Grob JJ. Multiple senile lentigos of the face, skin ageing pattern resulting from a life excess of intermittent sun exposure in dark-skin Caucasians: a case-control study. *Br J Dermatol* 2005;153 Suppl 2:1-7.
4. Elgart GW. Seborrheic keratoses, solar lentigines, and lichenoid keratoses. Dermatoscopic features and correlation to histology and clinical signs. *Dermatol Clin* 2001;19:77-83.
5. Ortonne JP. Dyspigmentation of aged skin. *Eur J Dermatol* 2001;11:168-9.
6. Briganti S, Camera E, Picardo M. Chemical and instrumental approaches to treat hyperpigmentation. *Pigment Cell Res* 2003;16:101-10.
7. Farris PK. Combination therapy for solar lentigines. *J Drugs Dermatol* 2004;3:S23-6.
8. Stern RS, Dover JS, Levin JA, Arndt KA. Laser therapy *versus* cryotherapy of lentigines: a comparative trial. *J Am Acad Dermatol* 1994;30:985-7.
9. Stratigos AJ, Dover JS, Arndt KA. Laser treatment of pigmented lesions - 2000. *Arch Dermatol* 2000; 136:915-21.
10. Anderson RR, Parish JA. Selective photothermolysis: precise microsurgery by selective absorption of pulsed irradiation. *Science* 1983;22:524-7.
11. Alster TS, Lupton JR. Laser therapy for cutaneous hyperpigmentation and pigmented lesions. *Dermatol Ther* 2001;14:46-54.
12. Tanzi EL, Lupton JR, Alster TS. Lasers in dermatology: for decades of progress. *J Am Acad Dermatol* 2003;49:1-31.
13. Margolis RJ, Dover JS, Polla LL, Watanabe S, Shea CR, Hruza GJ. Visible action spectrum for melanin-specific selective photothermolysis. *Lasers Surg Med* 1989;9:389-97.

14. Tan OT, Morelli JG, Kurban AK. Pulsed dye laser treatment of benign cutaneous pigmented lesions. *Lasers Surg Med* 1992;12:538-41.
15. Ashinoff R, Geronemus RG. Q-switched ruby laser treatment of labial lentigos. *J Am Acad Dermatol* 1992;27:809-11.
16. Goldberg DJ. Benign pigmented lesions of the skin. Treatment with the Q-switched ruby laser. *J Dermatol Surg Oncol* 1993;19:376-9.
17. Taylor CR, Anderson RR. Treatment of benign pigmented epidermal lesions by Q-switched ruby laser. *Int J Dermatol* 1993;32:908-12.
18. Rosenbach A, Lee SJ, Johr RH. Treatment of medium-brown solar lentigines using an alexandrite laser designed for hair reduction. *Arch Dermatol* 2002;138:547-8.
19. Li YT, Yang KC. Comparison of the frequency-doubled Q-switched Nd:YAG laser and 35% trichloroacetic acid for the treatment of face lentigines. *Dermatol Surg* 1999;25:202-4.
20. Kilmer SL, Wheeland RG, Goldberg DJ, Anderson RR. Treatment of epidermal pigmented lesions with the frequency-doubled Q-switched Nd:YAG laser: a controlled, single-impact, dose-response, multicenter trial. *Arch Dermatol* 1994;130:1515.
21. Todd MM, Rallis TM, Gerwels JW, Hata TR. A comparison of 3 lasers and liquid nitrogen in the treatment of solar lentigines. *Arch Derm* 2000;136:841-6.
22. Ortonne JP. Pigmentary changes of the ageing skin. *Br J Dermatol* 1990;35:21-8.
23. Moreno-Ramirez D, Ferrandiz L, Camacho FM. Are the ABCD signs useful for the management of solar lentigo? *Br J Dermatol* 2005;153:1083-4.
24. Lee PK, Rosenberg CN, Tsao H, Sober AJ. Failure of Q-switched ruby laser to eradicate atypical appearing solar lentigo: report of two cases. *J Am Acad Dermatol* 1998;38:314-7.



Nivea cream for your skin in the springtime, year 1934.
(from the collection of Mr. Zlatko Puntijar)