

Disseminated Hailey-Hailey Disease Treated with Topical Tacrolimus and Oral Erythromycin: Case Report and Review of the Literature

Sanja Peršić-Vojinović¹, Višnja Milavec-Puretić², Ivan Dobrić², Jaka Radoš², Sanja Špoljar³

¹Zagreb-Centar Health Center; ²University Department of Dermatology and Venereology, Zagreb University Hospital Center; ³Ministry of Defense, Republic of Croatia, Zagreb, Croatia

Corresponding author:

Sanja Peršić-Vojinović, MD
Zagreb-Centar Health Center
Runjaninova 4
HR-10000 Zagreb
Croatia
sanja.persic@email.t-com.hr

Received: June 5, 2006

Accepted: September 10, 2006

SUMMARY Hailey-Hailey disease is a rare autosomal dominant skin disorder that typically affects the intertriginous areas. The responsible defect has been identified in the gene named ATP2C1 on chromosome 3q21-24. We present a 50-year-old man with a 16-year history of blistering eruptions and positive familial history where this disease had appeared through four generations. The diagnosis was confirmed by histopathologic studies and negative immunofluorescence findings. A combination of topical tacrolimus therapy and oral erythromycin seemed to play a considerable part in this case, in which all of the lesions healed within 2 weeks.

KEY WORDS: Hailey-Hailey disease; autosomal dominant skin disorder; erythromycin; tacrolimus

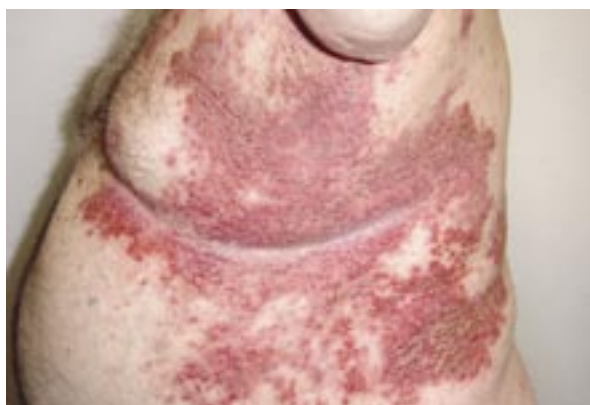INTRODUCTION

Hailey-Hailey disease is an autosomal dominant skin disorder that typically affects the intertriginous areas. The primary lesion is a flaccid vesicle or bulla on erythematous or normal skin, which ruptures easily and forms macerated erosions with crusting and scaling. Development of chronic vegetations and painful fissures is common, and it occurs without scarring, leaving post-inflammatory hyperpigmentations. The eruption runs a chronic course, and the lesions tend to wax and wane. Histopathologically, the classic findings in a fully developed lesion of Hailey-Hailey disease include the so-called dilapidated brick wall in which acantholysis occurs throughout the full thickness of the epidermis. The histopathologic findings in an early, unruptured vesicular lesion of Hailey-Hailey disease include incipient acantholysis marked by vacuoles around keratinocytes confined to the lower portion of the epidermis, which can be difficult to distinguish from pemphigus vulgaris.

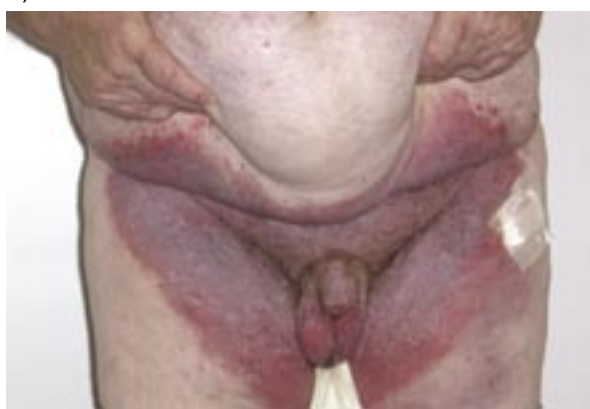We present a patient with disseminated Hailey-Hailey disease and therapeutic efficacy of 0.1% tacrolimus ointment combined with erythromycin *per os*.

CASE REPORT

A 50-year-old man with a 16-year history of flexural blistering eruptions presented with vesicles, erosions and erythema in the intertriginous areas and with multiple truncal lesions. Erythematous and livid lesions with odorous vegetations were found in the groin and genital region (Fig. 1a, b). Oral mucosa, larynx, esophagus and conjunctivae were not affected. His medical history included adiposity (140 kg) and arterial hypertension. His father, his oldest sister, her daughter and her niece had similar lesions (Fig. 2). They all were treated at our Department, where the disease was confirmed. Initial lesions in intertriginous areas were also found in his fraternal twin sister. Biopsy spec-



a)



b)

Figure 1a) and b). Lesions on the trunk and in the genital region

imens showed intraepidermal clefts of a varying size both suprabasally and higher in the epidermis as well as the characteristic incomplete acantholysis in large parts of the epidermis (Figs. 3 and 4). Results of direct and indirect immunofluorescence evaluation were negative.

In the initial phase of the disease, local corticosteroid therapy (betamethasone ointment) leads to complete regression; however, it is ineffective in disseminated forms of the disease. During the patient's first hospitalization at our Department, the local retinoid therapy applied did not result in healing. Systemic retinoid therapy with local corticosteroid applied intermittently reduced the disease activity. The initial dose of retinoid was 50 mg *per day*, gradually lowered down to 25 mg over 2 months and prolonged with 25 mg for one year more. Upon the disease relapse, the patient applied local corticosteroid therapy, which produced local side effects of skin atrophy and striae. Two years before, he experienced the last rapid exacerbation of the disease after exposure to UV radiation during summer. Then, during his last hospital stay, oral treatment with erythromycin, 2x500 mg

daily and 0.1% tacrolimus ointment resulted in healing of the erosions in 2 weeks, with post-inflammatory hyperpigmentations (Fig. 5a, b). Local therapy with tacrolimus ointment was prolonged for the next 2 months. When tacrolimus ointment therapy was interrupted, there was a recurrence of vesiculobullous lesions.

DISCUSSION

Hailey-Hailey disease, or familial benign chronic pemphigus, is a rare autosomal dominant condition that involves recurrent blistering of the skin (1-4). The pathomorphology of Hailey-Hailey disease originates in the epidermis of the skin, where there is suprabasal keratinocyte acantholysis usually involving all layers of the epidermis. This acantholysis results in a dilapidated brick wall appearance.

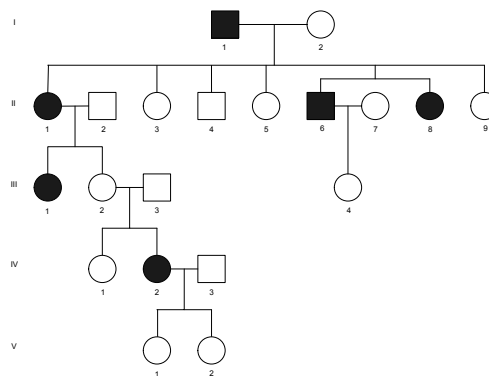


Figure 2. Pedigree: solid symbols, individuals affected by Hailey-Hailey disease (II-6 our patient, I-1 his father, II-1 his oldest sister, III-1 her daughter, IV-2 her grand-daughter, and II-8 his fraternal twin sister).

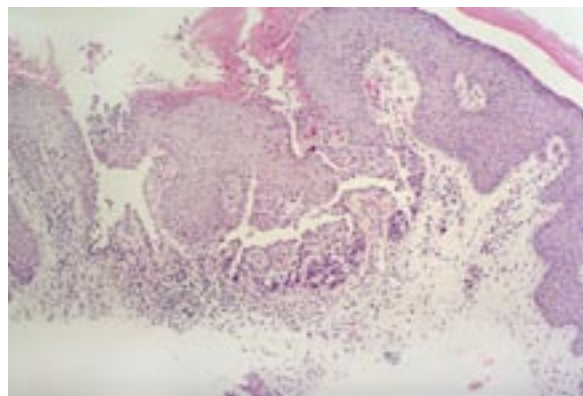


Figure 3. Intraepidermal clefts and incomplete acantholysis

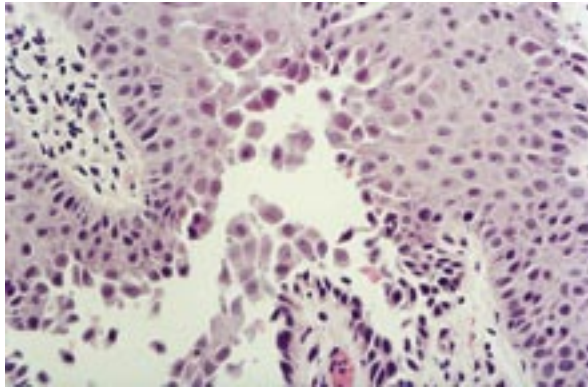
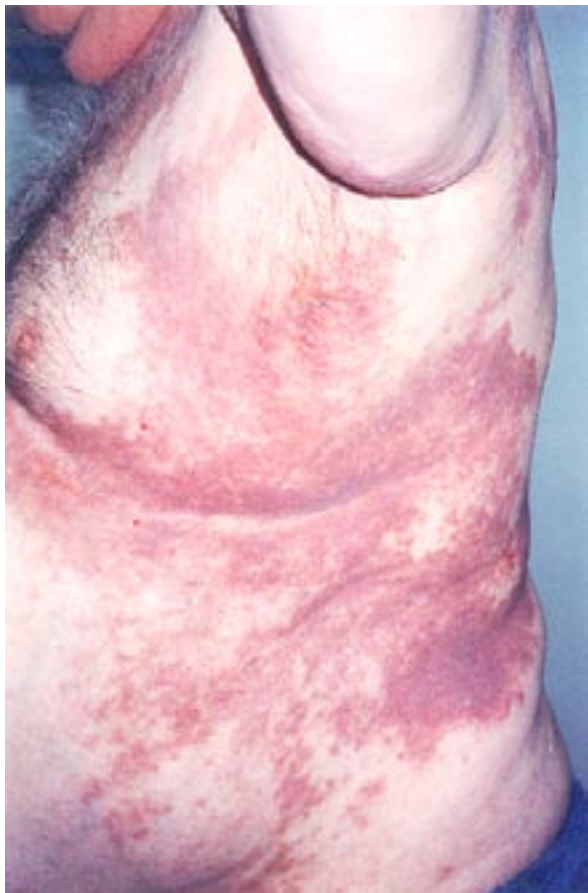

Figure 4. Intraepidermal clefts and incomplete acantholysis

At the molecular level, the manifestation of Hailey-Hailey disease has been attributed to the genetic defect of the ATP2C1 gene involving a calcium pump driven by adenosine triphosphate, resulting in altered levels of cytosolic calcium (3,4). What provokes the breakdown of the desmosome-keratin tonofilament complex resulting in acantholytic keratinocytes remains unknown and this may explain difficulties in the treatment of the disease,



often resulting in relapses. A variety of therapeutic modalities have been recommended for the treatment of Hailey-Hailey disease. Although none of these regimens provides "cure", they can suppress flare-ups. Recommendations range from antibiotics to control secondary bacterial infections through immunomodulating therapy with systemic and topical corticosteroids (5), cyclosporine (13,14), retinoid (15), and topical vitamin D (16). Other methods include photodynamic therapy with 5-aminolevulinic acid (17), dermabrasion (18), carbon dioxide laser therapy (19,20), and surgical excision (21). A common approach to the treatment of Hailey-Hailey disease is the use of topical steroids. The greatest benefit has been observed when topical corticosteroids are used promptly during the initial phases of eruptions. Due to long-term use and local side effects such as folliculitis, skin atrophy, striae and telangiectases, we wanted to apply steroid-free therapy during the patient's last hospitalization. Because of the disseminated distribution of the lesions, surgical methods and carbon dioxide laser treatment were not considered as an appropriate therapeutic option. The immunosuppressive agent cyclosporine has been proven to be effective in the treatment of Hailey-Hailey disease pemphigoid lesions. The problem with potential long-term cyclosporine utilization, however, lies in the risk of developing hypertension and nephrotoxicity. Due to disseminated lesions, local side effects of corticosteroid therapy and patient's persistent hypertension, we decided to treat our patient with another immunosuppressant, tacrolimus ointment, in combination with oral erythromycin. Tacrolimus, like cyclosporine, targets a calcium-activated phosphatase called calcineurin, that in turn reduces the activity of T-lymphocytes and blocks the expression of several cytokines (interleukins IL-2, IL-3, IL-4, IL-5, granulocyte-monocyte colony-stimulating factor, and tu-

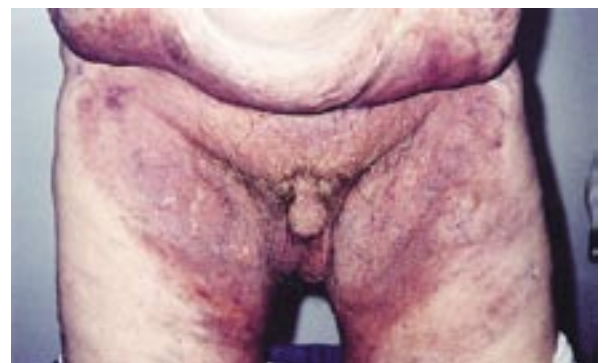

Figure 5a) and 5b). Lesions on the trunk and in the genital region after 2 weeks of therapy

mor necrosis factor α) resulting in inflammation, redness and itching. In addition, tacrolimus may also have direct effects on skin cells (keratinocytes). It appears to reduce the number of IL-8 cytokine receptors on the keratinocytes, hence reducing inflammation (22). It is suggested that the mechanism of action of topically applied tacrolimus ointment in Hailey-Hailey disease must be related in some way to the immunomodulating effect of the compound. We chose erythromycin because of its efficacy in another blistering disease (23,24). There are reports on its successful use in both children and adults for bullous pemphigoid. In addition, erythromycin is a safe treatment with no requirement for blood monitoring. The exact mechanism of action of erythromycin in bullous disorders is unknown but it is thought to be due to its anti-inflammatory action rather than antimicrobial effects. Erythromycin has been observed to inhibit neutrophil chemotaxis *in vivo*, and also has steroid-sparing properties. We started with systemic erythromycin therapy, 2x500 mg daily for 2 weeks, in combination with tacrolimus ointment. Local therapy with tacrolimus ointment was prolonged for the next 2 months as maintenance therapy. During therapy with tacrolimus we could not detect any symptoms or signs of systemic toxicity. When tacrolimus ointment therapy was interrupted there was a recurrence of vesiculobullous lesions.

CONCLUSION

We find it very interesting and valuable to present this rare hereditary disease which in our case had appeared through four generations. We could observe the impact of triggers (adiposity, sweating, UV radiation, secondary bacterial infections) on the disease exacerbation. In this case, the bullous lesions responded dramatically to topical tacrolimus ointment in combination with oral erythromycin. Considering that the reported cases of Hailey-Hailey disease which responded to topical tacrolimus ointment needed one month for resolution of the lesions (25,26), the combination of topical tacrolimus and oral erythromycin therapy seemed to play a considerable part in this disease, as the lesions healed within 2 weeks of treatment. In conclusion, we propose this combination therapy in patients with disseminated distribution of the lesions, and especially topical tacrolimus as steroid-free therapy also suitable for maintenance therapy.

References

1. Hwang LY, Lee JB, Richard G, Uitto JJ, Hsu S. Type 1 segmental manifestation of Hailey-Hailey disease. *J Am Acad Dermatol* 2003;49:712-4.
2. Hakuno M, Akiyama M, Shimizu H, Wheelock MJ, Nishikawa T. Upregulation of cadherin expression in the lesional skin of pemphigus, Hailey-Hailey disease and Darier's disease. *J Cutan Pathol*. 2001;28:271-81.
3. Bologna J. Hailey-Hailey disease: a second calcium pump gone away. *J Watch Dermatol* 2000;8:22.
4. Hu Z, Bonifas JM, Beech J, Bench G, Shigihara T, Ogawa H, *et al.* Mutations in ATP2C1, encoding a calcium pump, cause Hailey-Hailey disease. *Nat Genet* 2000;24:61-5.
5. Marsch WC, Stüttgen G. Generalized Hailey-Hailey disease. *Br J Dermatol* 1978;99:553-9.
6. Galimberti RL, Kowalczyk AM, Bianchi O, Bonino MV, Garcia AG. Chronic benign familial pemphigus. *Int J Dermatol* 1988;27:495-500.
7. Burge SM. Hailey-Hailey disease: the clinical features, response to treatment and prognosis. *Br J Dermatol* 1992;26:275-82.
8. Ruzicka T, Assmann T, Homey B. Tacrolimus, the drug for the turn of the millennium? *Arch Dermatol* 1999;135:574-80.
9. Lauerma AI, Maibach HI, Granlund H, Erkkö P, Kartamaa M, Stubb S. Inhibition of contact allergy reactions by topical FK506. *Lancet*. 1992;340:556.
10. Lauerma AI, Surber C, Maibach HI. Absorption of topical tacrolimus (FK506) *in vitro* through human skin: comparison with cyclosporin A. *Skin Pharmacol* 1997;10:230-4.
11. Michel G, Kemeny L, Homey B, Ruzicka T. FK506 in the treatment of inflammatory skin disease: promises and perspectives. *Immunol Today*. 1996;17:106-8.
12. Nasr IS. Topical tacrolimus in dermatology. *Clin Exp Dermatol* 2000;25:250-4.
13. Jitsukawa K, Ring J, Weyer U, Kimming W, Radloff H. Topical cyclosporine in chronic benign familial pemphigus (Hailey-Hailey disease). *J Am Acad Dermatol* 1992;27:625-6.
14. Ormerod AD, Duncan J, Stankler L. Benign familial pemphigus responsive to cyclosporine, a possible role for cellular immunity in pathogenesis. *Br J Dermatol* 1991;124:299-305.

15. Hunt MJ, Salisbury EL, Painter DM, Lee S. Vesiculobullous Hailey-Hailey disease: successful treatment with oral retinoids. *Australas J Dermatol* 1996;37:196-8.
16. Bianchi L, Chimenti MS, Giunta A. Treatment of Hailey-Hailey disease with topical calcitriol. *J Am Acad Dermatol* 2004;51:475-6.
17. Rodrigez RR, Alvarez JG, Jaén P, Acevedo A, Córdoba S. Photodynamic therapy with 5-aminolevulinic acid for recalcitrant familial benign pemphigus (Hailey-Hailey disease). *J Am Acad Dermatol* 2002;47:740-2.
18. Hamm H, Metze D, Bröcker EB. Hailey-Hailey disease. Eradication by dermabrasion. *Arch Dermatol* 1994;130:1143-9.
19. Kartamaa M, Reitamo S. Familial benign chronic pemphigus (Hailey-Hailey disease). Treatment with carbon dioxide laser vaporization. *Arch Dermatol*. 1992;128:646-8.
20. Cotton J, Hood AF, Gonin R, Beesen WH, Hanke CW. Histologic evaluation of preauricular and postauricular human skin after high-energy, short-pulse carbon dioxide laser. *Arch Dermatol* 1996;132:425-8.
21. Emiroglu M, Ercocen AR, Can Z, Gultan SM. Hailey-Hailey disease: a case report and treatment by surgical excision. *J Clin Dermatol* 1999;2:23-67.
22. Nghiem P, Pearson G, Langley RG. Tacrolimus and pimecrolimus: from clever prokaryotes to inhibiting calcineurin and treating atopic dermatitis. *J Am Acad Dermatol* 2002;46:228-41.
23. Cooper M, Powell J, Wojnarowska F. Linear IgA disease: successful treatment with erythromycin. *Clin Exp Dermatol* 2002;27:677-9.
24. Altomare G, Capella GL, Fracchiolla C, Frigerio E. Treatment of bullous pemphigoid with erythromycin: a reappraisal. *Eur J Dermatol* 1999;9:583-5.
25. Sand C, Thomsen HK. Topical tacrolimus ointment is effective therapy for Hailey-Hailey disease. *Arch Dermatol* 2003;139:1401-2.
26. Reuter J, Termeer C, Bruckner, Tuderman LB. Tacrolimus – a new therapeutic option for Hailey-Hailey disease? *J Dtsch Dermatol Ges* 2005;3:278-9.



Elida Ideal soap; year 1933.
(from the collection of Mr. Zlatko Puntijar)