

Löfgren's Syndrome Presenting with Erythema Nodosum-Like Eruption

Jaka Radoš, Jasna Lipozenčić, Diana Celić¹, Davorin Lončarić

University Department of Dermatology and Venereology, Zagreb University Hospital Center and School of Medicine; ²Medikol Clinic, Zagreb, Croatia

Corresponding author:

Jaka Radoš, MD, MS
University Department of Dermatology
and Venereology
Zagreb University Hospital Center
and School of Medicine
Šalata 4
HR-10000 Zagreb
Croatia
sodarakaj@yahoo.com

Received: August 18, 2007

Accepted: October 9, 2007

SUMMARY Löfgren's syndrome is an acute form of sarcoidosis that mostly presents with erythema nodosum, periarticular ankle inflammation, arthritis, conjunctivitis, and unilateral or bilateral hilar or right paratracheal lymphadenopathy. Erythema nodosum is the most common cutaneous lesion in acute sarcoidosis, but it is histologically nonspecific, as it does not reveal sarcoidal granulomas upon microscopic examination. We present a case of a 57-year-old woman with acute onset of tender erythematous nodules on the calves, which were clinically erythema nodosum-like lesions. Histologic analysis revealed sarcoidal granulomas located in the dermis and subcutaneous tissue. Upon further work-up, the patient was found to have both pulmonary and ocular sarcoidosis. Based on this case, we recommend that all patients with erythema nodosum-like lesions undergo biopsy and further work-up for sarcoidosis is recommended in case of biopsy proven sarcoidal granulomas.

KEY WORDS: erythema nodosum, sarcoidosis, Löfgren's syndrome

INTRODUCTION

Löfgren's syndrome is an acute form of sarcoidosis, a multisystemic granulomatous disease of unknown etiology that has a wide variety of clinical manifestations (1). In sarcoidosis, about 40%-50% of patients have cutaneous involvement (2). Cutaneous lesions are divided into specific and nonspecific lesions (2,3). Histopathologically, specific cutaneous lesions are granulomas, which consist of epithelioid macrophages, giant cells and a sparse lymphocytic infiltrate, and these may be found throughout the dermis and subcutaneous tissue (2).

Erythema nodosum (EN) is the most nonspecific cutaneous finding and is usually associated

with acute sarcoidosis and a benign course (4). Sarcoidal granulomas in erythema nodosum lesions are rare.

We present a case of Löfgren's syndrome and EN-like eruption with biopsy proven sarcoidal granulomas.

CASE REPORT

A 57-year-old woman presented to Dermatology Department for sudden onset of erythematous, subcutaneous nodules on the calves (Fig.1), and maculopapular rash on the dorsal aspects of the feet (Fig. 2). She complained of malaise and chills. She denied respiratory difficulties. On examination,

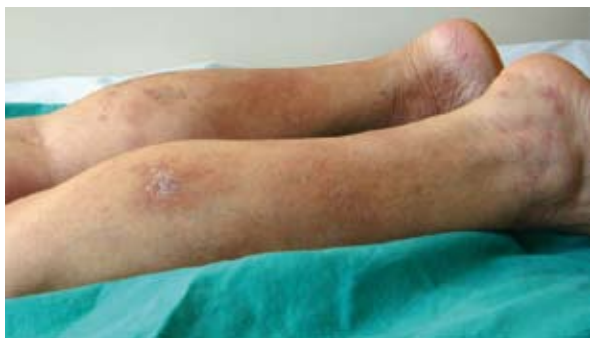

Figure 1. Erythematous subcutaneous nodules on the calves.

she was febrile but free from acute distress. Eye examination revealed findings typical of keratoconjunctivitis. Laboratory testing revealed a high erythrocyte sedimentation rate, elevated liver enzymes, serum angiotensin converting enzyme and alkaline phosphatase. Antinuclear antibody (ANA), antineutrophil cytoplasmic antibody (ANCA) and tuberculin skin test were negative. Complement levels, serum calcium and 24-h urine calcium levels were also within the normal limits.

Histopathology of the nodules showed circumscribed granulomas of epithelioid cells throughout the dermis with extension into the subcutaneous tissue (Fig. 3). Histology of the maculopapular lesions showed discrete, round to oval granulomas in the superficial dermis (Fig. 4). Mycologic examination of cutaneous lesions and syphilis serology were negative. Chest radiography showed bilateral hilar lymphadenopathy (Fig. 5). Total body gallium scan was normal.

The patient was treated with 40 mg of prednisone *per day* for six months. This resulted in prompt resolution of cutaneous lesions during the first month of therapy. Keratoconjunctivitis was treated with local application of steroids.

DISCUSSION

Sarcoidosis is an immune disorder, mediated primarily by CD4+ T-helper cells and cells derived from mononuclear phagocytes (5). Immune dysregulation has been postulated to be due to a persistent antigen of low virulence that is poorly cleared by the immune system, which in turn results in granuloma formation (6).

HLA B8, A1 and DR3 have been associated with the presence of EN and spontaneous resolution of the disease (7). HLA DR17 has been associated with acute onset of the disease and Löfgren's syndrome (8).

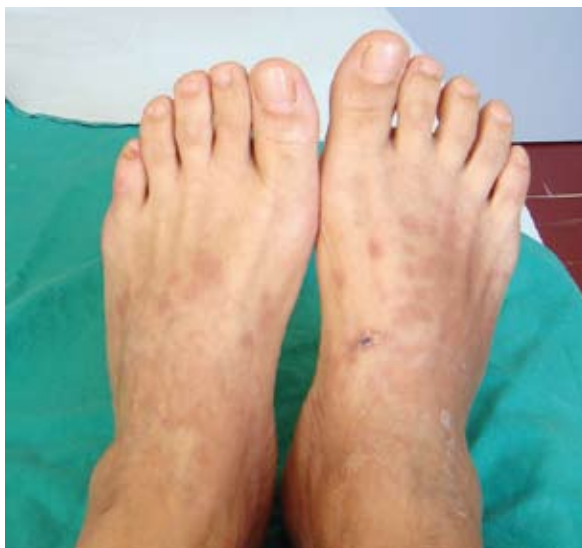

Figure 2. Maculopapular rash on the dorsal aspects of the feet.

Sarcoidosis can appear at any age with peaks between ages 25-35 and 45-65 (6). The course is variable, from a self-limited acute disease to a chronic disease that may result in death (9). EN, hilar lymphadenopathy, arthralgias and conjunctivitis are signs of acute sarcoidosis, which generally resolve (2).

Löfgren's syndrome was first recognized as an acute, benign form of sarcoidosis by Löfgren and Lundback (10,11). Mana *et al.* describe seasonal variation in Löfgren's syndrome, which usually starts in spring (9). Women are more frequently affected than men (2). Patients usually present with tender subcutaneous nodules on the anterior tibial area, fever, arthralgias, conjunctivitis, and bilateral hilar or paratracheal lymphadenopathy (2). Cutaneous involvement in sarcoidosis may occur at any stage of the disease (12). Cutaneous lesions are classified as specific when histologic examination shows typical sarcoidal granulomas, and as nonspecific (2). EN is a nonspecific cutaneous finding and has the same clinical and histologic appearance as EN lesions of other etiology (13). Septal pannicular inflammation is associated with some peripheral lobular inflammation as well as a superficial and deep dermal lymphocytic inflammatory infiltrate (14). Bacterial, fungal and viral infections, pregnancy, and malignancies such as Hodgkin's and non-Hodgkin's lymphoma, leukemia and renal carcinoma have been associated with EN (14-17). Autoimmune diseases (Sjögren's syndrome, Reiter's syndrome, systemic lupus erythematosus, Behçet's syndrome) can also be underlying conditions (18,19). In adults, the leading

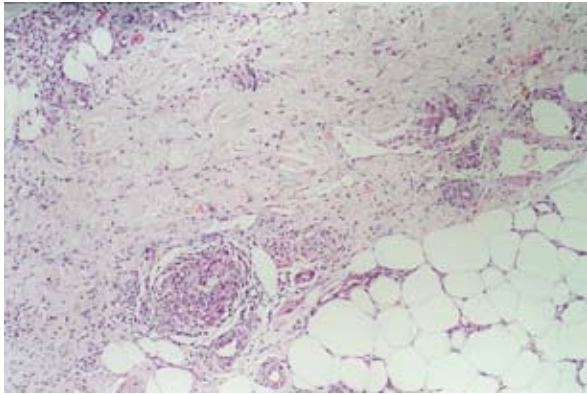


Figure 3. Circumscribed granulomas of epithelioid cells throughout the dermis with extension into the subcutaneous tissue (hematoxylin-eosin stain; original magnification X120).

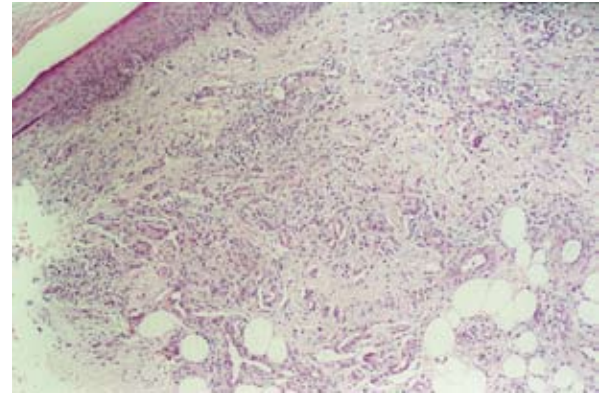


Figure 4. Histology of maculopapular lesions showed discrete, round to oval granulomas in the superficial dermis (hematoxylin-eosin stain; original magnification X80).

causes of EN are medications, sarcoidosis, and inflammatory bowel disease (20). James reports that only two of 170 cases with EN in sarcoidosis showed evidence of epithelioid granulomas on histology (21). This rare histologic feature was seen in our patient.

Cutaneous lesions in the chronic stage tend to be more persistent (2,20). Lupus pernio, angiolupoid, maculopapular, nodular, plaque, scar, ulcerative lesions as well as subcutaneous nodules are examples of specific cutaneous lesions (2,20). Multiple forms of clinically atypical granulomatous lesions have been described: psoriasiform plaques, verrucous and papillomatous lesions, ichthyosiform lesions, lichenoid eruptions, cicatricial alopecia, pustular folliculitis and hypopigmentation in black patients (22-28). Biopsy of these lesions is diagnostic of sarcoidosis. On the other hand, biopsy lesions found in EN are mostly non-specific (3).

In our case, biopsy showed a specific sarcoid lesion. Therefore, we believe that skin biopsy should be performed in all patients with tender, erythematous nodules of lower extremities. Some studies examined the relationship of skin sarcoidosis with systemic manifestation of the disease (3,29,30). Mana *et al.* report that 27 out of 37 patients presented initially with specific cutaneous lesions, 19 had other systemic manifestation concomitantly, whereas 8 who presented with specific cutaneous lesions developed systemic manifestation between 6 months and 3 years later (3). On the other hand, skin lesions may also appear later in the course of the disease (31).

Work-up for systemic manifestations should be undertaken in all patients who have biopsy proven

sarcoidal granulomas of the skin (3). The work-up should include complete history and physical examination, chest radiography, tuberculin skin test, ophthalmologic examination, and analysis of blood and urine calcium levels and serum angiotensin-converting enzyme level (SACE) (3). SACE level is elevated in 60% of patients and is helpful in monitoring disease activity and therapeutic response (3). Computed tomography scanning of the thorax and total body gallium scanning may be helpful in establishing the diagnosis as well as determining the extension of the disease (2,3).

Oral corticosteroids are the mainstay of therapy in sarcoidosis (2). It should be reserved for severe inflammatory disease of the eye, pulmonary and cardiac involvement, central nervous system

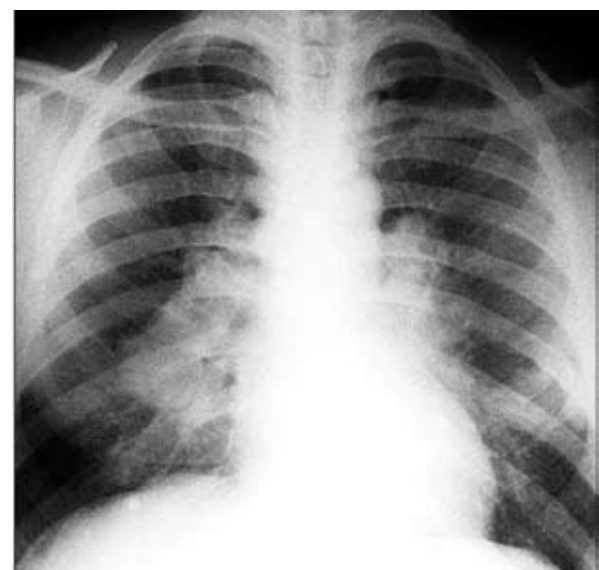

Figure 5. Chest radiography showed bilateral hilar lymphadenopathy.

disease and hepatic involvement (2). Alternatives to corticosteroids are methotrexate, chlorambucil, azathioprine, cyclophosphamide and thalidomide, which can be used in patients refractory to or those who develop adverse effects to systemic corticosteroids (2). Antimalarials may have immunomodulatory effects and are occasionally used to treat cutaneous and pulmonary disease (2). Our patient was treated with 40 mg prednisone *per day* for 6 months, as she had the risk of developing chronic sarcoidosis. Early withdrawal of therapy is coupled with disease relapses, while in rare cases therapy is lifelong (32).

The course of sarcoidosis is variable. In more than 80% of patients with Löfgren's syndrome, the disease resolves spontaneously over two years (1). As a general rule, progressive disease is associated with the presence of specific cutaneous lesions (20). In these patients, pulmonary fibrosis and neurologic involvement are the most common causes of death (2). Follow up care should be frequent for the first two years after diagnosis, but our patient could not present for regular control visits.

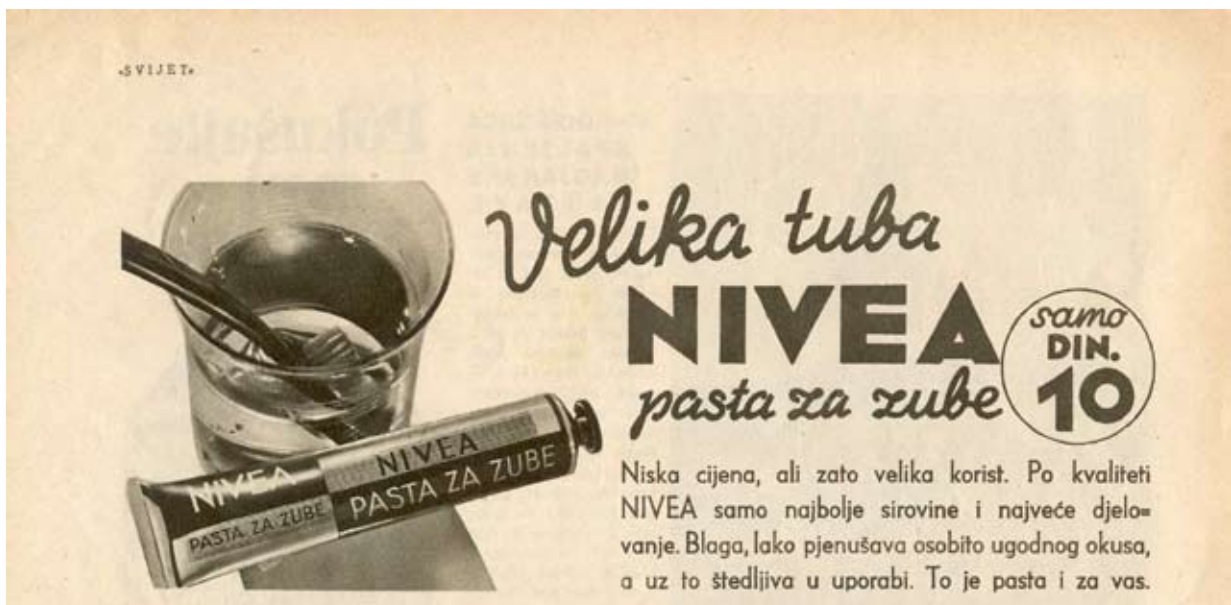CONCLUSION

While EN is the most common nonspecific cutaneous lesion of sarcoidosis, the EN-like eruption in our case was a specific sarcoid lesion. We conclude that patients with EN-like lesions should undergo biopsy. If cutaneous sarcoidal granulomas are found, thorough work-up for other manifestations of sarcoidosis are recommended. Cutaneous sarcoidal granulomas appear to be associated with a poorer prognosis and an increased incidence of pulmonary fibrosis and uveitis. These patients should be followed-up carefully.

References

1. Newman LS, Rose CS, Maier LA. Sarcoidosis. *N Engl J Med* 1997;336:1224-34.
2. Braun-Falco O, Plewig G, Wolff HH, Winkelmann RK. Granulomatous diseases. In: Braun-Falco O, Plewig G, Wolff HH, Winkelmann RK, eds. *Dermatology*. 2nd Completely Revised Edition. Heidelberg, New York: Springer-Verlag; 2000. pp.1380-400.
3. Mana J, Marcoval J, Graells J, Salazar A, Peyri J, Pujol R. Cutaneous involvement in sarcoidosis. *Arch Dermatol* 1997;133:882-8.
4. Callen JP. Sarcoidosis. In: Callen JP, Jorizzo JL, Greer KE, Penneys NS, Piette WW, Zone JJ, eds. *Dermatological Signs of Internal Disease*. Philadelphia, PA: WB Saunders Co;1995. pp. 293-300.
5. Barnard J, Newman LS. Sarcoidosis: immunology, rheumatic involvement, and therapeutics. *Curr Opin Rheumatol* 2001;13:84-91.
6. Podlipsky Gould K, Callen JP. Sarcoidosis. Available at: <http://www.emedicine.com/derm/topic381.htm>
7. Hedfors E, Lindstrom F. HLA-B8/DR3 in sarcoidosis. *Tissue Antigens* 1983;22:200-3.
8. Berlin M, Fogdell-Hahn A, Olerup O, Eklund A, Grunewald J. HLA-DR predicts the prognosis in Scandinavian patients with pulmonary sarcoidosis. *Am J Respir Crit Care Med* 1997;156:1601-5.
9. Mana J, Gomez-Vaquero C, Montero A, Salazar A, Marcoval J, Valverde J *et al.* Löfgren's syndrome revisited: a study of 186 patients. *Am J Med* 1999;107:240-5.
10. Löfgren S, Lundback H. The bilateral hilar lymphoma syndrome: a study of the relation to age and sex in 212 cases. *Acta Med Scand* 1952;142:259-73.
11. Löfgren S. Primary pulmonary sarcoidosis. I. Early signs and symptoms. *Acta Med Scand* 1953;45:424-31.
12. Hanno R, Needelman A, Eiferman RA, Callen JP. Cutaneous sarcoidal granulomas and the development of systemic sarcoidosis. *Arch Dermatol* 1981;117:203-7.
13. Okamoto H, Mizuno K, Imamura S, Nagai S, Izumi T. Erythema nodosum-like eruption in sarcoidosis. *Clin Exp Dermatol* 1994;19: 507-10.
14. Psychos DN, Voulgari PV, Skopouli FN, Drosos AA, Moutsopoulos HM. Erythema nodosum: the underlying conditions. *Clin Rheumatol* 2000;19:212-6.
15. Cribier B, Caille A, Heid E, Grosshans E. Erythema nodosum and associated diseases. A study of 129 cases. *Int J Dermatol* 1998;37:667-72.
16. Rosenthal J, Brandt KD, Wheat LJ, Slama TG. Rheumatologic manifestations of histoplasmosis in the recent Indianapolis epidemic. *Arthritis Rheum* 1983;26:1065-70.
17. Maggiore G, Grifeo S, Marzani MD. Erythema nodosum and hepatitis B virus infection. *Am J Dermatol* 1983;9:602-3.
18. Klippel JH, Weyand CM, Wortmann RL. Pri-

- mer on the rheumatic diseases. 11th edition. Arthritis Foundation. 1997. pp.365-6.
19. Bang D, Homma J, Saito T, Nakagawa S, Ueki H, Lee S. The pathogenesis of vascular changes in erythema nodosum like lesions of Behçet's syndrome: an electron microscopic study. *Hum Pathol* 1987;18:1172-9.
 20. Braverman IM. Sarcoidosis. In: Freedberg IM, Eisen AZ, Wolff K, Austen KF, Goldsmith LA, Katz SI. *Fitzpatrick's dermatology in general medicine*. 6th edition. New York: McGraw-Hill; 2003. pp.1777-83.
 21. James DG. Dermatologic aspects of sarcoidosis. *Q J Med* 1959;28:109-24.
 22. Kerdel FA, Moschella SL. Sarcoidosis: an updated review. *J Am Acad Dermatol* 1984;11:1-19.
 23. Shmunis E, Lantis RL, Hurley HJ. Verrucous sarcoidosis. *Arch Dermatol* 1970;102:665-9.
 24. Banse-Kupin L, Pelachyk JM. Ichthyosiform sarcoidosis: report of two cases and a review of the literature. *J Am Acad Dermatol* 1987;17:616-20.
 25. Gange RW, Smith NP, Fox ED. Eruptive cutaneous sarcoidosis of unusual type. *Clin Exp Dermatol* 1978;3:299-306.
 26. Golitz LE, Shapiro L, Hurwitz E, Stritzler R. Cicatricial alopecia of sarcoidosis. *Arch Dermatol* 1973;107:758-60.
 27. Elgart ML. Cutaneous sarcoidosis: definitions and types of lesions. *Clin Dermatol* 1986;4:35-45.
 28. Clayton R, Breathnach A, Martin B, Feiweil M. Hypopigmented sarcoidosis in the negro. *Br J Dermatol* 1970;96:119-25.
 29. Callen JP. Relationship of cutaneous sarcoidosis to systemic disease. *Clin Dermatol* 1986;4:46-53.
 30. Ahmed I, Harshad SR. Subcutaneous sarcoidosis: is it specific subset of cutaneous sarcoidosis frequently associated with systemic disease? *J Am Acad Dermatol* 2006;54:55-60.
 31. Hanno R, Needelman A, Eiferman RA, Callen JP. Cutaneous sarcoid granulomas and the development of systemic sarcoidosis. *Arch Dermatol* 1981;117:203-7.
 32. Golubičić Peroš T. Sarkoidoza. In: Vrhovac B, Francetić I, Jakšić B, Labar B, Vucelić B. *Inter-na medicina*. Zagreb: Naknada Ljevak; 2003. pp.1402-7.



For your teeth - use Nivea toothpaste; year 1936.
(from the collection of Mr. Zlatko Puntijar)