

# Porphyria Cutanea Tarda as the Most Common Porphyria

**Vedrana Bulat, Liborija Lugović, Mirna Šitum, Marija Buljan, Lada Bradić<sup>1</sup>**

University Department of Dermatology and Venereology, Sestre milosrdnice University Hospital; <sup>1</sup>Department of Pathophysiology, Zagreb University Hospital Center, Zagreb, Croatia

## Corresponding author:

Vedrana Bulat, MD  
University Department of Dermatology  
and Venereology  
Sestre milosrdnice University Hospital  
Vinogradska cesta 29  
HR-10000 Zagreb  
Croatia  
[veckybulat@inet.hr](mailto:veckybulat@inet.hr)

Received: June 3, 2007

Accepted: September 20, 2007

**SUMMARY** Porphyrias are an uncommon, heterogeneous group of metabolic diseases caused by inherited or acquired deficiency of specific enzymes in the heme biosynthetic pathway resulting in an excess of porphyrins (red-brown pigments) and their precursors. Accumulation of heme precursors, such as porphyrinogens that are spontaneously oxidized to porphyrins, is responsible for various clinical features. Porphyrias are classified into three groups: erythropoietic, hepatic and hepatoerythropoietic, depending on the primary organ affected. Porphyria cutanea tarda (PCT) is the most common porphyria, characterized by defective uroporphyrinogen III decarboxylase enzyme. There are three types of PCT with typical skin manifestations. Patients with PCT present with skin fragility, erosions, vesicles, bullae, and milia in sun-exposed areas of the skin, sometimes periorbital mottled hyperpigmentation and hypertrichosis, sclerodermoid changes and ulceration. We present the most common pathogenetic, clinical, diagnostic, and therapeutic features of PCT and other types of porphyria.

**KEY WORDS:** porphyria, porphyria cutanea tarda, porphyrin

## INTRODUCTION

Porphyrias are a heterogeneous group of metabolic diseases caused by inherited or acquired deficiency of specific enzymes in the heme biosynthetic pathway resulting in an excess of porphyrins and their precursors (porphyrin is a red-brown pigment) (1). Porphyrias are classified into three groups: erythropoietic, hepatic and hepatoerythropoietic, depending on the primary organ affected (Table 1) (1,2).

The accumulation of heme precursors in porphyrias, including porphyrinogens that are spon-

taneously oxidized to their respective porphyrins, is responsible for various clinical features (1). Two main types of clinical manifestation include life-threatening attacks of acute porphyria and chronic skin photosensitization (3). Acute porphyrias include acute intermittent porphyria, variegate porphyria, hereditary coproporphyria, and  $\delta$ -aminolevulinic acid (ALA) dehydratase deficiency, while chronic porphyrias include porphyria cutanea tarda (PCT), erythropoietic porphyria and erythropoietic protoporphyria (3).

**Table 1.** Clinical features of porphyrias (modified according to Habif (3))

Type of porphyria	Hereditly	Enzyme deficiency	Age at onset	Cutaneous manifestations	Extracutaneous manifestations	Urine	Feces	Erythrocytes	
Erythropoietic	AR	Uroporphyrinogen III synthase	Infancy	Chronic Bullous lesions, severe scarring	Red teeth, hemolytic anemia	Uro I copro I	Copro I	Uro I stable fluorescence	
Erythropoietic	AD	Ferrochelatase	Childhood	Chronic Burning edema thickening rarely blisters	Rarely fatal liver disease, gall stones	negative	Protoporphyrin continuously	Protoporphyrin transient fluorescence	
Hepatic and erythropoietic	AR	Uroporphyrinogen decarboxylase	Infancy	Chronic Bullous lesions, severe scarring thickening	Decreased liver function	Uro I Uro III	Copro I Copro III ISO coproporphyrin	Protoporphyrin	
Hepatic	AD	Hydroxymethylbilane synthase	Adolescence	Acute None	Abdominal pain, neuropathy, psychosis	ALA and PBG continuously	Negative	Negative	
									Acute intermittent porphyria (AIP)
									Variegate porphyria (VP)
Porphyria cutanea tarda (PCT)	Sporadic (80%) AD (20%)	Uroporphyrinogen III decarboxylase	Middle age	Chronic Bullous lesions, scarring thickening scleroderma-like features	Decreased liver function, siderosis	Uro I > uro III continuously continuous fluorescence	ISO coproporphyrin > copro	Negative	
Hereditary coproporphyrin (HCP)	AD	Coproporphyrinogen oxidase	Young adulthood	Acute Same as PCT	Same as AIP	Copro, ALA and PBG during attacks	Copro III continuously	Negative	

## BIOSYNTHETIC PATHWAY OF HEME

Heme is synthesized in all nucleated cells, but the majority is formed in hepatocytes and erythroblasts in bone marrow. Heme is necessary for the transport and metabolism of oxygen (4). The biosynthetic pathway of heme starts in mitochondria when the amino acid glycine (which is found in all cells) and succinyl coenzyme A (derived from Krebs cycle) are condensed to form ALA (Fig. 1) (5). This reaction is catalyzed by 5-ALA synthase and is the rate limiting step in the biosynthetic pathway of heme. The activity of the 5-ALA synthase enzyme can be inhibited by heme, glucose and hematin. The next stage of the pathway occurs in the cytosol when two molecules of ALA are condensed to form porphobilinogen, a molecule containing a monopyrrole ring. The reaction is catalyzed by 5-ALA dehydratase. Then four porphobilinogen molecules are combined to form a linear tetrapyrrole, hydroxymethylbilane by hydroxymethylbilane synthase, and then the pathway splits (5). The uroporphyrinogen-III cosynthetase enzyme cyclizes linear hydroxymethylbilane to uroporphyrinogen III, while in the absence of the enzyme uroporphyrinogen I is formed. Uroporphyrinogen III is then converted by uroporphyrinogen III decarboxylase (UROD) to its respective coproporphyrinogen III, while uroporphyrinogen I is spontaneously converted to coproporphyrinogen I. Only coproporphyrinogen III participates further in heme synthesis, being oxidized by coproporphyrinogen oxidase to protoporphyrinogen IX, which is returned to the mitochondria. It is then oxidized by protoporphyrinogen oxidase to protoporphyrin IX. At the end of heme synthesis iron is added by ferrochelatase to protoporphyrin IX to make heme (5). Different forms of porphyrias are caused by enzyme deficiencies, starting from 5-ALA synthase and ending with ferrochelatase, which are almost all inherited in an autosomal dominant pattern (2,5). Low clinical penetrance of all the autosomal dominant porphyrias is an important feature (4). The enzyme deficiencies are permanent, but clinical symptoms of porphyrias are intermittent and usually do not present until after puberty, especially in PCT (the most common porphyria), acute intermittent porphyria and variegate porphyria (5).


For the disorder to become clinically manifest, an additional decrease in enzyme activity is required, which may result from direct, organ specific inhibition of the enzyme, e.g., hepatocellular carcinoma, or from a mutation in the genes that affects transcription and/or translation of enzymes of heme synthesis. These effects may be caused

by mutation in the genes other than those directly involved in heme synthesis, e.g., mutation in the hemochromatosis gene. Clinical manifestation is triggered by medications, hormones (particularly progesterone), fasting and medical illness.

Induction of ALA synthetase increases hepatic heme synthesis and enzyme deficiencies become apparent as heme precursors accumulate. If heme breakdown is increasing, the negative feedback loop causes direct induction of ALA synthetase and clinical manifestations of porphyrias become apparent (5). Heme is the prosthetic group of proteins such as hemoglobin, myoglobin, catalase, peroxidase and cytochrome P 450. Cytochrome P 450 is heme oxygenase (about 40% of the hepatic heme is incorporated into enzyme), which metabolizes a significant number of commonly used drugs. Medications cause direct induction of this enzyme, increasing its production, then lead to heme reduction (heme is incorporated into cytochrome P 450) and the negative feedback loop causes induction of ALA synthetase. The enzymes involving heme synthesis are defective and heme precursors accumulate. Toxins including alcohol, metals (iron), hexachlorobenzene and many other chemical substances are metabolized in the liver by cytochrome P 450 and can cause clinical manifestation of the most common cutaneous porphyria, PCT. Also, hepatitis C virus (especially in HIV-positive patients) can cause a mutation in the genes that affects directly transcription and/or translation of the enzymes of heme synthesis (5,6).

Porphobilinogens are oxidized to uroporphyrinogens, coproporphyrins and protoporphyrins, and their solubility changes as they are metabolized (5). Therefore, ALA, porphobilinogen and uroporphyrinogen are hydrophilic and excreted in the urine, while coproporphyrin and protoporphyrin are lipophilic and are found in the stool.

Porphyryns (except for ALA and porphobilinogen) absorb the lower range of visible light in the Soret band (400-410 nm), and after exposure to visible light they show red fluorescence. This absorbed light energy is then transferred to cellular structures of hepatocytes and erythroblasts, and molecular oxygen is transformed into singlet oxygen. Free radicals and singlet oxygen peroxide phospholipids of the lysosomal biomembranes. Potent degrading lysosomal enzymes, including proteases, lipases and glycosidases lead to tissue damage. After heme precursors in erythrocytes have absorbed enough energy, photohemolysis occurs. Peripheral erythrocytes are no



**Figure 1.** Biosynthesis of heme, with sites of enzyme deficiencies in porphyria; adapted from: Braun-Falco O, Plewig G, Wolff HH, Burgdorf WHC, eds. The porphyrias. In: Braun-Falco O, Plewig G, Wolff HH, Burgdorf WHC, eds. Dermatology. 2nd completely revised edition. Berlin: Springer-Verlag; 2000. pp.1309-26.

longer responsive to blood loss and hypoxia. An elevated reticulocyte count indicates an increased erythrocyte production compensating for the ongoing loss of erythrocytes (photohemolysis).

The most phototoxic porphyrin is protoporphyrin, which produces free radicals and singlet oxygen that damage a variety of cellular structures. Photoprotection from both UVA and the lower range of visible light is necessary in porphyria patients due to the peak activation of heme precursors in the Soret band (5).

## CLASSIFICATION AND TYPES OF PORPHYRIA

Traditionally, porphyrias have been divided into erythropoietic and hepatic, while according to some authors porphyrias are classified as erythropoietic, hepatic, and hepatoerythropoietic (Table 1) (1,5). Only one porphyria is purely erythropoietic, i.e. congenital erythropoietic porphyria, which is an autosomal recessive variant, suggesting that all reticulocytes have to miss the necessary enzyme in order to manifest the disease. In

erythropoietic protoporphyria, both red blood cells and hepatocytes have enzyme deficiencies, while in other porphyrias the main problem is in hepatocytes (7-10).

Porphyrias have been classified by clinicians as acute and chronic. Acute porphyrias include acute intermittent porphyria, variegate porphyria, hereditary coproporphyria, and ALA dehydratase deficiency, while chronic porphyrias include PCT, erythropoietic porphyria and erythropoietic protoporphyria (3,11-13). Acute porphyrias are caused by deficiency of the hepatic heme synthesis enzymes, with the possible emergency admission for sudden attacks of abdominal pain, or may cause neuropsychiatric symptoms (2,5).

There is also secondary porphyria caused by acute lead poisoning. Lead blocks the action of the ALA dehydratase enzyme and massive amounts of ALA accumulate in the urine, where they serve as markers of lead intoxication, leading to symptoms of acute intermittent porphyria. Lead also causes increased fragility and decreased red blood cell survival due to direct effect on the red cell membrane. Patients with chronic renal failure on dialysis sometimes develop clinical manifestations that are indistinguishable from the cutaneous lesions seen in PCT, and are associated with increased carboxylated porphyrins, mainly uroporphyrins, that accumulate in serum. Identifying these uncommon porphyrins requires a highly specialized laboratory (5).

All types of porphyria show excess of porphyrin metabolites in the blood, urine or feces, and in various tissues such as skin and liver. Certain porphyrin metabolites (porphyrinogens) accumulate in the skin and are auto-oxidized to become porphyrins. Porphyrins absorb UVA light in Soret band range, and these excited porphyrins generate peroxides that cause blisters seen in PCT and variegate porphyria (3).

Acute intermittent porphyria (AIP) is caused by deficiency of the hydroxymethylbilane synthase enzyme that combines four porphobilinogen molecules to form linear tetrapyrrole (Table 1). This type of porphyria is characterized by increased concentrations of 5-ALA and PBG in plasma and urine (2). Hereditary coproporphyria is acute porphyria due to the defect in the conversion of coproporphyrinogen III to protoporphyrinogen III (2). Variegate porphyria is acute porphyria characterized by clinical manifestations that are indistinguishable from the cutaneous lesions seen in AIP. PCT and other porphyrias present clinically

as skin sensitivity to light (photosensitivity), with possible disfiguration and scarring (2).

The skin lesions in PCT, variegate porphyria, hereditary coproporphyria, and congenital erythropoietic porphyria manifest with mechanical fragility, subepidermal bullae, hypertrichosis, and pigmentation (3). Protoporphyrin is the predominant porphyrin in patients with erythropoietic protoporphyria. Protoporphyrin and Soret band radiation cause the release of mast cell mediators causing erythema and edema without skin lesions seen in other types of porphyria.

Laboratory diagnosis of porphyrias includes measurements of both relevant enzymes and metabolites in plasma, urine, feces and erythrocytes. The most important test for the diagnosis of acute porphyrias is the measurement of PBG in urine and plasma (2). Then ALA accumulates in the urine, where it serves as a marker of lead intoxication.

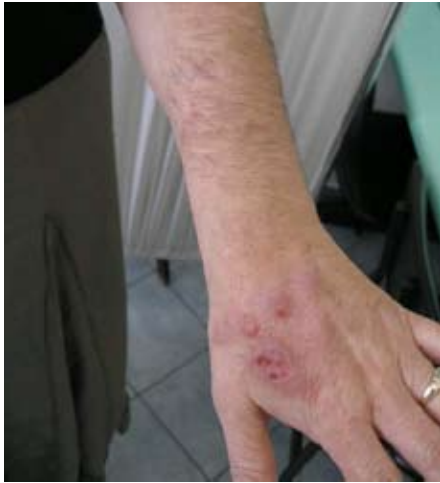It is also important to analyze urine (ALA, porphobilinogen and total urine porphyrins, measured by ion-exchange resins, chromatographic photometric techniques, high-pressure liquid chromatography) and erythrocytes (erythrocyte fluorescence determine erythropoietic protoporphyria and congenital erythropoietic porphyria), or to measure porphobilinogen deaminase (high-pressure liquid chromatography is needed to separate various porphyrin products in the urine) and feces (high-pressure liquid chromatography)(5).

## PORPHYRIA CUTANEA TARDA

Porphyria cutanea tarda (PCT) (Günther 1922; Waldenström 1937; Ippen 1959) is the most common porphyria, characterized by defective uroporphyrinogen III decarboxylase (UROD) enzyme and includes three types of PCT with typical skin manifestations (1,5). Patients present with skin fragility, erosions, vesicles, bullae, and milia in sun-exposed areas of the skin, sometimes periorbital mottled hyperpigmentation and hypertrichosis, sclerodermoid changes and ulceration (Fig. 2). It is characterized by increased uroporphyrins such as 8-,7-, 6-, 5-, and 4-carboxyl porphyrins in urine and isocoproporphyrin in stool (1,14-16).

There are three types of PCT: two types of hereditary PCT (types II and III) and acquired PCT (type I). Acquired PCT (PCT type I) is the most common type of PCT (80% of patients with PCT) with negative family history. The disease is caused by mutation in the genes for the hepatic enzyme UROD, where the hepatic enzyme activity is





**Figure 2.** Classic clinical presentation of a patient with porphyria cutanea tarda.

reduced by 50%, although the structural protein is present. In extrahepatic locations, the enzyme structure and function are normal (17-19).

Family history is positive in hereditary PCT types II and III, and they are inherited in an autosomal dominant pattern. Hereditary PCT type II is caused by a mutation in the genes that affects directly transcription and/or translation of the hepatic and erythrocyte enzyme UROD, while hereditary PCT type III is caused by mutation only in the genes of the hepatic enzyme UROD; the enzyme level is reduced to about 50% of normal in all tissues (1,5).

In the majority of patients, a mutation in the UROD gene is not enough to cause clinical manifestations of PCT (4). However, in contrast to the autosomal dominant acute porphyrias (with the same enzyme activities, and symptoms present or not); in familial PCT the hepatic enzyme activity is decreased to below half-normal in symptomatic individuals.

The additional decrease in hepatic UROD activity results from reversible inactivation by an iron-dependent process, probably initiated by a number of possible triggers such as alcohol, hepatotropic viruses, iron intake, oral estrogens and genetic factors that may influence susceptibility to these causes (4).

There is a strong genetic association of co-inheritance of UROD and hemochromatosis (HFE) gene mutations, resulting in the earlier onset of symptoms. Other candidate predisposing genes include ALAS 1 and cytochrome P 450 (4,10,11). However, there is similar hepatic iron content in PCT patients with and without HFE mutations, and clearly involving other factors related to iron metabolism.

It should also be noted that PCT patients have an increased risk of clinical relapse and hepatocellular carcinoma, particularly those with long-standing untreated disease, and should be kept under surveillance.

Although precise data on the epidemiology of PCT are lacking (more than a single enzyme defect is involved), it was observed that in average dermatological practice, PCT accounts for 80%-90% of porphyria patients with an incidence of 1:25 000 (5). The male/female ratio has been reported to be 1:1 in both inherited types of PCT, but in the acquired form men are by far more frequently affected.

### **Etiopathogenesis of PCT**

Defective UROD activity results in the characteristic porphyrin profile of PCT. In familial PCT, there are several genomic DNA mutations resulting in defective UROD (indicating that it is a genetically heterogeneous entity) (1).

The porphyrins absorb Soret band radiation, generating reactive oxygen species. Free radicals and singlet oxygen peroxide the phospholipids of the lysosomal biomembranes. Potent degrading lysosomal enzymes, including proteases, lipases and glycosidases, lead to tissue damage and release of inflammatory mediators, neutrophils, and the activation of the complement system. The lack of direct effect of uroporphyrins (the predominant porphyrin in patients with PCT) on mast cells explain the manifestations of PCT, without erythema and edema. It has also been shown that uroporphyrins stimulate collagen synthesis by fibroblasts *in vitro*, which may explain the sclerodermoid skin lesions occurring both in sun-exposed and sun-protected areas of the skin in porphyria patients (1,11).

The hereditary types of PCT tend to have a somewhat earlier onset in the first decades of life, while acquired cases of PCT typically appear after the age of 30.

In hereditary and acquired forms of PCT, about 20% of patients, the family history of PCT is positive. It has been confirmed that both forms were triggered by alcohol abuse (60%), estrogens (25%) and liver disease (20%) (1). Association of PCT with human immunodeficiency virus (HIV) infection and hepatitis C infection was confirmed (1,14).

Medications and hepatomas are responsible for chronic reaction in 5% of patients with PCT, while in about 10% of patients, the cause is unknown (5). Medications cause direct induction of

the cytochrome P 450 enzyme in hepatocytes. Cytochrome P 450 is heme oxygenase (about 40% of the hepatic heme is incorporated into the enzyme), which metabolizes a significant number of commonly used drugs. Thus, the medications in the hepatic porphyria lists can be employed for routine use in PCT patients, but it is wise to avoid any potentially hepatotoxic medications in PCT patients. High-dose chloroquine and hydroxychloroquine therapy causes acute reactions, but severe reactions are rare. Besides medications, there are other triggering agents in PCT: alcohol (the major risk factor, acts at many levels of heme synthesis); estrogens (oral contraceptives, replacement estrogens and estrogens given to males with prostate cancer); iron (elevated hepatic iron stores, often to twice normal), hexachlorobenzene (e.g., PCT-like illness with chronic PCT changes, arthritis, neurologic problems and elevated fecal and urine porphyrins in a region of southeastern Turkey where wheat seeds treated with hexachlorobenzene were used for food), and dioxin (5,8).

### Clinical features of PCT

Genetic predisposition and exposure to selected exogenous agents contribute to the cutaneous manifestations of PCT (1). The disorder can start at any age in the autosomally dominant inherited form (types II and III), while the acquired form (type I) usually begins in adulthood. Several exogenous agents such as alcohol, estrogen, iron overload and polychlorinated aromatic hydrocarbons precipitate the onset of PCT by contributing to excessive hepatic porphyrinogenesis. The most common clinical presentation of PCT is skin fragility, manifested as erosions, vesicles or bullae in sun-exposed areas, usually on the dorsa of hands and forearms (Fig. 2). Another typical aspect is increased skin fragility, and thus the slightest trauma will damage the sun-exposed skin and the wound healing is delayed. Bullae and erosions heal with hyper- and hypopigmented atrophic scars and milia. Other cutaneous changes include facial hypertrichosis along the temples and cheeks, periorbital mottled hyperpigmentation, sclerodermoid lesions on both sun-exposed and sun-protected areas of the neck, face and chest, scarring alopecia; dystrophic calcification with ulceration, and rarely onycholysis (1,5).

There often are no sensations of discomfort following sun exposure (such as burning and stinging), and no gastrointestinal and neuropsychiatric symptoms.

Bullous lesions in PCT appear as noninflamed subepidermal blisters in sun-exposed skin, commonly on the back of the hand, cheeks or temples, ranging in size from a few millimeters to several centimeters, and are quite stable and painless (5,15). The blisters rupture and may produce atrophic scars, hypo- and hyperpigmentation and milia, producing a polymorphous clinical picture, but patients almost never associate blisters with acute sunlight exposure and often deny photosensitivity (Fig. 2).

Other reversible lesions include hypertrichosis as a common feature, often involving the temples, connecting the eyebrows to the hairline and cheeks. Facial hyperpigmentation resembling melasma, and heliotrope discoloration are also manifestations of PCT (5,15).

PCT patients often show chronic actinic damage, with possible Favre-Racouchot disease, diffuse actinic elastosis, deep furrows and wrinkles. The presence of marked actinic damage in a young patient should suggest the possibility of PCT (Birda sign) (5,15).

Sclerodermoid lesions (pseudoscleroderma) are also seen in porphyria patients, mostly on the skin of the lateral aspects of the face and neck, as firm and indurated skin, with small erosions, hemorrhagic areas, crusts or varioliform scars (5).

A number of patients have been reported with both PCT and lupus erythematosus, which is clinically important, as high-dose chloroquine therapy used in lupus erythematosus can cause acute reactions in PCT patients (5).

### Laboratory findings in PCT

Plasma porphyrin determination is a good screening test for all types of porphyria with cutaneous manifestations. Diagnosis should only be made after evaluation of the complete porphyrin profile in plasma, erythrocytes, urine, and feces (1).

Porphyrin profiles are essential in differentiating PCT from two other less common types of porphyria, namely variegate porphyria and hereditary coproporphyria (which can be clinically indistinguishable from PCT) (Table 1) (1). In variegate porphyria, the predominant porphyrin is coproporphyrin, while ALA and porphobilinogen are increased in urine during attacks (1).

Porphyrins can be identified by serum analysis, which is of particular importance in renal dialysis patients, but urine analysis is crucial. The most appropriate test is 24-h urine evaluation;

screening tests on spot urines are unreliable (5). There is a massive increase in all urine porphyrins but coproporphyrins usually predominate. The urine may be discolored. Feces analysis is not mandatory but also shows elevated levels of porphyrins and the presence of isocoporphyrins is taken as diagnostic.

There are several quantitative and qualitative measurement tests of porphyrins, including fluorescence under Wood's light (invisible long-wave ultraviolet radiation at 360 nm), which is a non-specific finding but serves as a screening test in PCT. If the level of porphyrins is too low, false-negative result can be obtained. The 24-hour urine test is a quantitative measurement of porphyrins. If porphyrins are present, the urine may be amber-red or burgundy. In most forms of porphyria, increased levels of porphyrins are found in the urine. The urine in PCT shows elevated level of uroporphyrins (isomers I>III) and 7-carboxyl porphyrin (isomers III>I), and lesser elevations of 6-, 5-, and 4-carboxyl porphyrins. Urine tests are not as accurate as fluorescent spectrophotometric analysis of plasma. A sharp emission peak at 619 nm confirms PCT. The test can also be done on a fresh stool specimen. In PCT the predominant stool porphyrin precursor is isomer III of isocoporphyrin, with lesser amounts of uroporphyrin, coproporphyrin, and 7-carboxyl porphyrin (1,15).

The analysis of erythrocytes for determination of UROD levels is used to separate the acquired form (normal levels) from the familial form (50% reduction).

Other laboratory tests that should be performed include complete blood count (to assess hemoglobin and hematocrit levels prior to therapy), serum iron, ferritin and total iron binding capacity (to assess iron stores, which are increased in more than 30% of patients), liver enzymes and hepatitis virus (including hepatitis C) screen and ANA screening (1,14). In patients who have risk factors for HIV infection, HIV serology should be considered.

Biopsy of a vesicle shows a characteristic sub-epidermal blister, with intact dermal papillae rising irregularly from the floor of the bullae into the cavity and only sparse inflammatory cells in the dermis. Thickened capillary walls in the superficial dermis are best observed in sections stained with periodic acid Schiff (PAS) stain and represent multiple layering of basal lamina, as detected by electron microscopy (1). Biopsy of a vesicle, which should include the edge of the lesion, is indicated to differentiate PCT from other blistering diseases.

It is important to think about possible histological features of associated lupus erythematosus. The clinical picture of scleroderoid lesions may appear as scleroderma, while histological features such as separation at the epidermal-dermal junction and amorphous perivascular material suggest PCT. In addition, there is usually actinic elastosis or other elastic fiber changes, while in scleroderma the elastic fibers are normal.

The differential diagnosis of PCT includes drug-induced pseudoporphyria, caused by medications such as furosemide, nonsteroid anti-inflammatory drugs; nalidixic acid and tetracycline, clinically indistinguishable from PCT, but porphyrin studies are negative. Bullous lesions in patients with renal dialysis may be caused by the increased serum porphyrin. Epidermolysis bullosa acquisita may look like PCT and can be diagnosed by the presence of antibodies to type VII collagen. Excessive use of tanning beds cause blisters and increased skin fragility independent of burning (5).

Direct immunofluorescence shows deposition of immunoglobulins and C3 at the basement membrane zone and in the walls of blood vessels in the superficial dermis (1). Indirect immunofluorescent examination is negative.

The prognosis of PCT is good if the patient does not have permanent liver damage and avoids future hepatic insults. A small percentage of patients either have a hepatoma or may develop one. Some clinicians consider PCT a paraneoplastic marker and close monitoring is required (5).

### Therapy of PCT

It is important that complete elimination of alcohol, estrogen, iron, and environmental toxins results in clinical clearing of reversible skin lesions of PCT in 2 months to 2 years (1). Protection from both ultraviolet and visible light is required, and use of physical sun-blockers such as micronized titanium dioxide is recommended, while chemical sunscreens do not effectively absorb the Soret band.

Phlebotomy is the treatment of choice; 250-500 mL of blood should be removed weekly or biweekly until hemoglobin drops to 10 to 11 g/dL or until serum iron drops to 50 to 60 µg/dL, but clinical improvement is not noticeable until 3 to 6 months and the time necessary for remission ranges from months to years (7,20,21).

Oral antimalarial agents are quite effective and some physicians use them as first-line therapy. For example, chloroquine phosphate base, 125 mg



twice weekly for 8-18 months in very low dosages may be given. Thereat, chloroquine forms a water-soluble complex with porphyrins and uroporphyrins are rapidly eliminated by the urine. It also causes a minor hepatotoxic reaction with the release of porphyrins, which are excreted in the urine. They can also be useful in patients who are anemic, in HIV positive patients or in those that cannot tolerate phlebotomy for other reasons. Chloroquine is usually used in very low dosages, as at higher dosages severe hepatotoxic response may occur (5). During this therapy, liver function must be monitored carefully, especially at the beginning of therapy. Ocular toxicity is possible but unlikely at such low dosages. Some clinicians prefer to combine chloroquine 125 mg twice weekly with more modest phlebotomies, usually 250 mL every other week. It is important to measure plasma uroporphyrin in order to monitor the progression of PCT. Therapy should be continued until plasma uroporphyrin drops below 10 mmol/L.

Other less commonly used treatments include cholestyramine, iron chelators, high-dose hydroxychloroquine, and erythropoietin (1,20,22).

The iron load is nowhere near as high as in hemochromatosis, so usually there is no use for the aggressive regimens described for this disease (5). The hemoglobin or hematocrit levels should not be driven below 12 g/dL or 36%, respectively. Serum iron and urine porphyrin levels drop slowly as the clinical findings improve. Blistering and skin fragility improve first, often after several months, hypertrichosis and sclerodermoid changes may get better over years, while atrophic scars and white milia are permanent skin lesions.

Other approaches include the use of iron-binding chelating agents, both orally and intravenously, and combining erythropoietin with phlebotomy in anemic patients. Local therapy in porphyria patients is usually not needed, except for routine wound care for eroded blisters. Sunscreens may reduce the chronic actinic changes but seem to help little against blistering (5).

## References

1. Lim HW. The porphyrias. In: Sams WM, Lynch PJ, editors. Principles and practice of dermatology. 2<sup>nd</sup> edition. New York: Churchill Livingstone; 1996. pp. 731-8.
2. Baynes J, Dominiczak MH. Special liver function. In: Baynes J, Dominiczak MH, editors. Medical biochemistry. 4<sup>th</sup> edition. Edinburgh: Elsevier Limited; 2004. p. 347.
3. Habif TP. Porphyria cutanea tarda. In: Habif TP, editor. Skin disease diagnosis and treatment. 2<sup>nd</sup> edition. Philadelphia: Elsevier Mosby; 2005. pp. 368-71.
4. Badminton MN, Elder GH. Molecular mechanisms of dominant expression in porphyria. *J Inher Metab Dis* 2005;28:277-86.
5. Braun-Falco O, Plewig G, Wolff HH, Burgdorf WHC, editors. The porphyrias. In: Braun-Falco O, Plewig G, Wolff HH, Burgdorf WHC, editors. Dermatology. 2<sup>nd</sup> completely revised edition. Berlin: Springer-Verlag; 2000. pp. 1309-26.
6. Herrero C, Vicente A, Bruguera M, Ercilla MG, Barrera JM, Vidal J *et al.* Is hepatitis C infection a trigger of porphyria cutanea tarda? *Lancet* 1993;341:788-9.
7. Bickers DR, Poh-Fitzpatrick MB. Günther's disease and the changing complexion of human porphyria. *Photodermatology* 1986;3:315-6.
8. Bloomer JR. The liver in protoporphyria. *Hepatology* 1988;8:402-7.
9. Eales L, Day RS, Blekkenhorst GH. The clinical and biochemical features of variegate porphyria: an analysis of 300 case studies at Groote Schuur Hospital, Cape Town. *Int J Biochem* 1980;12:837-53.
10. Lim HW. Pathophysiology of cutaneous lesions in porphyrias. *Semin Hematol* 1989;26:114-9.
11. Lim HW, Gigli I, Wasserman SI. Differential effects of protoporphyrin and uroporphyrin on murine mast cells. *J Invest Dermatol* 1987;88:282-7.
12. Toback AC, Sassa S, Poh-Fitzpatrick MB, Schechter J, Zaider E. Hepatoerythropoietic porphyria: clinical, biochemical, and enzymatic studies in a three-generation family lineage. *N Engl J Med* 1987;316:645-50.
13. Nakahashi Y, Fujita H, Taketani S, Ishida N, Kappas A, Sassa S. The molecular defect of ferrochelatase in a patient with erythropoietic protoporphyria. *Proc Natl Acad Sci USA* 1992;89:281-5.
14. Cohen P. Porphyria cutanea tarda in human immunodeficiency virus-seropositive men: case report and literature review. *J AIDS* 1991;4:1112-7.
15. Grossman ME, Bickers DR, Poh-Fitzpatrick MB, Deleo VA, Harber LC. Porphyria cutanea tarda: clinical features and laboratory findings in 40 patients. *Am J Med* 1979;67:277-86.

16. Held JL, Sassa S, Kappas A, Harber LC. Erythrocyte uroporphyrinogen decarboxylase activity in porphyria cutanea tarda: a study of 40 consecutive patients. *J Invest Dermatol* 1989;93:332-4.
17. Garey JR, Hansen JL, Harrison LM, Kennedy JB, Kushner JP. A point mutation in the coding region of uroporphyrinogen decarboxylase associated with familial porphyria cutanea tarda. *Blood* 1989;73:892-5.
18. Garey JR, Harrison LM, Franklin KF, Metcalf KM, Radisky ES, Kushner JP. Uroporphyrinogen decarboxylase: a splice site mutation causes the deletion of exon 6 in multiple families with porphyria cutanea tarda. *J Clin Invest* 1990;86:1416-22.
19. Garey JR, Hansen JL, Harrison LM, Kennedy JB, Kushner JP. A point mutation in the coding region of uroporphyrinogen decarboxylase associated with familial porphyria cutanea tarda. *Blood* 1989;73:892-5.
20. Cainelli T, Di Padova C, Marchesi L, Gori G, Rovagnati P, Podenzani SA *et al.* Hydroxychloroquine *versus* phlebotomy in the treatment of porphyria cutanea tarda. *Br J Dermatol* 1983;108:593-600.
21. Ippen H. Treatment of porphyria cutanea tarda by phlebotomy. *Semin Hematol* 1977;14:253-62.
22. Anderson KE, Goeber DE, Carson RW, Lee SM, Stead RB. Erythropoietin for the treatment of porphyria cutanea tarda in a patient on a long-term hemodialysis. *N Engl J Med* 1990;322:315-7.



*Hop! Eto zaprijeke,*

nedužne doduše, koja ali isto tako kao i Nivea spada u zimski sport. Ta znate da vjetar i hladnoća stavljaju na kožu velike zahtjeve i da se ona suši. Koži je stoga potrebna naročita zaštita ako ne želite, da postane opora, crvena i da ne popuca. Za tu svrhu je Nivea-Creme i Nivea-Ulje idealno i jednostavno sredstvo usljed sadržine koži slične materije Eucerita. Zato uveče, ujutro i prije izleta natarite se, odnosno nauljite se dobro. Uspjeh: Nikakvo neugodno stezanje već mekana glatka koža i svjež sportski izgled.



By winter sport - Nivea cream; year 1936.  
(from the collection of Mr. Zlatko Puntijar)