

## Seborrheic Dermatitis – An Early and Common Skin Manifestation in HIV Patients

**Paraskevi Chatzikokkinou<sup>1</sup>, Konstantinos Sotiropoulos<sup>2</sup>, Alexandros Katoulis<sup>3</sup>, Roberto Luzzati<sup>4</sup>, Giusto Trevisan<sup>1</sup>**

<sup>1</sup>Department of Dermatology and Venereology, University Hospital of Trieste, Trieste, Italy; <sup>2</sup>Second Department of Internal Medicine Propedeutic; <sup>3</sup>Second Department of Dermatology and Venereology, Attikon University Hospital, Athens, Greece; <sup>4</sup>Department of Infectious Diseases, University Hospital of Trieste, Trieste, Italy

### Corresponding author:

Paraskevi Chatzikokkinou, MD  
U.C.O di Dermatologia e Venereologia  
Università di Trieste Ospedale Maggiore  
34100 Trieste  
Italy  
[chatzikokkinouparaskevi@hotmail.com](mailto:chatzikokkinouparaskevi@hotmail.com)

**SUMMARY** Seborrheic dermatitis is a common dermatosis occurring on the scalp, face and chest. In the general population, the prevalence of seborrheic dermatitis varies between 3% and 5%, while in HIV positive patients there is an increased prevalence of seborrheic dermatitis ranging between 30% and 83%. Seborrheic dermatitis occurs early in the course of HIV disease and may be an initial clinical marker of HIV infection.

**KEY WORDS:** seborrheic dermatitis, cutaneous HIV markers, papulosquamous skin diseases, seborrhea, *Malassezia furfur*

Received: July 22, 2008

Accepted: October 21, 2008

### INTRODUCTION

Seborrheic dermatitis (SD) is a common chronic papulosquamous dermatosis with remissions and exacerbations, typically located in areas with rich supply of sebaceous glands, i.e. the scalp, face and upper trunk. Clinical manifestations of the disease vary in severity from wild dandruff to exfoliative erythroderma (1-4). Many cross-sectional as well as cohort studies have examined the association between SD and human immunodeficiency virus (HIV) infection. We reviewed current literature regarding SD characteristics, focusing on differences in clinical manifestations, prevalence and treatment between general population and HIV patients. The aim is to demonstrate that SD is more

common, has an early onset and presents with severe clinical syndrome in HIV patients, thus posing therapeutic difficulties in this patient population.

### EPIDEMIOLOGY OF SEBORRHEIC DERMATITIS

SD affects newborns, infants and adults, occurs in persons of all races, and the clinical syndrome is more severe in males than in females. The prevalence of SD in the general population varies between 3% and 5%, increasing to 30%-83% in human immunodeficiency virus (HIV) positive and acquired immunodeficiency syndrome (AIDS)

patients (1,5). SD is closely related to infantile SD (cradle cap or diaper rash) and to neurological disorders such as Parkinson's disease (2,6,7). It is commonly worsened by changes in environment humidity, changes in seasons, trauma (e.g., scratching) or emotional stress (8).

### ETIOLOGY OF SEBORRHEIC DERMATITIS

The etiology of seborrheic dermatitis is poorly understood, although different lines of evidence support the role of *Malassezia (M.) furfur* (previously *Pityrosporum (P.) ovale*) as the causative yeast (9). Furthermore, the success of antifungal medications in treating SD provides new evidence for this view. Many studies describe the effectiveness of antifungal medications, paralleled by a reduction in the number of *P. ovale* and leading to amelioration of SD lesions (10,11).

Gupta *et al.* found *M. globosa* to be the predominant species in SD patients, while Sei confirmed the predominant presence of *M. globosa* along with *M. restricta* in SD patients, in contrast to *M. sympodialis*, which was detected in healthy skin of normal population (2,12).

*M. furfur* is part of the normal resident skin flora, but under certain circumstances it may cause or aggravate a spectrum of skin diseases including pityriasis versicolor, atopic dermatitis and SD (13). Currently advanced laboratory methods like RAPD-PCR analyses can offer distinct differentiation between *M. furfur* isolates from pityriasis versicolor and SD in patients with or without AIDS (14).

However, it is uncertain whether or not SD patients have higher *Malassezia* counts than normal controls (15), although a correlation between yeast density and severity of SD has been reported (16). It has been suggested that the density of *Malassezia* organisms is only important for the individuals who are susceptible to SD. An abnormal immune response to *Malassezia* could be another explanation. Bergbrant *et al.* report that in patients with AIDS who typically show abnormalities of T-cell functions, the activation of the alternative complement pathway by *P. ovale* which does not require T-cell function is depressed and could be an explanation for the inflammatory response (17).

Parry and Sharpe suggest that SD is not caused by an altered immune response to *Malassezia* yeast and propose toxin production or lipase activity as potential mechanisms (9). Other researchers have shown that the lipophilic yeast

is able to activate the alternative pathway of complement (18). All the above mentioned processes can induce nonspecific skin inflammation. Briefly, a defect in immune response (specific or not) may facilitate fungal survival in the skin.

Furthermore, endogenous factors have always been implicated in the pathogenesis of SD, along with others factors, e.g., the role of lipid hormones. The lipid amount on the skin in patients with SD was significantly higher than in controls (19).

Similarly, Ostlere *et al.* suggest that the skin surface lipid composition in men with SD differs from that of unaffected controls (20). Since SD is more common in men than in women, hormones may play a role and androgen influence on the pilosebaceous unit has been suggested. In addition, lifestyle and nutrition may be involved in SD development, especially in those suffering from alcoholism (21) or depression (8).

### SEBORRHEIC DERMATITIS IN HIV INFECTED PATIENTS

Cutaneous manifestations including SD may occur at any stage of HIV infection (22,23). In fact, the first clinical manifestations related to HIV infection are often located on the skin. SD is a common dermatosis occurring most frequently on the scalp, face and chest in HIV positive patients. In these patients, SD tends to occur early in the course of the disease (CD4<sup>+</sup> T-cell count range 450-550 cells/ $\mu$ L) (24-26), and is usually more severe and difficult to diagnose and treat than in the general population (27). The butterfly distribution of the rash when followed by a non-diagnostic biopsy, as sometimes happens, may mislead to the diagnosis of discoid lupus erythematosus unless the clinician is aware of the underlying immunodeficiency (26,28). Additionally, because tinea infections such as tinea faciei may occur in this patient population and mimic SD, a potassium hydroxide examination for hyphae should be performed if the diagnosis is in doubt (29).

It has been shown that during the course of HIV disease almost 85% of patients will manifest SD at least once, although these data seem to be closely linked to the type of the patient population and the duration of follow-up (31). In Mali, where SD is quite rare, development of this dermatosis has been used as a predictor for HIV infection (31,32).

The introduction of highly active antiretroviral therapy (HAART) has led to a dramatic reduction in the incidence of opportunistic disorders and HIV-related mortality (30,33,34). Hengee *et al.* re-

port that 25.3% of HIV patients develop SD lesions prior to HAART (35). In this series, the cumulative incidence of SD did not change significantly (17.6%) among patients under HAART. In a study reported by Rosatelli *et al.*, 223 HIV patients were examined during the 1989-1993 period, and 152 of these 223 patients had full-blown AIDS, whereas the remaining 71 patients were asymptomatic. It was concluded that SD was the most frequent disorder affecting 24% of patients in the initial stages of HIV and 30.3% of those with AIDS (36).

In addition, many studies, mainly cross-sectional or cohort studies, have examined the association between skin disease prevalence and CD4 counts, concluding that a low CD4 cell count or higher viral load were linked with extended skin abnormalities (37-39). Also, patients suffering from SD and decreased CD4 cell counts were more likely to experience rapid progression to advanced disease (40).

## TREATMENT

Antimycotics remain a popular treatment for SD, in the form of shampoos or creams. Many double-blind studies have documented the efficacy of ketoconazole 2% in reducing flaking and *Malassezia* counts (41,42); furthermore, ketoconazole 2% shampoo has been shown to have a significant prophylactic effect when used once weekly (11). Nevertheless, low potency topical corticosteroids (e.g., hydrocortisone) and emollients have been used in the initial stages of treatment (43).

Additional measures including shampoos with coal tar, pyrithione zinc, then selenium sulfide and lithium succinate ointment may be effective treatment for SD both in immunocompetent individuals and in those with AIDS (44).

Newer topical successful therapeutic options for facial SD in HIV patients are pimecrolimus 1% and tacrolimus cream (45-47). These modulators are nonsteroid calcineurin inhibitors that exert their anti-inflammatory effects by inhibiting the release of pro-inflammatory cytokines and mediators from T-cells and other cells, involved in skin inflammation (48,49).

A recent open-label pilot study conducted by de Moraes *et al.* documented that all patients responded to therapy despite their immune status and that pimecrolimus did not alter CD4<sup>+</sup> and CD8<sup>+</sup> T-cells counts or viral load during the treatment period (5). Furthermore, metronidazole has been used in the treatment of SD, with some promising results (50,51).

## CONCLUSION

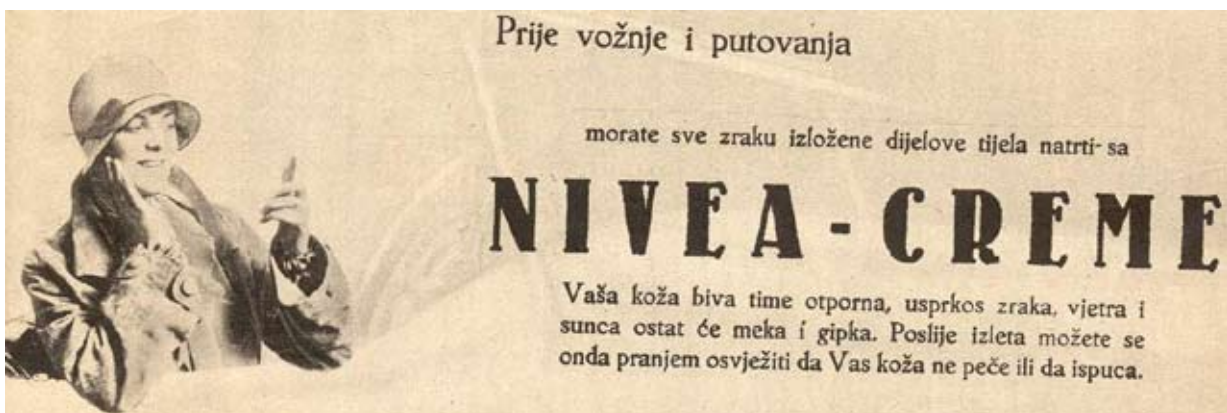
SD is one of the earliest and common skin diseases in the course of HIV disease. Careful examination of the skin may be highly useful for the diagnosis of HIV infection and the severe forms of common skin diseases in HIV patients (such as SD) may provide a clue for the clinician to suspect the underlying HIV infection (27,36).

## References

1. Gupta AK, Madzia SE, Batra R. Etiology and management of seborrheic dermatitis. *Dermatology* 2004;208:89-93.
2. Gupta AK, Bluhm R. Seborrheic dermatitis. *J Eur Acad Dermatol Venereol* 2004;18:13-26.
3. Jansen T, Plewig G. Seborrheic dermatitis. In: Freedberg IM, Eisen AZ, Wolff K, *et al.* Fitzpatrick's *Dermatology in General Medicine*, Vol. 1, 5<sup>th</sup> edn. McGraw-Hill, New York, 1999, 1482-9.
4. Schwartz RA, Janusz CA, Jannige CK. SD: an overview. *Am Fam Physician* 2006;74:125-30.
5. de Moraes AP, de Arruda EA, Vitoriano MA, de Moraes Filho MO, Bezerra FA, de Magalhães Holanda E, *et al.* An open-label efficacy pilot study with pimecrolimus cream 1% in adults with facial seborrheic dermatitis infected with HIV. *Eur Acad Dermatol Venereol* 2007;21:596-601.
6. Cowley NC, Farr RM, Shuster S. The permissive effect of sebum in seborrheic dermatitis: an explanation of the rash in neurological disorders. *Br J Dermatol* 1990;122:71-6.
7. Binder RL, Jonelis FJ. Seborrheic dermatitis in neuroleptic-induced parkinsonism. *Arch Dermatol* 1983;119:473-5.
8. Maietta G, Fornaro P, Rongioletti E, Rebora A. Patients with mood depression have a high prevalence of seborrheic dermatitis. *Acta Derm Venereol* 1990;70:432-4.
9. Parry ME, Sharpe GR. Seborrheic dermatitis is not caused by an altered immune response to *Malassezia* yeast. *Br J Dermatol* 1998;139:254-63.
10. Ortonne J-P, Lacour J-P, Vitetta A, Le Fichoux Y. Comparative study of ketoconazole 2% foaming gel and betamethasone dipropionate 0.05% lotion in the treatment of seborrheic dermatitis in adults. *Dermatology* 1992;184:275-80.

11. Peter RU, Richarz-Barthauer U. Successful treatment and prophylaxis of scalp seborrheic dermatitis and dandruff with 2% ketoconazole shampoo: results of a multicentre, double-blind, placebo-controlled trial. *Br J Dermatol* 1995;132:441-5.
12. Sei Y. *Malassezia* related disease. *Nippon Ishinkin Gakkai Zasshi* 2006;47:75-80.
13. Hort W, Nilles M, Mayser P. *Malassezia* yeasts and their significance in dermatology. *Hautarzt* 2006;57:633-43.
14. Gandra RF, Simão RC, Matsumoto FE, da Silva BC, Ruiz LS, da Silva EG, *et al.*. Genotyping by RAPD-PCR analyses of *Malassezia furfur* strains from pityriasis versicolor and seborrheic dermatitis patients. *Mycopathologia* 2006;162:273-80.
15. Bergbrant IM, Faergemann J. Seborrheic dermatitis and *Pityrosporum ovale*: a cultural and immunological study. *Acta Derm Venereol (Stockh)* 1989;69:332-5.
16. Heng MCY, Henderson CL, Barker DC, Habberfelde G. Correlation of *Pityrosporum ovale* density with clinical severity of seborrheic dermatitis as assessed by a simplified technique. *J Am Acad Dermatol* 1990;23:82-6.
17. Bergbrant I-M, Johansson S, Robbins D, Scheynius A, Faergemann J, Soderstrom T. An immunological study in patients with seborrheic dermatitis. *Clin Exp Dermatol* 1991;16:331-8.
18. Neuber K, Kröger S, Gruseck E, Abeck D, Ring J. Effects of *Pityrosporum ovale* on proliferation, immunoglobulin (IgA, G, M) synthesis and cytokine (IL-2, IL-10, IFN $\gamma$ ) production of peripheral blood mononuclear cells from patients with seborrheic dermatitis. *Arch Dermatol Res* 1996;288:532-6.
19. Faergemann J. *Pityrosporum* species as a cause of allergy and infection. *Allergy* 1999;54:413-9.
20. Ostlere LS, Taylor CR, Harris DW, Rustin MH, Wright S, Johnson M. Skin surface lipids in HIV-positive patients with and without seborrheic dermatitis. *Int J Dermatol* 1996;35:276-9.
21. Rosset M, Oki G. Skin diseases in alcoholics. *O J Stud Alcohol* 1971;32:1017-25.
22. Rigopoulos D, Pappazios V, Katsambas A. Cutaneous markers of HIV infection. *J Clin Dermatol* 2004;22:487-98.
23. Myskowski PL, Ahkami R. Dermatologic complications of HIV infection. *Med Clin North Am* 1996;80:1415-35.
24. Schaub NA, Drewe J, Sponagel L, Gilli L, Courvoisier S, Gyr N, *et al.* Is there a relation between risk groups or initial CD4 T-cell counts and prevalence of seborrheic dermatitis in HIV-infected patients? *Dermatology* 1999;198:126-9.
25. Reynaud-Mendel B, Janier M, Gerbaka J, Hakim C, Rabian C, Chastang C, *et al.* Dermatologic findings in HIV-infected patients: a prospective study with emphasis on CD4+ cell count. *Dermatology* 1996;192:325-8.
26. Marino CT, McDonald E, Romano JF. Seborrheic dermatitis in acquired immunodeficiency syndrome. *Cutis* 1991;50:217-8.
27. Buchness MR. Treatment of skin diseases in HIV-infected patients. *Dermatol Clin* 1995;13:231-8.
28. Eisenstat BA, Wormser GP. Seborrheic dermatitis and butterfly rash in AIDS. *N Engl J Med* 1984;311:189.
29. Gerfand JM, Rudikoff D. Evaluation and treatment of itching in HIV-infected patients. *Mt Sinai J Med* 2001;68:298.
30. Garman ME, Tying SK. The cutaneous manifestations of HIV infection. *Dermatol Clin* 2002;20:193-208.
31. Mahe A, Boulais C, Blanc L, Keita S, Bobin P. Seborrheic dermatitis as a revealing feature of HIV infection in Bamako, Mali. *Int J Dermatol* 1994;33:601-2.
32. Mahe A, Simon F, Coulibaly S. Predictive value of seborrheic dermatitis and other common dermatoses for HIV infection in Bamako, Mali. *J Am Acad Dermatol* 1998;38:1084-6.
33. Kreuter A, Schugt I, Hartmann M, Rasokat H, Altmeyer P, Brockmeyer NH. Dermatological diseases and signs of HIV infection. *Eur J Med Res* 2002;7:57-62.
34. Dunic I, Vesic S, Jevtovic DJ. Oral candidiasis and seborrheic dermatitis in HIV-infected patients on highly active antiretroviral therapy. *HIV Med* 2004;5:50-4.
35. Hengge UR, Franz B, Goos M. Decline of infectious skin manifestations in the era of highly active antiretroviral therapy. *AIDS* 2000;14:1069-70.
36. Rosatelli JB, Machado AA, Roselino AM. Dermatoses among Brazilian HIV-positive pa-

- tients: correlation with evolutionary phases of AIDS. *Int J Dermatol* 1997;36:729-34.
37. Tzung TY, Yang CY, Chao SC, Lee JY. Cutaneous manifestation of human immunodeficiency virus infection in Taiwan. *Kaohsiung J Med Sci* 2004;20:216-24.
  38. Goh BK, Chank RK, Sen P, Theug CT, Tan HH, Wun YJ, *et al.* Spectrum of skin disorders in human immunodeficiency virus-infected patients in Singapore and the relationship to CD4 lymphocyte counts. *Int J Dermatol* 2007;46:695-9.
  39. Mirmirani P, Hessol NA, Maurer TA, Berger TG, Nguyen R. Prevalence and predictors of skin disease in the women's Interagency HIV Study (WIHS). *J Am Acad Dermatol* 2001;44:785-8.
  40. Ippolito F, Passi D, Di Carlo A. Is seborrheic dermatitis a clinical marker of HIV disease? *Minerva Ginecol* 2000;25 (Suppl 1):54-8.
  41. Piérard-Franchimont C, Piérard GE, Arrese JE, De Doncker P. Effect of ketoconazole 1% and 2% shampoos on severe dandruff and seborrheic dermatitis: clinical, squamometric and mycological assessments. *Dermatology* 2001;202:171-6.
  42. Stratigos JD, Antoniou C, Katsambas A, Boehler K, Fritsch P, Schmolz A *et al.* Ketoconazole 2% cream *versus* hydrocortisone 1% cream in the treatment of seborrheic dermatitis: a double-blind comparative study. *J Am Acad Dermatol* 1988;19:850-3.
  43. Johnson BA, Nunley JR. Treatment of seborrheic dermatitis. *Am Fam Physician* 2000;61:2703-10.
  44. Langtry JAA, Rowland Payne CME, Straughton RCD, Stewart JC, Horrobin DF. Topical lithium succinate ointment (Efalith) in the treatment of AIDS-related seborrheic dermatitis. *Clin Exp Dermatol* 1997;22:216-9.
  45. Crutchfield CE 3<sup>rd</sup>. Pimecrolimus: a new treatment for seborrheic dermatitis. *Cutis* 2002;70:207-8.
  46. Brownell I, Quan LT, Hsu S. Topical pimecrolimus in the treatment of seborrheic dermatitis. *Dermatol Online J* 2003;9:13.
  47. Rigopoulos D, Ioannides D, Kalogeromitros D, Gregoriou S, Katsambas A. Pimecrolimus cream 1% vs. betamethasone 17-valerate cream 0.1% in the treatment of seborrheic dermatitis. A randomized open-label clinical trial. *Br J Dermatol* 2004;151:1071-5.
  48. Hultsch T, Spengel J. Immunomodulation and safety of topical calcineurin inhibitors for the treatment of atopic dermatitis. *Dermatology* 2005;211:174-87.
  49. Wolff K, Stuetz A. Pimecrolimus for the treatment of inflammatory skin disease. *Exp Opin Pharmacother* 2004;5:643-55.
  50. Parsad D, Pandhi R, Negi KS, Kumar B. Topical metronidazole in seborrheic dermatitis – a double-blind study. *Dermatology* 2001;202:35-7.
  51. Iudica AC. Does treatment with topical metronidazole improve seborrheic dermatitis? *J Fam Pract* 2001;50:492.



Before driving and travelling – apply Nivea cream; year 1936.  
(from the collection of Mr. Zlatko Puntijar)