

Treatment of Stable Vitiligo by ReCell System

Valerio Cervelli, Barbara De Angelis, Alberto Balzani, Gianfranco Colicchia, Diana Spallone, Monica Grimaldi

Department of Plastic and Reconstructive Surgery, Policlinico Casilino, University of Tor Vergata, Rome, Italy

Corresponding author:

Diana Spallone, MD
Department of Plastic and Reconstructive Surgery,
Policlinico Casilino,
University of Tor Vergata,
Via U.Saba 71
I-00100 Rome
Italy
dianaspallone@hotmail.it

Received: December 16, 2008

Accepted: July 1, 2009

SUMMARY The aim of our study was to analyze the results obtained with the ReCell system for surgical treatment of stable vitiligo. At Department of Plastic and Reconstructive surgery, University of Tor Vergata in Rome, we treated 15 patients with stable vitiligo during a 2-year period. The stability of vitiligo lesions varied between 1 and 4 years. The mean stability was 2.25. The disease activity according to Vitiligo Disease Activity Score (VIDA) was 0 in all cases, which means that all patients had a stability of greater than or equal to 1 year. Three (20%) patients had vitiligo vulgaris, seven (46.6%) segmental vitiligo and five (33.3%) focal vitiligo. Repigmentation was assessed using the Vitiligo Area Scoring Index (VASI). The extent of pigmentation was scored as excellent, good, fair, and poor depending on the percentage of repigmentation in the previously depigmented site. The color of the repigmented area was compared with the adjacent normally pigmented area: excellent color match was present in ten (66.6%) and good in five (33.3%) cases. There was no fair or poor outcome. Repigmentation greater than 75% was recorded in 12 (80%) and 25% to 50% repigmentation in three (20%) of 15 patients treated. ReCell® is a feasible, simple and safe technique. The method that uses noncultured autologous epidermal suspension is simpler, less expensive, less time consuming, and does not require sophisticated laboratory facilities as compared with the methods employing cultured melanocytes.

KEY WORDS: vitiligo, skin grafting, cell transplantation, ReCell system

INTRODUCTION

Vitiligo is one of the most common acquired pigmentation disorders. This cosmetically disfiguring condition, particularly in dark-skinned individuals, affects 0.1%-2% of the world's population, with an equal sex distribution (1). A general knowledge of the causes of depigmentation is particularly relevant for understanding the possibilities and limitations of surgery for vitiligo.

As it is well known, vitiligo is a visible cosmetic defect that leads to serious emotional stress. Vitiligo lesions on the exposed areas of the body, especially on the face, have strong impact on the patient's self-esteem and social relationships.

Treatment of vitiligo is often difficult and disappointing. There are many surgical options in the treatment of refractory vitiligo including minigrafting,

micropigmentation, split-thickness skin grafting, suction blister transplantation, transplantation of cultured autologous melanocytes, keratinocyte/melanocyte co-cultures, or noncultured suspension of epidermal cells (2).

In the last years, several surgical therapies including the use of autologous skin grafts have been proposed. These methods can be used in vitiligo that is refractory to medical treatment, in patients with piebaldism, or to obtain repigmentation in case of thermal burns, trauma, and inflammation (3). It is mandatory to treat only patients showing stability in their vitiligo lesions: hypopigmented patches should be stable for at least 2 years before surgical therapy. This article deals with the ReCell® technique in the treatment of refractory vitiligo.

PATIENTS AND METHODS

The study included 15 otherwise healthy patients (six men and nine women) admitted for stable vitiligo to Department of Plastic and Reconstructive Surgery, University of Tor Vergata, Rome. The study was approved by the Ethics Committee of the National Center for Vitiligo and Psoriasis. Patients were treated between January 2007 and February 2008. The stability of vitiligo lesions varied between 1 and 4 years, the mean stability 2.25 years. The disease activity according to Vitiligo Disease Activity Score (VIDA) was 0 in all cases, which means that all patients had a stability of greater than or equal to 1 year. Three (20%) patients had vitiligo vulgaris, seven (46.6%) had segmental vitiligo and five (33.3%) had focal vitiligo. The involved area was evaluated by use of the Vitiligo Area Scoring Index (VASI). One hand unit, which encompasses the palm plus volar surface of all digits, is approximately 1% of the total body surface area and was used as a guide to estimate the baseline percentage of vitiligo involvement of each body region. The total body VASI was then calculated using the following formula, considering the contributions of all body regions (possible range, 0-100):

$$VASI = \sum [\text{Hand Units}] \times [\text{Residual Depigmentation}]$$

Patients were informed about the study and their written consent was obtained. Inclusion criteria were: stable vitiligo cases having no progression of existing lesions and/or no appearance of new lesions in the past 1 year and with areas involved less than 320 cm². Exclusion criteria were: patient less than 10 years of age, extensive depigmented areas where grafting may not yield cos-

metically good results, concomitant serious systemic disease, and keloidal/bleeding tendency.

The following patient data were recorded for regular follow up: name, age, sex, occupation, and address. Thorough disease history was taken including disease duration, site of onset, progression, trichrome/multichrome sign, type of lesion, distribution and stability of lesion (Table 1). Medical management for vitiligo or any other disease, if taken, was noted.

Table 1. Demographic and clinical characteristics

Age (yrs)	18-45 (mean)
Sex	
male	6
female	9
Duration of disease (yrs)	1-4 (mean 2.25)
Positive family history	
paternal	5 (33.3%)
maternal	2 (13.3%)
no family history	6 (40%)
Type of vitiligo	
vitiligo vulgaris	3 (20%)
segmental vitiligo	7 (46.6%)
focal vitiligo	5 (33.3%)
Localization	
forearm	2 (13.3%)
hand	5 (33.3%)
lower limb	4 (26.6%)
foot	4 (26.6%)

General physical examination and systemic evaluation were performed to rule out any other concomitant dermatologic or medical disorder. Oral antibiotics and analgesics were administered until postoperative day 7. Minimal follow up period was 6 months.

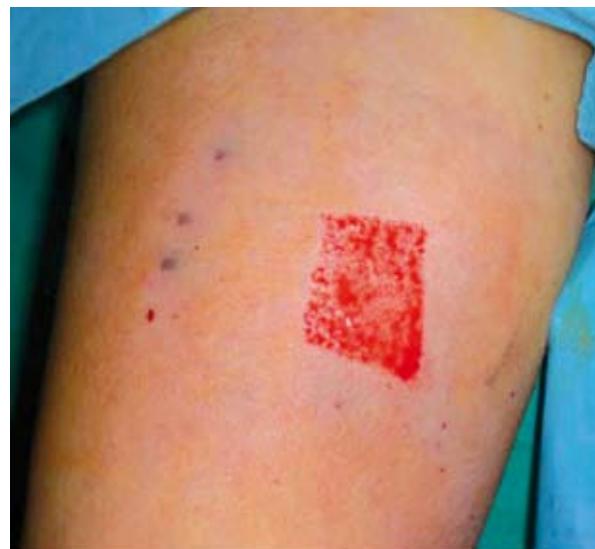


Figure 1. Cutaneous biopsy.

Pretreatment and post-treatment photographs were taken to document the pigmentation before and after the surgery at the end of the first, third and sixth months. A square lattice grid on tracing paper was used for the assessment of the size of the donor and transplanted areas, and the extent of the spread of repigmentation. Repigmentation was assessed by use of VASI. Global assessments were made to compare the VASI system with analogous ordinal scales. Upon completion of the study, each patient and one of the authors separately graded the treated sides on a 6-point ordinal scale based on global estimate of the change in vitiligo as follows: complete improvement (100%), very much improved (76%-99%), much improved (51%-75%), improved (26%-50%), minimal change (1%-25%), and no change. The results were assessed by the plastic surgeon and the patients themselves, their family members and/or close friends. Cosmetic results were graded on a 4-point ordinal scale by the patients and the surgeon as excellent, good, fair and poor.

ReCell® kit

ReCell® is a single-use battery-operated autologous cell-harvesting device. It consists of a processing unit with built-in heating mechanism for warming the enzyme solution to optimum working temperature (37 °C) and a removable insert to act as a sterile Petri dish for use when separating and scraping the skin biopsy. In addition, it contains a sealed glass vial of enzyme, lyophilized trypsin 0.75% (minimum activity 3000 Tu mL)¹, equivalent to 50 Ikat mL¹, 1x10 mL ampoule of sterile water, 1x10 mL vial of compound sodium lactate.

Biopsy and cell separation using ReCell® kit

A thin split-thickness cutaneous biopsy (0.2-0.3 mm) was harvested from an uninvolved area using a Zimmer dermatome (Zimmer, Indiana, USA). According to the manufacturer's instructions, as the cellular spread rate is 1:80, the biopsy area was 1 cm² when the recipient area was 80 cm² and 4 cm² when the recipient area was 320 cm². The epidermis was put in 4.5 mL of trypsin solution for 20 min at 37-38 °C to begin the intercellular detachment. While the biopsy was processed, classic escharotomy was applied on eschars of vitiligo and deep partial thickness areas with thick fibrin slough. Upon completion of digestion with trypsin, the epidermis was separated from the dermal layers and epidermal cells were further divided with the scalpel blade. Cells were further suspended in

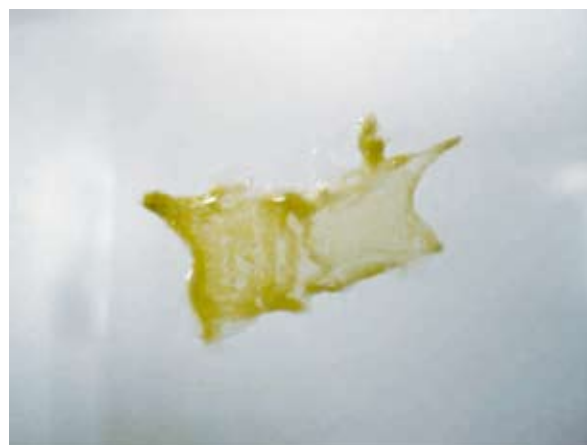

Figure 2. Separation of the epidermal layer from the dermis.

lactate solution, aspirated several times to create cell suspension with a 5-mL syringe and sprayed over the area to be treated and the biopsy site. All procedures were performed in the operating room and under general anesthesia. In all patients, an adequately debrided wound bed was achieved with tangential escharotomy.

Medication was administered with non-adhering dressings (Adaptic, Johnson and Johnson Wound Management, Ethicon) and gauzes on both areas.

RESULTS

From January 2007 to February 2008, we enrolled 15 patients (six men and nine women) for the clinical trial. Demographic and clinical characteristics and outcome for both groups are summarized in Table 1. Five (33.3%) patients had paternal family history, three (20%) had maternal family history, and seven (46.6%) had no family history of vitiligo.

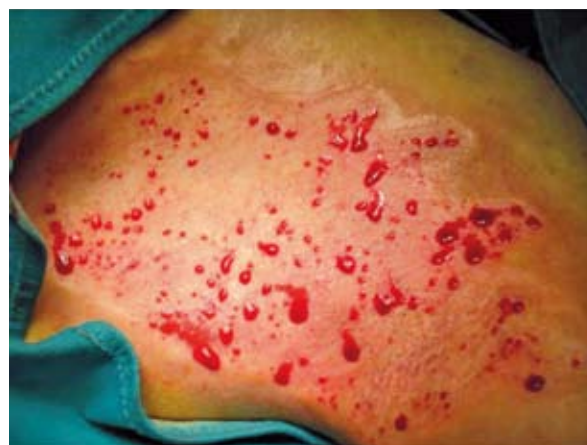

Figure 3. Recipient area.

Table 2. Functional and cosmetic outcome

Outcome	n (%)
Extent of repigmentation (%)	
100	0 (0%)
76-99	12 (80%)
51-75	0 (0%)
25-50	3 (20%)
1-25	0 (0%)
Response grading (patients)	
excellent	10 (66.6%)
good	5 (33.3%)
fair	0 (0%)
poor	0 (0%)
Time to repigmentation (weeks)	
5	9 (60%)
3	6 (40%)

The involved area were forearms in two (13.3%), hands in five (33.3%), lower limbs in four (26.6%) and feet in four (26.6%) patients. Repigmentation was assessed by use of VASI. The main parameter to measure the efficacy of treatment was the percentage area of repigmentation in test lesions. Patients had clinical stability of 3, 5 and 1 year. Out of 15 study patients, greater than 75% repigmentation was achieved in 12 (80%) and 25%-50% repigmentation in three (20%) patients, whereas no repigmentation at all was not recorded in any of the study patients. The cosmetic result was scored as excellent, good, fair, or poor by the surgeon and the patients. The color of the repigmented area was compared with the adjacent normally pigmented area; excellent color match was present in ten (66.6%) and good in five (33.3%) cases. There was no fair or poor outcome. The data collected were analyzed and are shown in Table 2. The time to repigmentation was three weeks in six (40%) and five weeks in nine (60%) patients. There were no serious complications like pain or infection, either at biopsy site or in the involved area. The patient subjective global assessment showed that ten (66.6%) patients were very satisfied and five (33.3%) were satisfied. None of the patients reported being unsatisfied with the cosmetic result.

DISCUSSION

The skin contains a number of different cell types (4). Keratinocytes are the most common cell type in the epidermis and form the surface barrier layer. Melanocytes are found in the lower layer of the epidermis and provide skin color. Proliferation, differentiation and migration of melanocytes and melanoblasts are regulated by keratinocyte-derived factors and some coat color genes (5).

Keratinocytes synthesize and secrete a wide variety of cytokines. As its well known, cytokines provide the cell-to-cell communication system between adjacent cells (paracrine effect), between cells at distant sites (endocrine effect), and inter-cellular effects (autocrine effect).

Any therapy for vitiligo must explain not only the repopulation of melanocytes but also their functional development. Vitiligo is an acquired pigmentary disorder characterized by depigmentation of the skin and hair. As the pathogenesis of the disease is still obscure, the treatment of vitiligo has generally been unsatisfactory and often disappointing.

Topical therapies like steroids, psoralen, tacrolimus, placental extract, and systemic steroids are commonly used in daily clinical practice. These diverse medical therapies have been shown to produce satisfactory repigmentation in only 50% of cases, especially in limited extent vitiligo, and because of their simplicity, they might be considered as a reasonable first step in the treatment of vitiligo (6), reserving more complex surgical methods (including tattooing, etc.) when resistant forms of vitiligo are encountered (7).

Surgical treatment options for vitiligo offer the potential for rapid and more desirable amounts of repigmentation. The different modalities of surgical techniques include tattooing, organ-cultured fetal skin allografting, epidermal culture grafting, melanocyte culture grafting, autologous noncultured melanocyte-keratinocyte cell transplantation, epidermal grafting by the suction blister technique, thin Thiersch split skin grafting, or miniature punch grafting. Treatment of vitiligo is very complex. It is

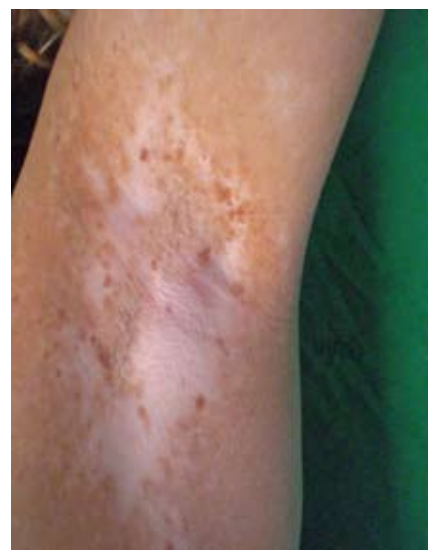


Figure 4. Preoperative view.

well recognized that the response varies according to the anatomic location of the lesion. Vitiliginous lesions localized in the dorsum of the hands, distal sections of limbs, genitals, around the mouth and nipples are characterized by poor response to conservative therapy (pharmacological therapy, phototherapy, photochemotherapy, immunotherapy) (8). It is possible to achieve repigmentation using surgical treatment based on the transfer of autologous melanocytes to the vitiliginous lesions (2).

Most tissue-engineered skin is created by expanding skin cells in the laboratory (at a rate much greater than would be achieved in the patient) and using them to restore barrier function (the primary objective in burn patients) or to initiate wound healing (in chronic non-healing ulcers) (4). Other uses include accelerating healing, reducing pain in superficial burns and correcting conditions in which healing has been suboptimal (for example, in scars, contractures or pigmentary defects).

Since 1987, there have been many reports on transplantation of cultured autologous melanocytes (9,10). As it involves *in vitro* multiplication of cells, the use of various culture media is obligatory. Culture techniques require a state-of-the-art laboratory, highly trained staff and at least two visits by the patient, and are quite expensive. As such, they are restricted to very specialized centers and are mainly useful for research purposes. Subsequently, the culture technique was modified by eliminating the step of *in vitro* culture of melanocytes, and cells were transplanted directly onto the affected depigmented area (11). The use of the

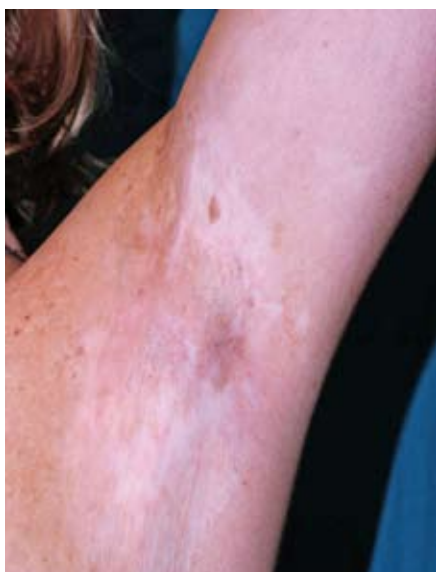

Figure 5. Postoperative view at 2 years without sun exposure.

ReCell® device for harvesting and preparing cells for seeding produced consistent cell counts with a high viability. In addition, the isolation of the cell population directly from the DEJ provides a source of cells with no selection, as would be expected during culturing, and contains not only basal layer keratinocytes but also melanocytes, papillary dermal fibroblasts and Langerhans giant cells. This may enhance the final outcome, with the presence of melanocytes enhancing repigmentation of the wound. The use of sodium lactate as a cell suspension medium was first initiated by Clinical Cell Culture for ReCell® (12). This device was developed to treat superficial burn injuries with the help of epidermal cell transplantation (12,13). During the management of superficial burn by ReCell® it was observed that the resultant healing was accompanied by a satisfactory repigmentation. This led to the use of this device in the treatment of stable vitiligo maculae. In our study, we treated 15 patients with stable vitiligo. Repigmentation was assessed using VASI. We performed global assessment to compare the VASI system with analogous ordinal scales. Out of 15 study patients, greater than 75% repigmentation was achieved in 12 (80%) and 10%-50% repigmentation in three (20%) patients, whereas none of the patients had no repigmentation at all. The patient subjective global assessment showed 66% of them to be very satisfied and 33% satisfied. Our results proved the efficacy of ReCell for the treatment of vitiligo. However, based on the currently available literature, it is difficult to compare the efficacy of different treatment modalities not only because the measurement of repigmentation is not standardized, but also because most of the published studies were uncontrolled by design.

CONCLUSION

In recent years, several molecules such as leukotriene C4, transforming growth factor, 50 basic fibroblast growth factor, stem cell factor and endothelin 151 have been shown to stimulate pigment cell migration *in vitro* (14). If similar and/or more potent molecules are identified, it is conceivable that when applied to the vitiliginous skin, they could stimulate continuous melanocyte migration from the edge of the lesion and/or hair follicle reservoir towards the depigmented skin for repigmentation of extensive vitiligo areas.

Tissue-engineered skin has delivered considerable benefits to patients with burns and chronic wounds, and has enormous potential that is only just beginning to be realized.

The method that uses noncultured autologous epidermal suspension is simpler, less expensive, less time consuming, and does not require sophisticated laboratory facilities, when compared with the methods employing cultured melanocytes; however, limitations still exist: the surface areas that can be covered using the noncultured method are smaller than those which can be treated with cultured melanocyte grafting (15).

In conclusion, ReCell® may be an effective method to treat vitiligo. Studies on larger series of patients are required to confirm its efficacy.

References

1. Alkhateeb A, Fain PR, Thody A, Bennett DC, Spritz RA. Epidemiology of vitiligo and associated autoimmune diseases in Caucasian probands and their families. *Pigment Cell Res* 2003;16:1-7.
2. Czajkowski R, Placek W, Drewa T, Kowalyszyn B, Sir J, Weiss W. Autologous cultured melanocytes in vitiligo treatment. *Dermatol Surg* 2007;33:1027-36.
3. Lotti T, Gori A, Zanieri F, Colucci R, Moretti S. Vitiligo: new and emerging treatments. *Dermatol Ther* 2008;21:110-7.
4. MacNeil S. Progress and opportunities for tissue-engineered skin. *Nature* 2007;445:874-80.
5. Jeon S, Kim NH, Koo BS, Lee HJ, Lee AY. Bee venom stimulates human melanocyte proliferation, melanogenesis, dendricity and migration. *Exp Mol Med* 2007;39:603-13.
6. Khandpur S, Sharma VK, Manchanda Y. Comparison of minipunch grafting *versus* split-skin grafting in chronic stable vitiligo. *Dermatol Surg* 2005;31:436-41.
7. Babu A, Thappa DM, Jaisankar TJ. Punch grafting *versus* suction blister epidermal grafting in the treatment of stable lip vitiligo. *Dermatol Surg* 2008;34:166-78.
8. Halder RM, Young CM. New and emerging therapies for vitiligo. *Dermatol Clin* 2000;18:79-89.
9. Guerra L, Primavera G, Raskovic D, Pellegrini G, Golisano O, Bondanza S, *et al.* Erbium: YAG laser and cultured epidermis in the surgical therapy of stable vitiligo. *Arch Dermatol* 2003;139:1303-10.
10. Lerner AB, Halaban R, Klaus SN, Moellmann G. Transplantation of human melanocytes. *J Invest Dermatol* 1987;89:219-24.
11. Mulekar SV, Ghwish B, Al Issa A, Al Eisa A. Treatment of vitiligo lesions by ReCell *vs.* conventional melanocyte-keratinocyte transplantation: a pilot study. *Br J Dermatol* 2008;158:45-9.
12. Wood FM, Stoner ML, Flower BV, Fear MW. The use of a non-cultured autologous cell suspension and Integra dermal regeneration template to repair full-thickness skin wounds in a porcine model: a one-step process. *Burns* 2007;33:693-700.
13. Gravante G, Di Fede MC, Araco A, Grimaldi M, De Angelis B, Arpino A, *et al.* A randomized trial comparing ReCell system of epidermal cells delivery *versus* classic skin grafts for the treatment of deep partial thickness burns. *Burns* 2007;33:966-72.
14. Falabella R. Surgical approaches for stable vitiligo. *Dermatol Surg* 2005;31:1277-84.
15. Tegta GR, Parsad D, Majumdar S, Kumar B. Efficacy of autologous transplantation of non-cultured epidermal suspension in two different dilutions in the treatment of vitiligo. *Int J Dermatol* 2006;45:106-10.
16. Lotti T, Buggiani G, Troiano M, Assad GB, Delescluse J, De Giorgi V, *et al.* Targeted and combination treatments for vitiligo. Comparative evaluation of different current modalities in 458 subjects. *Dermatol Ther* 2008;21:20-6.
17. Mulekar SV. Long-term follow-up study of 142 patients with vitiligo vulgaris treated by autologous, non-cultured melanocyte-keratinocyte cell transplantation. *Int J Dermatol* 2005;44:841-5.
18. Mulekar SV, Al Issa A, Al Eisa A, Asaad M. Genital vitiligo treated by autologous, noncultured melanocyte-keratinocyte cell transplantation. *Dermatol Surg* 2005;31:1737-9.
19. Feliciani C, Gupta AK, Saucier DN. Keratinocytes and cytokine/growth factors. *Crit Rev Oral Biol Med* 1996;7:300-18.
20. Gupta S, Goel A, Kanwar AJ, Kumar B. Autologous melanocyte transfer *via* epidermal grafts for lip vitiligo. *Int J Dermatol* 2006;45:747-50.