

## Steatocystoma Multiplex Generalisata Partially Suppurativa – Case Report

Gyula László Fekete<sup>1</sup>, Júlia Edit Fekete<sup>2</sup>

<sup>1</sup>Department of Dermatology, University of Medicine and Pharmacy, <sup>2</sup>Public Health Center, Târgu-Mureş, Romania

### Corresponding author:

Gyula László Fekete, MD, PhD  
Department of Dermatology  
University of Medicine and Pharmacy Târgu-Mureş  
Bulevardul 1 Decembrie 1918, nr.211/27  
RO-540530 Târgu-Mureş  
Romania  
dermafek@yahoo.com

Received: November 29, 2009

Accepted: April 6, 2010

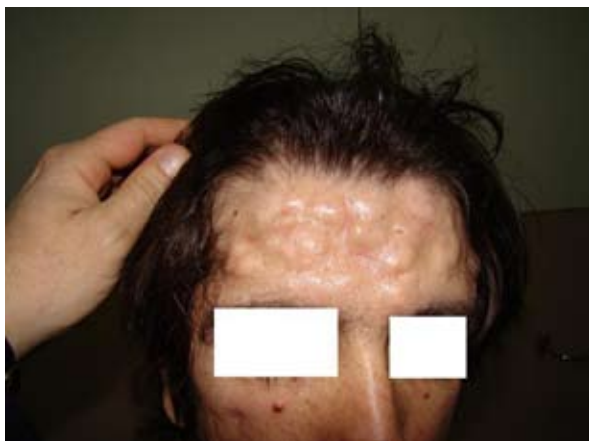**SUMMARY** Steatocystoma multiplex is a rare inherited disorder with an autosomal dominant mode of transmission, but sometimes it may appear sporadically. Usually the onset tends to occur during adolescence or early adult life. A clinical case of a 27-year-old male patient is presented. Since the age of 8, he had been presenting with multiple, asymptomatic, round-to-oval, well-defined, smooth-surfaced, yellow to skin-colored, 5- to 22-mm diameter cysts and nodules initially scattered on the trunk and lately disseminated all over the body with less lesions on the lower extremities. At one of follow-up visits, he presented with high fever, pain with tumefaction of the small and medium size joints of the palms and soles, and deteriorated general status with polymorphous skin lesions. Based on the clinical and paraclinical features, the diagnosis of steatocystoma multiplex generalisata partially suppurativa was made. He was treated with oral isotretinoin (1 mg/kg *per day*) for 14 weeks, antibiotics and local treatments. The lesions healed slowly, with local disfigurement, hyperpigmentation and unpleasant scars. Isotretinoin usually does not eradicate the condition but could be effective in suppurative abscesses. Steatocystoma multiplex generalisata is considered rare; the true incidence of the disease is unknown. In the disease evolution, the severe inflammatory variant, steatocystoma multiplex suppurativa, may appear at any time.

**KEY WORDS:** steatocystoma multiplex, autosomal dominant inherited disorder, isotretinoin

### INTRODUCTION

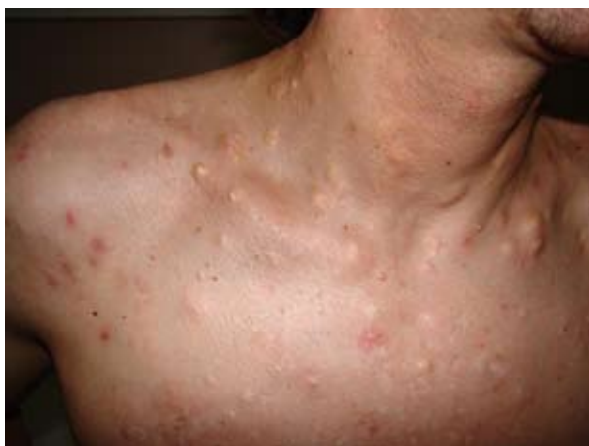First described by Jamieson in 1873, and coined by Pringle in 1899, steatocystoma multiplex is an uncommon and rare disorder of the pilosebaceous unit characterized by the development of numer-

ous sebum-containing dermal cysts. Although the disease has historically been described as an autosomal dominant inherited disorder, most presenting cases are sporadic (1,2). Steatocystoma



**Figure 1.** Lesions on the face

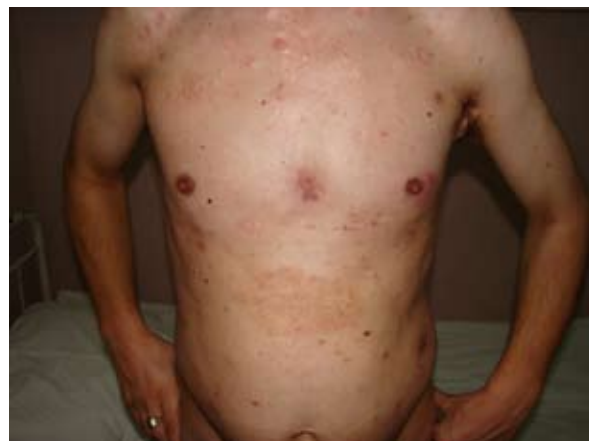multiplex is a benign disorder, but in some patients the severe inflammatory variant, *steatocystoma multiplex suppurativa*, may appear. In such cases, secondary bacterial colonization often leads to malodorous discharge. These lesions could heal with local disfigurement or with the appearance of cosmetically unpleasant scars.



**Figure 2.** Lesions on the upper chest and neck

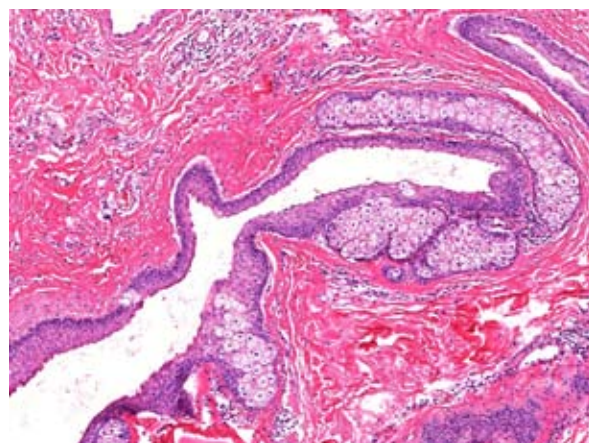
### CASE REPORT

A 27-year-old male patient, under our observation for five years, had been presenting since the age of 8 with multiple, asymptomatic, round-to-oval, well-defined, smooth-surfaced, yellow to skin-colored, 5- to 22-mm diameter cysts and nodules initially scattered on the trunk and lately disseminated all over the body, with less lesions on the lower extremities (Figs. 1 and 2). Hyperpigmented, smooth, shiny plaques were also present on the upper back. There were no nail changes. We also found a giant *café au lait* plaque situated centrally on the abdominal region and more than

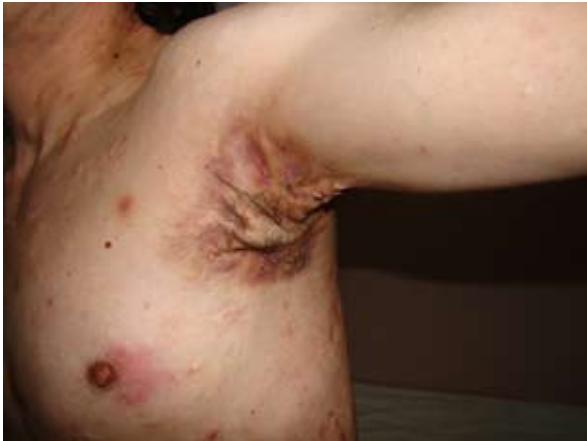

**Figure 3.** Lesions on the trunk, *café au lait* spot and naevi

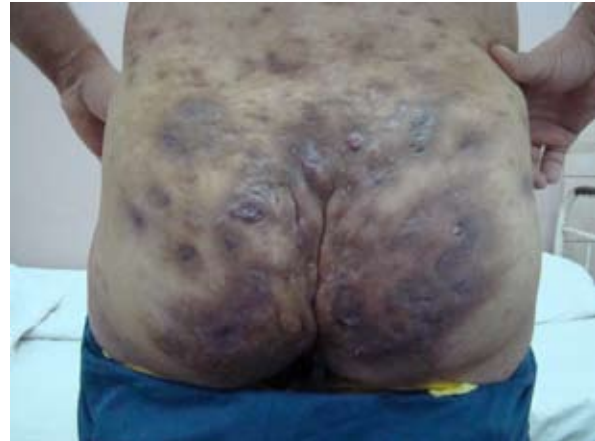30 junctional and compound nevi too (Fig. 3). Apart from the unpleasant cosmetic impact, the patient had no other significant clinical symptoms. His medical history was unremarkable. The results of routine laboratory testing like hematology and biochemistry were within the normal limits. Histologic examination showed dermal cysts with lobules of sebaceous glands within the cyst wall (Fig. 4). The diagnosis was *steatocystoma multiplex generalisata*. There was no family history of similar lesions, so we considered the patient a sporadic case. We suggested regular clinical observations. Four months ago, at one of his follow up visits, he presented with high fever, pain with tumefaction of the small and medium size joints of the palms and soles, and deteriorated general status. Dermatologic examination showed multiple ruptured draining cysts, inflammation and abscesses with purulent secretion situated axillary on the left side and on a large area on the sacrogluteal region appear-



**Figure 4.** Histologic aspect, H&E, 20X



**Figure 5.** Steatocystoma multiplex generalisata suppurativa - hidradenitis-suppurativa-like axillary on left side



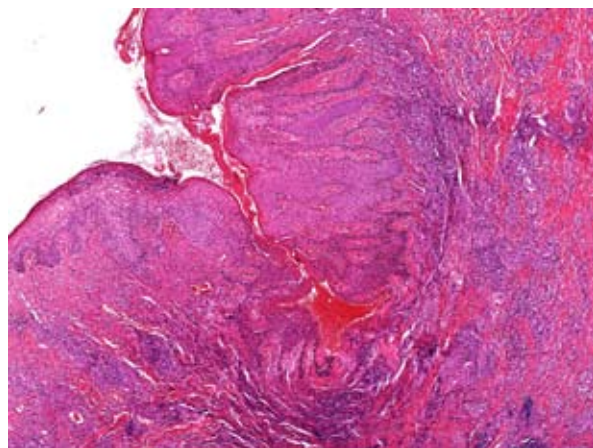
**Figure 6.** Steatocystoma multiplex suppurativa - acne conglobata like

ing like hidradenitis suppurativa (Fig. 5) and acne conglobata (Fig. 6). The rest of the lesions were intact. Laboratory results showed elevated inflammatory parameters with marked leukocytosis. Bacteriology pointed to *Staphylococcus aureus* superinfection. Histologic examination of these inflamed lesions showed granulomatous inflammation with lymphocyte infiltration and necrosis (Fig. 7). The diagnosis of steatocystoma multiplex generalisata partially suppurativa was made. The patient was treated with oral isotretinoin (1 mg/kg daily) for 14 weeks and antibiotics. Based on the antibiotic sensitivity report, a combination of cefuroxime and gentamicin was administered for 14 days. At the same time, topical antiseptics, anti-inflammatory agents and antibiotics were applied. Cryotherapy was used for small, non-suppurating lesions. The lesions healed slowly, with local disfigurement, hyperpigmentation and unpleasant scars. At the time of writing this report, the patient is on therapy with oral isotretinoin 0.5 mg/kg daily.

## DISCUSSION

Steatocystoma multiplex is a benign disorder. In some patients, it may have psychosocial implications resulting from disfigurement due to widespread lesions or from scarring seen in the inflammatory variant, steatocystoma suppurativa. Both sexes are equally affected and no racial predilection has been found. Usually the onset tends to occur during adolescence or early adult life. Cases of steatocystoma multiplex presenting at birth have been reported, and sporadic forms of steatocystoma multiplex with presentation in the elderly have also been described. Once present, steatocystoma multiplex is a lifelong condition (6).

Clinically, the lesions present as numerous flesh-to-yellow colored dermal cysts ranging in size from 3 mm to 3 cm. The cysts are usually nontender and asymptomatic. Symptoms like pain, pruritus and fever may occur in the suppurative clinical form (3). This clinical form occurs rarely in the disease development. The severe infection that occurred in our case may have been due to his low socioeconomic status and noncompliance. Individual cysts range from elastic to firm and are often freely movable. The lesions lack central punctum. The cyst content appears as an odorless creamy or oily fluid. Nail changes like hypertrophic dystrophy occur in most cases but were missing in our patient. Histopathology shows well encapsulated cysts in the middle dermis. Sebaceous cells or gland lobules are found consistently within or close to the cyst wall (4). Individual lesions of steatocystoma multiplex may become suppurative, increase in size, and become prone to rup-



**Figure 7.** Histologic aspect, inflammation, necrosis, H&E, 20X



ture. In typical cases of steatocystoma multiplex, cysts are distributed in areas where high numbers of sebaceous glands are found, most commonly on the chest, face, arms, axillae, and neck. There are reports on localized steatocystoma multiplex limited to the scalp (5,6), face (7), retroauricular region, groin, and nasal region (8). Additionally, rare clinical forms like facial papular (9), acral (10), acral nodular (11) and vulvar (12) form have been reported. Linear variants have been reported and, although rare, generalized eruptions may occur (13-15). Another rare clinical form is steatocystoma simplex which is the sporadic solitary tumor counterpart to steatocystoma multiplex. Steatocystoma multiplex occurs either as a sporadic or autosomal dominant inherited condition characterized by benign sebaceous gland tumors. Lesions consist of nevoid formation of abortive hair follicles at the site where sebaceous glands are attached. Electron microscopy studies demonstrate cyst wall cells undergoing trichilemmal keratinization similar to that of the isthmus portion of the outer hair sheath. The relationship of steatocystoma multiplex to the development of sebaceous glands and common presentation at puberty suggest a hormonal trigger for lesion growth. In the familial form of steatocystoma multiplex, mutations are localized to the keratin 17 (*K17*) gene in areas identical to mutations found in patients with pachyonychia congenita type 2 (PC-2) (16). Pachyonychia congenita type 2, an autosomal dominant inherited disorder, is characterized by hypertrophic nail dystrophy, focal keratoderma, multiple pilosebaceous cysts, and a variety of conditions associated with ectodermal dysplasia. Keratin 17 is expressed in several epithelial structures, most notably in sebaceous glands, the outer root sheath of hair follicles, and the nail bed; its expression correlates well with clinical phenotypic expression of both steatocystoma multiplex and pachyonychia congenita type 2 (17). To date, 14 mutations have been described in patients with either steatocystoma multiplex or pachyonychia congenita type 2, all of which are localized to the helix initiation domain (1A domain) of the *K17* gene (18). Some authors propose that steatocystoma multiplex is simply a variant of pachyonychia congenita type 2 because they both share the same underlying etiology (19). Sporadic forms of steatocystoma multiplex have not been shown to be associated with *K17* mutations. Based on the clinical features and absence of nail changes, we consider that our case is the product of a sporadic mutation. We cannot predict which gene is most likely responsible in this

case. However, the causative gene should be examined in the future. In previous reports, specific mutations were attributed to early-onset cyst formation in pachyonychia congenita type 2 and steatocystoma multiplex; however, more recent reports suggest that the age at onset is multifactorial (20). Steatocystoma multiplex is often associated with eruptive vellus hair cysts. Both diseases share overlapping clinical features, including age at onset, location, appearance of lesions, and mode of inheritance. There are reports of hybrid lesions showing histologic features of both steatocystoma multiplex and eruptive vellus hair cysts. Given these similarities, some postulate that steatocystoma multiplex and eruptive vellus hair cysts are, in fact, variants of the same disease. However, major differences in keratin expression patterns between steatocystoma multiplex and eruptive vellus hair cysts have been elucidated, leading others to believe that these are two distinct disease entities. In steatocystoma multiplex associated with eruptive vellus hair cyst, no *K17* mutation has been found. The disease was rarely associated with other diseases like trichoblastoma (21), familial syringoma (22), LEOPARD syndrome (23), hyperelastic skin, spherulocystic disease or "mysospherulosis" (24), multiple pilar cyst, acrokeratosis verruciformis, hypertrophic lichen planus, hypohidrosis, hidradenitis suppurativa, and natal teeth (25,26). Steatocystoma multiplex is included in the differential diagnoses of lipoma, fat necrosis, galactocoele, epidermal cyst, lipomatosis, xanthomatosis, and other benign tumors. Suppurative steatocystoma multiplex must be differentiated of severe nodulocystic acne, acne conglobata, infected fibroadenoma and other pyodermas (27). The treatments applied were inefficient or resulted in unsightly scarring. Lesions that are not inflamed and few are most successfully treated with surgical excision or drainage (28-30). Needle aspiration may reduce the size of lesions for a period of months (31). The number and extent of lesions usually preclude surgical excision. CO<sub>2</sub> laser therapy can be used in limited numbers of lesions (32,33). Inflamed lesions can be injected with intralesional glucocorticoids, or incised and drained (34). Isotretinoin usually does not eradicate the condition but may be used to decrease the size of suppurative lesions (35). Limited success has been reported with the use of both oral retinoids and liquid nitrogen cryotherapy in the treatment of suppurative lesions (36-38).

In conclusion, steatocystoma multiplex is an uncommon, mostly autosomal dominant or sporadic

inherited disorder of the pilosebaceous unit. Steatocystoma multiplex generalisata is considered rare, the true incidence of the disease is unknown. In the disease evolution, the severe inflammatory variant named steatocystoma multiplex suppurativa may occur at any time. Isotretinoin usually does not eradicate the condition but could be effective in suppurative abscesses.

## References

1. Kaur T, Kanwar AJ. Steatocystoma multiplex in four successive generations. *J Dermatol* 2003; 30:559-61.
2. Punia RP, Samra SG, Mohan H. Steatocystoma multiplex: a report of two sporadic cases. *Indian J Pathol Microbiol* 2007; 50:824-6.
3. Adams B, Shwayder T. Steatocystoma multiplex suppurativum. *Int J Dermatol* 2008; 47:1155-6.
4. Cho S, Chang SE, Choi JH, Sung KJ, Moon KC, Koh JK. Clinical and histologic features of 64 cases of steatocystoma multiplex. *J Dermatol* 2002; 29:152-6.
5. Jeong SY, Kim JH, Seo SH, Son SW, Kim IH. Giant steatocystoma multiplex limited to the scalp. *Clin Exp Dermatol* 2009 May 18. [Epub ahead of print]
6. Marley WM, Buntin DM, Chesney TM. Steatocystoma multiplex limited to the scalp. *Arch Dermatol* 1981;117:673-4.
7. Ahn SK, Hwang SM, Lee SH, Lee WS. Steatocystoma multiplex localized only in the face. *Int J Dermatol* 1997; 36:372-3.
8. Mortazavi H, Taheri A, Mansoori P, Kani ZA. Localized forms of steatocystoma multiplex: case report and review of the literature. *Dermatol Online J* 2005; 11:22
9. Nishimura M, Kohda H, Urabe A. Steatocystoma multiplex. A facial papular variant. *Arch Dermatol* 1986;122:205-7.
10. Rollins T, Levin RM, Heymann WR. Acral steatocystoma multiplex. *J Am Acad Dermatol* 2000; 43(2 Pt 2):396-9.
11. Yanagi T, Matsumura T. Steatocystoma multiplex presenting as acral subcutaneous nodules. *Acta Derm Venereol* 2006;86:374-5.
12. Rongioletti F, Cattarini G, Romanelli P. Late onset vulvar steatocystoma multiplex. *Clin Exp Dermatol* 2002;27:445-7.
13. De Almeida HL Jr, Basso P. Linear unilateral steatocystoma multiplex. *J Eur Acad Dermatol Venereol* 2009; 23:213-4.
14. D'Souza P, Joshi A, Gujral S, Ramam M. Linear steatocystoma multiplex. *Acta Derm Venereol* 1997; 77:161.
15. Park YM, Cho SH, Kang H. Congenital linear steatocystoma multiplex of the nose. *Pediatr Dermatol* 2000; 17:136-8.
16. Kurokawa I, Nishijima S, Kusumoto K, Senzaki H, Shikata N, Tsubura A. Cytokeratin expression in steatocystoma multiplex. *Br J Dermatol* 2002; 146:534-6.
17. Kim JU, Nogita T, Terajima S, Kawashima M. Pachyonychia congenita associated with steatocystoma multiplex. *J Dermatol* 1998; 25:479-81.
18. Covello SP, Smith FJ, Sillevs Smitt JH, Paller AS, Munro CS, Jonkman MF, *et al.* Keratin 17 mutations cause either steatocystoma multiplex or pachyonychia congenita type 2. *Br J Dermatol* 1998; 139:475-80.
19. Giustini S, Amorosi B, Canci C, Camplone G, Bottoni U, Porciello R, *et al.* Pachyonychia congenita with steatocystoma multiplex. A report of two cases and a discussion of the classification. *Eur J Dermatol* 1998; 8:158-60.
20. Kubota T. Pachyonychia congenita-steatocystoma multiplex. *Ryoikibetsu Shokogun Shirizu* 2001;(34 Pt 2):459-60.
21. Gianotti R, Cavicchini S, Alessi E. Simultaneous occurrence of multiple trichoblastomas and steatocystoma multiplex. *Am J Dermatopathol* 1997; 19:294-8.
22. Marzano AV, Fiorani R, Girgenti V, Crosti C, Alessi E. Familial syringoma: report of two cases with a published work review and the unique association with steatocystoma multiplex. *J Dermatol* 2009; 36:154-8.
23. Mochizuki-Osawa M, Terui T, Kato T, Tagami H. LEOPARD syndrome associated with steatocystoma multiplex and hyperelastic skin. Report of a Japanese case. *Acta Derm Venereol* 1995; 75:323-4.
24. Patterson JW, Kannon GA. Spherulocystic disease ("mysospherulosis") arising in a lesion of steatocystoma multiplex. *J Am Acad Dermatol* 1998; 38(2 Pt 1):274-5.
25. Sardana K, Sharma RC, Jain A, Mahajan S. Facial steatocystoma multiplex associated

- with pilar cyst and bilateral preauricular sinus. *J Dermatol* 2002; 29:157-9.
26. Yamada A, Saga K, Jimbow K. Acquired multiple pilosebaceous cysts on the face having the histopathological features of steatocystoma multiplex and eruptive vellus hair cysts. *Int J Dermatol* 2005; 44:861-3.
27. Beyer AV, Vossman D. Steatocystoma multiplex. *Hautarzt* 1996; 47:469-71.
28. Kaya TI, Ikizoglu G, Kakturk A, Tursen U. A simple surgical technique for the treatment of steatocystoma multiplex. *Int J Dermatol* 2001; 40:785-8.
29. Keefe M, Leppard BJ, Royle G. Successful treatment of steatocystoma multiplex by simple surgery. *Br J Dermatol* 1992;127:41-4.
30. Madan V, August PJ. Perforation and extirpation of steatocystoma multiplex. *Int J Dermatol* 2009; 48:329-30.
31. Sato K, Shibuya K, Taguchi H, Kitano Y, Yoshikawa K. Aspiration therapy in steatocystoma multiplex. *Arch Dermatol* 1993; 129:35-7.
32. Krahenbuhl A, Eichmann A, Pfaltz M. CO<sub>2</sub>-laser therapy for steatocystoma multiplex. *Dermatologica* 1991;183:294-6.
33. Rossi R, Cappugi P, Battini M, Mavilia L, Campolmi P. CO<sub>2</sub> laser therapy in a case of steatocystoma multiplex with prominent nodules on the face and neck. *Int J Dermatol* 2003; 42:302-4.
34. Schmook T, Burg G, Hafner J. Surgical Pearl: mini-incisions for the extraction of steatocystoma multiplex. *J Am Acad Dermatol* 2001; 44:1041-2.
35. Friedman SJ. Treatment of steatocystoma multiplex and pseudofolliculitis barbae with isotretinoin. *Cutis* 1987;39:506-7.
36. Apaydin R, Bilen N, Bayramgürler D, Başdaş F, Harova G, Dökmeci S. Steatocystoma multiplex suppurativum: oral isotretinoin treatment combined with cryotherapy. *Australas J Dermatol* 2000; 41:98-100.
37. Düzova AN, Sentürk GB. Suggestion for the treatment of steatocystoma multiplex located exclusively on the face. *Int J Dermatol* 2004; 43:60-2.
38. Chu DH. Steatocystoma multiplex. *Dermatol Online J* 2003; 9:18.

#### ERRATUM CORRIGE

In the article Rogošić V, et al. Vitiligo and Glaucoma - An Association or a Coincidence, published in *Acta Dermatovenerol Croat* 2010;18(1):21-26 by technical error made by author instead of name of co-author Davor Mendeš it was written Damir Sapunar.

With my apologies, Veljko Rogošić, MD, PhD