

Biopsy Proven Morphea Treated with Tacalcitol Ointment: Case Report

**Antonio Ascari-Raccagni^{1,2}, Adina Dondas³, Alessandra Dubini⁴,
Maria Giovanna Righini¹, Giusto Trevisan³**

¹Dermatological Surgery Unit, Department of Dermatology, GB Morgagni - L. Pierantoni General Hospital, Forli; ²Master in Dermatological Surgery, University of Siena, Siena; ³Institute of Dermatology, University of Trieste, Trieste; ⁴Department of Pathology, GB Morgagni - L. Pierantoni General Hospital, Forli; Italy

Corresponding author:

Antonio Ascari-Raccagni, MD
Dermatological Surgery Unit,
Department of Dermatology
GB Morgagni - L. Pierantoni General Hospital
via Forlanini 34
I-47121 Forli
Italy
ascrac@libero.it

Received: December 14, 2009

Accepted: October 11, 2010

SUMMARY A 43-year-old woman presented with a widespread morphea, which had its onset three months before. The patient had several plaques of active, pigmented, lilac halo disease on the trunk, arms and thighs. A biopsy confirmed that the patient was suffering from morphea. Therapy with clobetasol propionate ointment 0.05% was introduced, applied twice a day, 5 days a week. After a month, the ointment failed to significantly improve the lesions. Then the patient was treated with clobetasol ointment in the morning and tacalcitol ointment 4 mcg/g in the evening. This combination resulted in marked improvement of the disease after 20 days of therapy, and we decided to stop topical steroid. After three months of treatment with topical tacalcitol once a day, the plaques regressed considerably and only a very slight pigmentation remained. Therapy was further reduced to one evening, every other day for six months more, and then was suspended completely. No side effects were observed and there was no recurrence at 24-month follow up.

KEY WORDS: tacalcitol, fibroblast, morphea, vitamin D3 analogues

INTRODUCTION

Morphea is a localized type of scleroderma characterized by circumscribed fibrotic plaques. At onset, it is manifested as erythematous patches that become either yellow-white or ivory colored, surrounded by a purple-like or lilac halo that implies an early, inflammatory phase of the disease. Atrophy of the pilosebaceous units and subcutaneous tissue produces waxy, ivory colored, hardened patches, which can eventually become atrophic, with residual areas of hypo- or hyperpigmentation (1). Morphea can affect either single or

multiple areas on the trunk or extremities, with the face generally being spared.

The pathophysiological mechanism of morphea is still unknown, but alteration in the local immune function as much as collagen synthesis and endothelial cell proliferation have been noticed (2).

There are many *in vitro* and *in vivo* studies investigating the effects of the synthetic forms of vitamin D3 on immunoregulation, fibroblast growth, synthesis and deposition of collagen, which pro-

vide a strong rationale for the treatment of cutaneous sclerosis with synthetic forms of vitamin D3, either by topical or oral administration (3-7). We think that topically applied tacalcitol can be an effective, good and tolerable therapy for patients affected by morphea.

We report a case of a 43-year-old woman with a three-month history of widespread morphea that failed to improve with topical steroid therapy but was successfully treated with tacalcitol ointment.

CASE REPORT

A 43-year-old woman was referred to our department for the management of morphea. The onset of the disease had occurred three months before and the patient showed more than ten plaques on her trunk, arms and thighs. The patient lived in a Lyme disease area but did not remember a tick bite. In childhood, she had been affected by celiac syndrome, controlled by following a gluten-free diet.

Clinical examination revealed atrophic, hyperpigmented, telangiectatic plaques, with no tendency to become confluent or cause joint contractures (Fig. 1). Histology showed thickened collagen bundles with fibrosis, mainly in reticular dermis, fibrosis of adnexal structures, and a moderately severe inflammatory infiltration between collagen bundles and around blood vessels. Collagen fibers

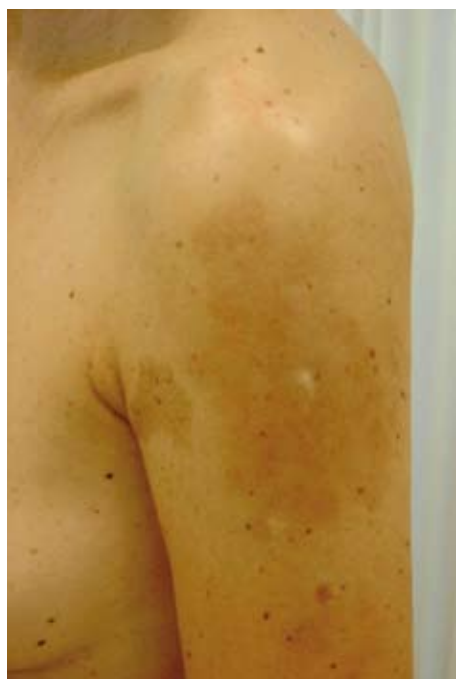

Figure 1. Atrophic, hyperpigmented, telangiectatic plaques on the left arm.

were uniform in appearance running parallel with the skin surface. There was also some pigmentation in the epidermis (Fig. 2).

The clinical and histologic features were consistent with the diagnosis of widespread morphea. Complete blood count, erythrocyte sedimentation rate, anti-nuclear antibodies, IgG and IgM anti-Borrelia burgdorferi were either normal or negative.

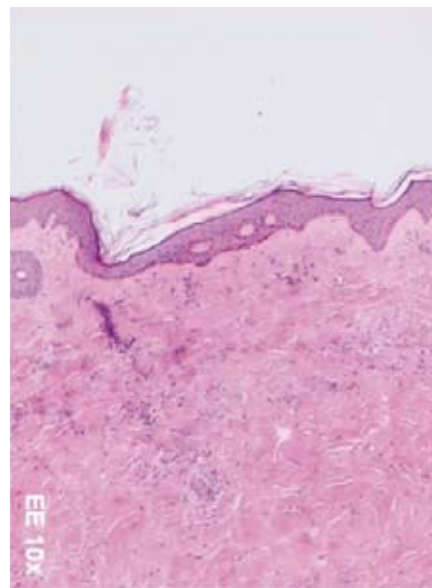


Figure 2. Thickened collagen bundles with fibrosis in reticular dermis; fibrosis of adnexal structures; a moderately severe inflammatory infiltrate between collagen bundles and around blood vessels. HE x 10

One-month treatment with clobetasol ointment 0.05% applied twice a day, 5 days a week failed to significantly improve the lesions. Topical steroid ointment was then reduced to a single application in the morning, while tacalcitol ointment 4 mcg/g was applied in the evening. Neither clobetasol nor tacalcitol ointment therapy was performed under occlusion. After twenty days, we observed significant improvement in the patient. The plaques had softened and telangiectasia had reduced to such an extent that we decided to suspend the treatment with clobetasol ointment.

After three months of monotherapy with topical tacalcitol applied once a day in the evening, the plaques had regressed considerably, leaving only a very slight pigmentation. Therapy was reduced to a single application every other evening, which was stopped completely six months later. Blood calcium and phosphate levels were normal. No local side effects such as burning, irritation or erythema were observed.

As no disease recurrence was found at 6-, 12- and 24-month clinical follow ups, therapy was discontinued (Fig. 3). The patient refused post treatment biopsy.

DISCUSSION

Many different therapies such as steroids, penicillin, D-penicillamine, cyclosporine, anti-malarial, interferon γ , PUVA, topical photodynamic therapy, tacrolimus and imiquimod have been recommended for the treatment of morphea (8-14).

The pathophysiological mechanism of the disease is still unknown, but there are many *in vitro* and *in vivo* studies investigating the effects of the synthetic forms of vitamin D3 on immunoregulation, fibroblast growth, synthesis and deposition of collagen, which provide a rationale for the treatment of cutaneous sclerosis with synthetic forms of vitamin D3.

Oral calcitriol has been successfully used to treat scleroderma and widespread morphea (15). Topical calcipotriene has been reported to improve morphea plaques by at least 40% (2). Topical calcipotriol was effective in the treatment of morphea in children (16).

We think that topically applied tacalcitol can be an effective, good and tolerable therapy for patients with morphea. We prescribed topical tacalcitol for our patient because of its high therapeutic impact, lack of local side effects, reduced system-

ic absorption, and the fact that it must be applied once a day. The latter point is of great importance when patients are treated for long periods.

In Europe, tacalcitol ointment is currently supplied in a 4 mcg/g concentration, making it possible for patients to apply it only once a day, even though the very first experiences with this drug were acquired by using a 2 mcg/g ointment that had to be applied twice a day.

CONCLUSION

Nowadays, topical steroids are the main choice of treatment for morphea. However, topical vitamin D analogues may be an effective and interesting alternative. To our knowledge, topical tacalcitol ointment has not been previously tested for the treatment of morphea, although the drug is well-tolerated, safe and easy to apply.

We treated a few cases of morphea with topical calcipotriol. In our opinion, tacalcitol ointment was as active as calcipotriol, if not more so, and initial improvements occurred a lot faster.

Many cases of morphea regress spontaneously, and a single patient is obviously not enough to confirm our hypothesis. However, we do feel that topical tacalcitol should be subjected to double-blind, placebo-controlled trials in order to confirm our clinical observations.

References

1. Vierra E, Cunningham BB. Morphea and localized scleroderma in children. *Semin Cutan Med Surg* 1999;18: 210-25.
2. Cunningham BB, Landells ID, Langman C, Sailer DE, Paller AS. Topical calcipotriene for morphea/linear scleroderma. *J Am Acad Dermatol* 1998;39:211-5.
3. Humbert PG, Dupond JL, Rochefort A, Vasselet R, Lucas A, Laurent R, *et al.* Localized scleroderma – response to 1,25-dihydroxyvitamin D3. *Clin Exp Dermatol* 1990;15:396-8.
4. Hulshof MM, Pavel S, Breedveld FC, Dijkmans BA, Vermeer BJ. Oral calcitriol as a new therapeutic modality for generalized morphea. *Arch Dermatol* 1994;130:1290-3.
5. Hulshof MM, Bouwes Bavinck JN, Bergman W, Masclee AA, Heickendorff L, Breedveld FC, *et al.* Double-blind, placebo-controlled study of oral calcitriol for the treatment of localized and systemic scleroderma. *J Am Acad Dermatol* 2000;43:1017-23.
6. Caca-Biljanovska NG, Vlckova-Laskoska MT, Dervendi DV, Pesic NP, Laskoski DS.

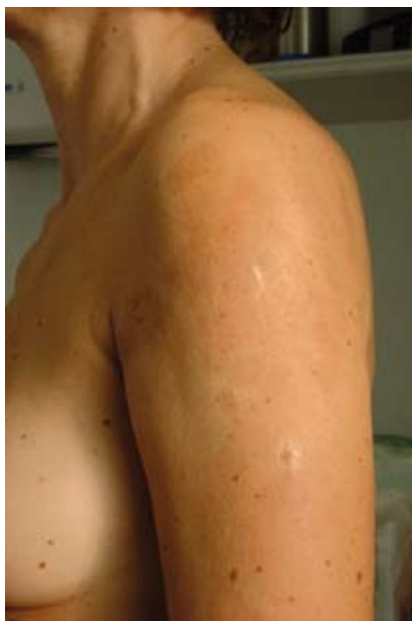
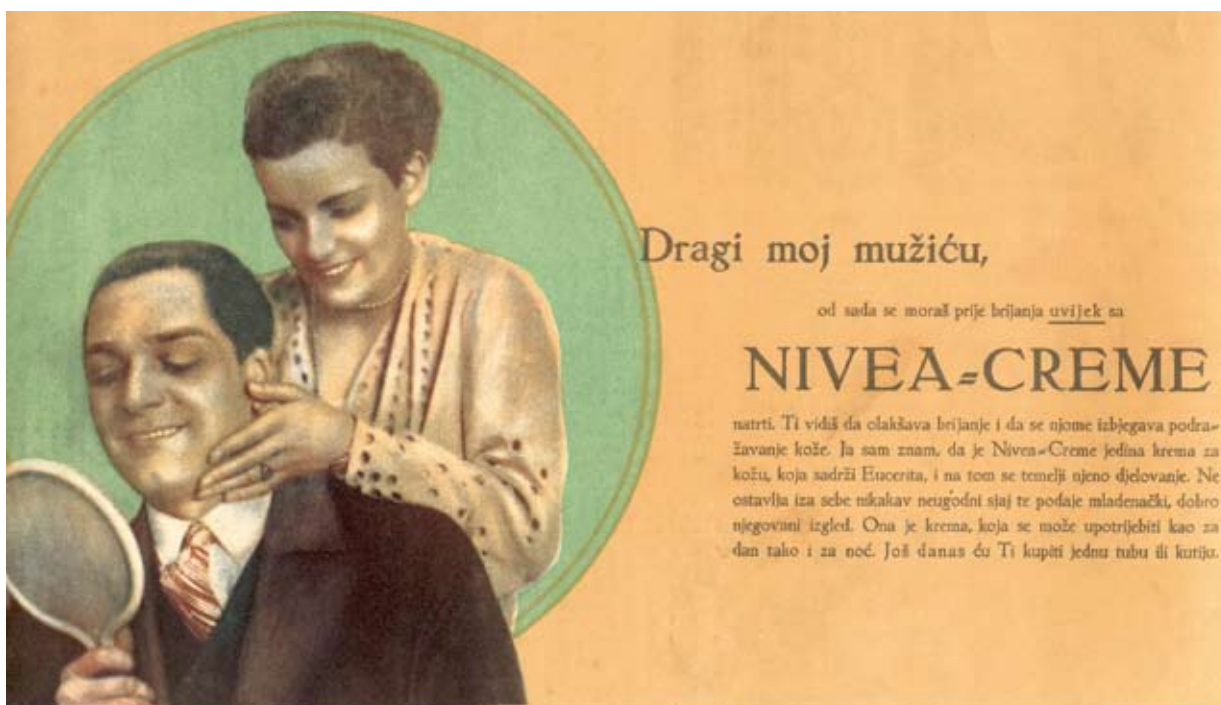
Figure 3. The condition after three months of treatment: plaque regression and slight pigmentation.

- Treatment of generalized morphea with oral 1,25-dihydroxyvitamin D3. *Adv Exp Med Biol* 1999;455:299-304.
7. Bottomley WW, Jutley J, Wood EJ, Goodfield MD. The effect of calcipotriol on lesional fibroblasts from patients with active morphoea. *Acta Derm Venerol* 1995;75:364-6.
 8. Jablonska S, Blaszczyk M. Scleroderma and sclerotic skin conditions: unapproved treatments. *Clin Dermatol* 2002;20:634-7.
 9. Mancuso G, Berdondini RM. Topical tacrolimus in the treatment of localized scleroderma. *Eur J Dermatol* 2003;13:590-2.
 10. Dytoc MT, Kossintseva I, Ting PT. First case series on the use of calcipotriol-betamethasone dipropionate for morphoea. *Br J Dermatol* 2007;157:615-8.
 11. Gambichler T, Kreuter A, Rotterdam S, Altmeyer P, Hoffmann K. Linear scleroderma 'en coup de sabre' treated with topical calcipotriol and cream psoralen plus ultraviolet A. *J Eur Acad Dermatol Venereol* 2003;17:601-2.
 12. Kreuter A, Gambichler T, Avermaete A, Jansen T, Hoffmann M, Hoffmann K, *et al.* Combined treatment with calcipotriol ointment and low-dose ultraviolet A1 phototherapy in childhood morphea. *Pediatr Dermatol* 2001;18:241-5.
 13. Man J, Dytoc MT. Use of imiquimod cream 5% in the treatment of localized morphea. *J Cutan Med Surg* 2004;8:166-9.
 14. Babilas P, Landthaler M, Szeimies RM. Photodynamic therapy in dermatology. *Eur J Dermatol* 2006;16:340-8.
 15. Piraccini BM, Vincenzi C, Lorenzi S. Oral calcitriol in the treatment of sclerodermia 'en coupe de sabre'. *J Dermatol Treat* 2000;11:207-8.
 16. Tay YK. Topical calcipotriol ointment in the treatment of morphea. *J Dermatol Treat* 2003;14:219-21.



My dear husband, from now after raising you have to use Nivea cream; year 1935.
(From the collection of Mr. Zlatko Puntijar)