

## Dermatitis Artefacta in a Patient Affected by Impulse Control Disorder: Case Report

Concetta Potenza<sup>1</sup>, Nicoletta Bernardini<sup>1</sup>, Alessandra Mambrin<sup>1</sup>, Nevena Skroza<sup>1</sup>

<sup>1</sup>UOC of Dermatology "Daniele Innocenzi", Sapienza University of Rome, Polo Pontino, Italy

### Corresponding author:

Assist. Prof. Nevena Skroza, MD  
UOC of Dermatology "Daniele Innocenzi"  
Sapienza University of Rome  
Polo Pontino  
Via Firenze snc, Terracina (LT)  
Italy  
[nevena.skroza@uniroma1.it](mailto:nevena.skroza@uniroma1.it)

Received: March 31, 2010

Accepted: December 27, 2010.

**SUMMARY** Dermatitis artefacta is a disease characterized by self-inflicted skin lesions in fully aware patients. Mechanical and chemical devices are most commonly used to produce such injuries. Several psychological disorders like depression, obsessive compulsive disorders, hysteria, etc. are associated with this kind of disease. Most of the patients are young females aged between 15 and 30, but the diagnosis of dermatitis artefacta may even be made in pediatric patients or elderly people. Because of its rarity and the polymorphism of lesions, dermatitis artefacta is often a challenge for the clinicians. More difficulties might be due to the lack of cooperation in these patients, who usually refuse the dialogue with doctors and deny their primary role in damaging their skin. We present a case of an elderly woman who showed a peculiar pattern of deep excoriating lesions disseminated on the upper part of her body, with an evident state of depression. Diagnostic and therapeutic procedure, that is often long lasting and difficult in such cases, was made by teamwork of dermatologists, psychiatrists and psychologists, leading to steady control of impulses and full remission of cutaneous symptoms.

**KEY WORDS:** dermatitis artefacta, factitial dermatoses, pathomimicry, impulse control disorder, skin picking

### INTRODUCTION

Dermatitis artefacta is an artefactual disease caused entirely by the fully aware (not conscious impaired) patient on skin, hair, nails or mucosa (1). The lesions appear as wounds or scars of different size and shape, from linear to polygonal or geometric, depending on the methods used to injure the skin. Sometimes it is hard to distinguish dermatitis artefacta from natural diseases, but figure in the complex cannot almost never be attributed to any spontaneous dermatosis (2,3). Lesions may be produced by a variety of mechanical or chemical means, including

fingernails, sharp or blunt objects, lit cigarettes and caustic chemicals. When injuries are multiple, as usual, the interlesional skin seems perfectly healthy, while histologic examination of the scarred areas shows almost invariably aspecific inflammation patterns.

Self-destructive conducts in these patients occur as the result or manifestation of a psychological problem. Many patients suffer from depression, anxiety and personality disorders, or have a past history of somatizing illness like pseudo-seizures, abdominal pain or chronic fatigue (4,5). Women are more af-

ected than men; maximum incidence is between the second and third decade of life (6), although clinical cases of pediatric or elderly patients are by no means infrequently reported (7,8).

### CASE REPORT

In April 2007, a 77-year-old Caucasian woman came for observation accompanied by her daughter. Cutaneous examination showed numerous linear, sharply demarcated, deep ulcerations on the face, chest and especially on the right arm (Figs. 1-3). Wounds appeared in different evolutive stages: recent ones were exudative and erythematous, while older ones, in resolution, appeared dark and covered by crusts. The speaking ability of this patient was reduced, with evident psychomotor inhibition. History data were obtained with the help of her daughter, who reported that her mother had been living in solitude for several years, falling in depressive state. Routine laboratory data were within the normal ranges. Skin biopsy was obtained for histopathologic examination, which revealed ulceration with unspecific signs of inflammation (Fig 4). Given the atypical and bizarre distribution of the lesions (the patient was left handed and the cuts were all located in the areas easily reachable by her left hand, such as face, chest and especially the right arm), not resembling any known dermatosis. Based on the aspecific histologic examination and particular psychosocial conditions, we made the diagnosis of dermatitis artefacta. Skin lesions were covered by occlusive bandages and started improving in several days.

Anyway, the patient was referred to Department of Psychiatry of our hospital for assessment and treatment of her mental disorder. The psychiatric report revealed a mild depressive state with impulse control disorder (ICD). During meetings with the psychologist and the psychiatrist, the patient admitted without reluctance to have self-inflicted the wounds because of unbearable itching in several areas of her body. This symptom was unleashed by anxiety and discomfort related to her inner experience; in effect, she revealed as her family and children had never given her the attention she needed. The patient was then treated with citalopram 30 mg/day.

In June 2007, after 2 months of pharmacological treatment and psychiatric and dermatologic follow up, the woman showed significant improvement in the tone of humor, in the control of impulses, and complete remission of skin lesions.

### DISCUSSION

Dermatitis artefacta should be considered as a dermatologic manifestation of an underlying psycholog-

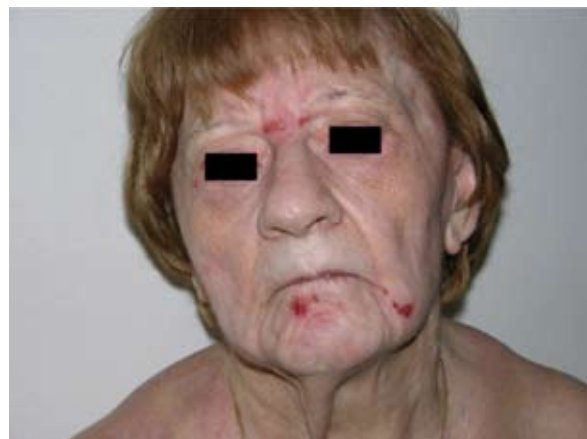

Figure 1. Face cutaneous ulcerations in our patient.

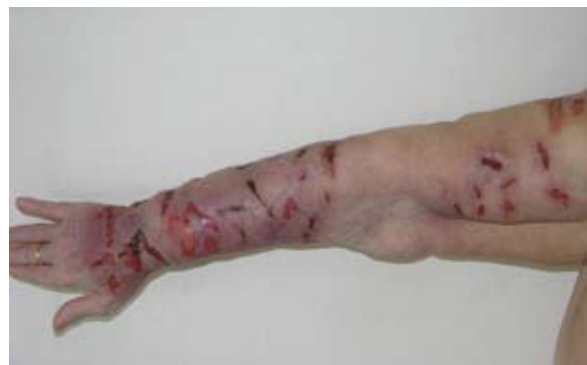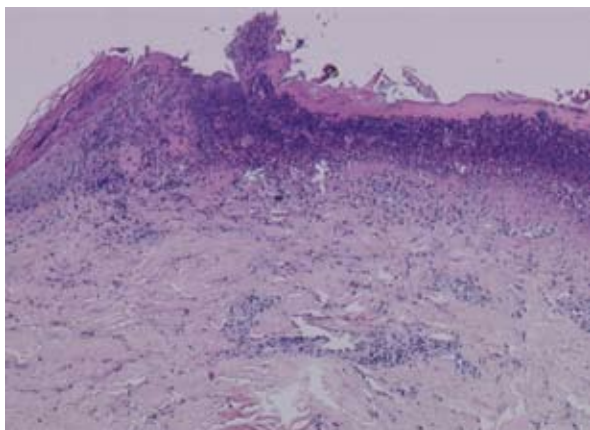


Figure 2. Deep ulcerations on right arm.

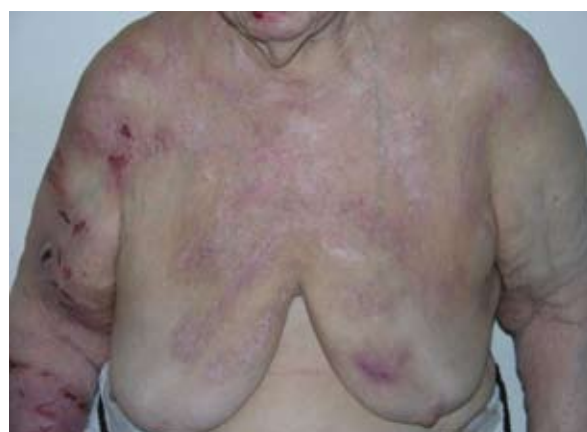

Figure 3. Deep ulcerations on brachial part of right arm.

ical problem. Women are most affected, as happens in other psychiatric pathologies related to dermatitis artefacta, such as depression, obsessive compulsive



**Figure 4.** Unspecific histopathologic signs of inflammation (HE; x100)

disorder, etc. The patients are often hardly cooperating and tend to deny their self-destructive behavior. This may complicate the diagnosis and management of the disease. Therefore, the diagnosis is made after excluding all possible spontaneous dermatoses that may be involved in differential diagnosis. The localization of injuries in somatic regions easily reachable by dominant hand, sudden appearance, unusual geometric form and patient indifference toward his/her clinical signs may help the dermatologist discover the real origin of the disease.

Much has been written about the motivation of these patients to assume the sick role. In many cases, dermatitis artefacta is interpreted as the need of attention, a "cry for help" (1), which the subject is not able to express in other ways. However, not all dermatitis artefacta cases are self-induced in order to get the so-called primary gain: this means that the subjects may follow a self-destructive conduct either because driven by erroneous ideas (as in case of psychotic patients that feel the presence of insects under their skin), or by a sensorial stimulus (as in our patient affected by ICD, who experienced irresistible itching). Impulse control disorder can be loosely defined as a failure to resist an impulsive act or behavior that may be harmful to self or others (9). Psychiatrist work consists in trying to identify the deeper psychological disorder and its causal link with the skin lesions. A direct approach aimed to unmask the origin of the injuries is not recommended because the patient usually reacts by denying and interrupting communication

with the doctor. In the case reported, the patient not only admitted almost immediately to have inflicted the wounds herself, but also provided a rational explanation of her scratching.

## CONCLUSION

Fortunately, false dermatoses are rare pathologic conditions; however, it is important to consider them as the possible diagnostic options, bearing in mind how they can affect patients and their families and how much their diagnostic workup and therapy can be difficult and exhausting, and that it can be successful only when treated by team of specialists.

## References

1. Burns T, Breathnach S, Cox N, Griffiths C, eds. *Rook's Textbook of Dermatology*, 7<sup>th</sup> edn. Oxford: Blackwell Publishing Ltd.; 2004.
2. Koblenzer CS. Dermatitis artefacta. Clinical features and approaches to treatment. *Am J Clin Dermatol* 2000;1:47-55.
3. Verraes-Derancourt S, Derancourt C, Poot F, Heenen M, Bernard P. Dermatitis artefacta: retrospective study in 31 patients. *Ann Dermatol Venereol* 2006;133:235-8.
4. Gupta MA. Somatization disorders in dermatology. *Int Rev Psychiatry* 2006 ;18:41-7.
5. Ozmen M, Erdogan A, Aydemir EH, Oguz O. Dissociative identity disorder presenting as dermatitis artefacta. *Int J Dermatol* 2006;45:770-1.
6. Nielsen K, Jeppesen M, Simelsgaard L, Rasmussen M, Thestrup-Pedersen K. Self-inflicted skin diseases. A retrospective analysis of 57 patients with dermatitis artefacta seen in a dermatology department. *Acta Derm Venereol* 2005;85:512-5.
7. Shah KN, Fried RG. Factitial dermatoses in children. *Curr Opin Pediatr.* 2006;18:403-9.
8. Saez-de-Ocariz M, Orozco-Covarrubias L, Mora-Magana I, Duran-McKinster C, Tamayo-Sanchez L, Gutierrez-Castrellon P, *et al.* Dermatitis artefacta in pediatric patients: experience at the national institute. *Pediatr Dermatol* 2004;21:205-11.
9. American Psychiatric Association. *Diagnostic and Statistical Manual of Mental Disorders (DSM-IV)*, 4<sup>th</sup> edn. Washington, DC: American Psychiatric Association Publications Division, 2004.