

Effective Treatment of Linear Darier's Disease with Topical Retinoids: Case Report and Review of the Literature

Darier's disease is a rare genodermatosis caused by a defect in ATP2A2 gene located on chromosome 12q23-23 (1). This somatic mutation rarely occurs in the postzygotic phase of embryogenesis, leading to cutaneous mosaicism for the disease. The mosaic form of Darier's disease is also called linear Darier's disease and clinically presents with linear, zosteriform or localized patterns located on Blaschko's lines. A case of linear Darier's disease successfully treated with topical 0.1% tretinoin therapy is presented.

A 62-year-old male patient presented to dermatology department for scaly eruption on the back for over a month. The patient had undergone Whipple's operation (pancreatoduodenosplenectomy) for pancreatic adenocarcinoma 3 months before. Dermatologic examination revealed unilateral follicular hyperkeratotic papules in an oblique linear configuration over the patient's back. Some keratotic papules coalesced to form plaques, which were located on Blaschko's lines (Fig. 1).

The remaining dermatologic examination of the hair, nails and mucosa was unremarkable. A punch biopsy performed from one of the papules showed focal suprabasilar acantholysis accompanied by dyskeratotic keratinocytes both in the stratum spinosum and stratum corneum. Dyskeratotic cells in the stratum spinosum showed pyknotic nuclei and enlarged homogeneous eosinophilic cytoplasm, whereas basophilic elongated nuclei were observed in dyskeratotic cells of the stratum corneum (Fig. 2). They were consistent with corps ronds and grains previously described in dyskeratotic dermatoses and particularly in Darier's disease (2). With these histopathologic findings, the diagnosis of Darier's disease was made. The clinical presentation composed of localized plaques parallel to Blaschko's lines led to the definitive diagnosis of linear Darier's disease. Topical 0.1% tretinoin

twice daily was prescribed and total improvement was accomplished after a month (Fig. 3).

Darier's disease is a rare autosomal dominant genodermatosis which is caused by a defect in ATP2A2 gene on chromosome 12q23-23.1 (1). This gene's product is a protein which functions as a sarco/endoplasmic reticulum calcium pumping ATPase isoform 2 (SERCA2) and mutation of this protein leads to loosening of the cell-cell adhesions by causing defect in the formation or maturation of the tonofilament-desmosome complex (3). The disrupted adhesion results in separation of the cells contributing particular focal suprabasilar acantholysis and dyskeratosis in keratinocytes known as corps ronds and grains histopathologically (2). The clinical findings in Darier's disease include keratotic, crusted red-brownish papules distributed over the seboreic areas such as the trunk, scalp margins, face and lateral aspects of the face. The papules generally coalesce to form large verrucous plaques. Nearly half of the patients have flat, shiny warty papules on the dorsal aspects of the hands. Painless whitish papules may be observed in oral mucosa in 15% of patients (4). After reports of unilateral or zosteriform patterns in patients with Darier's disease, the synonyms acantholytic dyskeratotic epidermal nevi, segmental Darier's disease, linear Darier's disease and localized Darier's disease were started to be used for describing mainly the same localized clinical condition observed in Darier's disease (5-7). In fact, 10% of patients with Darier's disease are estimated to have linear or zosteriform pattern, localized on one-half of the body and linear Darier's disease is accepted as a mosaic form of Darier's disease (8,9).

The reported treatment regimens for this rare mosaic cutaneous disorder are few in the literature. Topically applied adapalene was found to be effective by Cassals *et al.* (10). Short contact 0.1% tazarotene gel

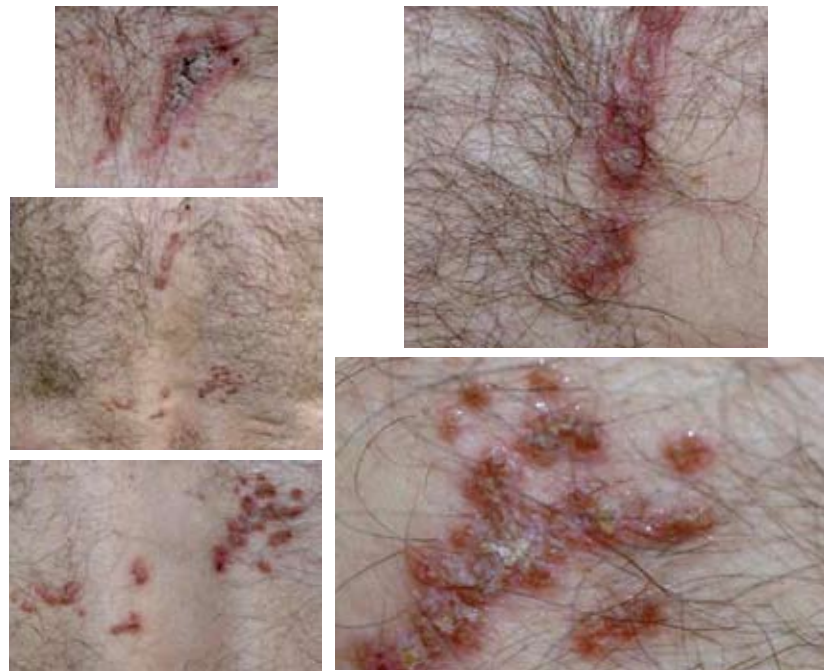

Figure 1. Hyperkeratotic papules in linear and zosteriform configurations located on Blaschko's lines over the back are seen on the left, and pinkish crusted papules seen on closer examination on the right.

for 6 weeks treated the disease successfully (3). In our experience, topically applied 0.1% tretinoin cream was also able to treat the lesions after twice a day application for 4 weeks.

Tretinoin, also known as all-*trans* retinoic acid, is the acid form of vitamin A. In fact, all-*trans* retinoic

acid is naturally formed by basal keratinocytes (11). Retinoids are believed to have antiproliferative effects on keratinocytes modulating keratinocyte differentiation, normalizing abnormal differentiation, and down-regulating epidermal growth factor receptors and hyperproliferative keratins. They bind to

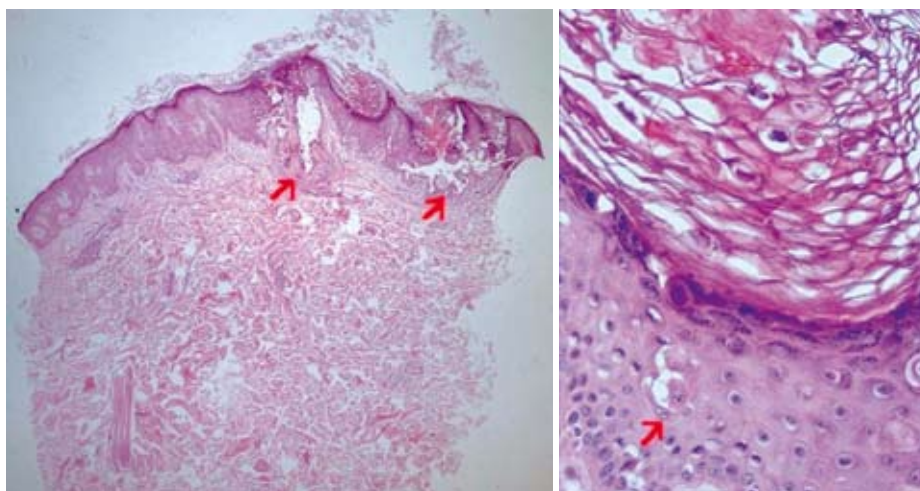


Figure 2. Focal suprabasilar acantholysis is indicated with arrows on the left; dyskeratotic cells in stratum spinosum with pyknotic nuclei and enlarged homogeneous eosinophilic cytoplasm (corps ronds) are indicated with arrows, and dyskeratotic cells with basophilic elongated nuclei (grains) within stratum corneum are indicated with a circle on the right. (H&E x20 and x40 magnifications)

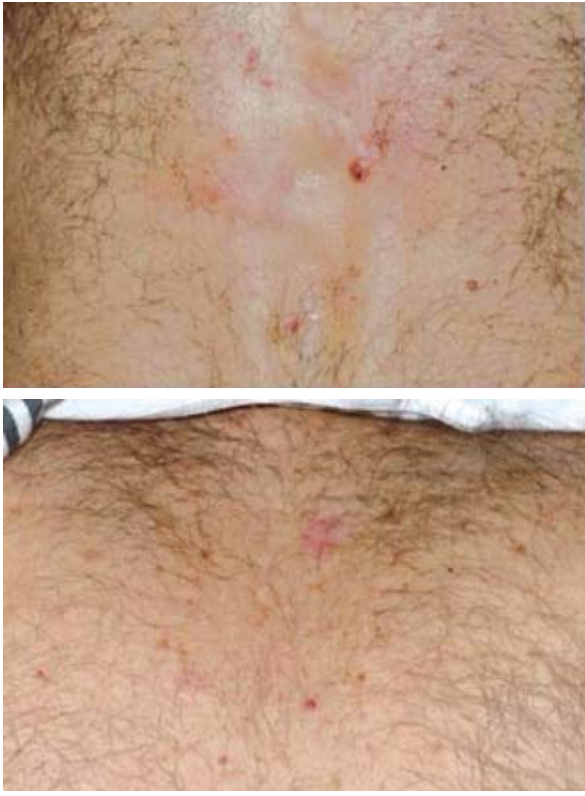

Figure 3. Total improvement of the lesions accomplished with 0.1% tretinoin cream after a month.

nuclear receptors RARs (retinoic acid receptors) or RXRs (retinoic X receptors) in cells and regulate gene expression by inhibiting transcription factors such as AP-1, which is a transcription complex controlling response to mitogenic injunctions (12). Retinoids also possess anti-inflammatory effects and they are shown to inhibit leukocytes, pro-inflammatory cytokine release and transcription factor expression (13). Topical retinoids are preferably used for localized cutaneous diseases for their low percutaneous absorption, rapid elimination and minor side effects. There are other local treatment options reported for Darier's disease including 5-FU, cryotherapy and photodynamic therapy, which obviously are not equally cost effective when compared to short-term topically applied retinoids (14,15).

Short periods of topically applied retinoids and retinoid analogues seem to be safe and effective for the treatment of linear Darier's disease, which is etiologically accepted as an inherited dyskeratotic mosaic cutaneous disorder.

References

1. Craddock N, Dawson E, Burge S, Parfitt L, Mant B, Roberts Q, *et al.* The gene for Darier's disease maps to chromosome 12q23-24.1. *Hum Mol Genet* 1993;2:1942-3.
2. Brazelli V, Prestinari F, Barbagallo T, Vassallo C, Agozzino M. Linear Darier's disease successfully treated with 0.1% tazarotene gel "short-contact" therapy. *Eur J Dermatol* 2006;16:59-61.
3. Munro CS, Cox NH. An acantholytic dyskeratotic epidermal nevus with other features of Darier's disease on the same part of the body. *Br J Dermatol* 1992;127:168-71.
4. Burge SM, Wilkinson JD. Darier-White disease: a review of the clinical features in 163 patients. *J Am Acad Dermatol* 1992;27:40-50.
5. Starink TM, Woerderman MJ. Unilateral systematized keratosis follicularis. A variant of Darier's disease or an epidermal naevus (acantholytic dyskeratotic epidermal naevus)? *Br J Dermatol* 1981;105:207-14.
6. Vakilzadeh F. Case demonstration: segmental follicular dyskeratosis (Darier). *Z Hautkr* 1974;49:579-80.
7. Kellium RE, Haserick JR. Localized linear keratosis follicularis. Response to intralesional vitamin A and simultaneous occurrence of warty dyskeratoma. *Arch Dermatol* 1962;86:450-4.
8. Cockayne EA. Darier's disease. In: Cockayne EA, editor. *Inherited Abnormalities of the Skin and Its Appendages*. Oxford: Oxford University Press; 1993. pp. 134-8.
9. Happle R. A rule concerning the segmental manifestation of autosomal dominant skin disorders: review of clinical examples providing evidence for dichotomous types of severity. *Arch Dermatol* 1997;133:1505-9.
10. Casals M, Campoy A, Aspiolea F, Carrasco MA, Camps A. Successful treatment of linear Darier's disease with topical adapalene. *J Eur Acad Dermatol Venereol* 2009;23:237-8.
11. Prystowsky JH. Topical retinoids. In: Wolverton SE, editor. *Comprehensive Dermatologic Drug Therapy*. Philadelphia: W.B. Saunders Company; 2001. pp. 578-94.
12. Michel S, Jombard A, Démarchez M. Pharmacology of adapalene. *Br Assoc Dermatol* 1998;139:3-7.

13. Wolf JE. Potential anti-inflammatory effects of topical retinoids and retinoid analogues. *Adv Ther* 2002;19:109-18.
14. Yoon TY, Kim JW, Kim MK. Successful treatment of Darier disease with topical 5-fluorouracil. *Br J Dermatol* 2006;154:1210-2.
15. Van't Westeinde SC, Sanders CJ, Van Weelden H. Photodynamic therapy in a patient with Darier's disease. *J Eur Acad Dermatol Venereol* 2006;20:870-2.

Sibel Dogan¹, Ayşen Karaduman¹, Gul Erkin¹, Ozay Gokoz²

¹Department of Dermatology, ²Department of Pathology, Faculty of Medicine, Hacettepe University, Ankara, Turkey

Corresponding author:

Sibel Dogan, MD
Department of Dermatology
Faculty of Medicine, Hacettepe University
Sihhiye 06100, Ankara
Turkey
sibel.dogan@hacettepe.edu.tr

Received: October 21, 2010

Accepted: July 15, 2011

Generalized Pustular Psoriasis-Like Dermatophytosis due to *Trichophyton rubrum*

Trichophyton rubrum (*T. rubrum*) accounts for approximately 90% of chronic superficial dermatophyte infections in human host (1). In particular, it is frequently implicated in tinea corporis caused by anthropophilic fungi, in which it can produce large annular lesions with a poorly defined border and erythema or scaling (2). In 1968, Ive and Marks (3) used the term "tinea incognito" for cases of epidermomycosis, erroneously treated with topical steroids, having clinical manifestations that mimicked other skin conditions such as seborrheic dermatitis, lichen planus, folliculitis, and rosacea (1).

We reported on a patient with generalized tinea incognito caused by *T. rubrum*, who presented two weeks after being cured by fluconazole, with pustular psoriasis-like generalized tinea corporis.

A 56-year-old previously healthy woman presented to dermatology clinic (Faghihi Hospital, Shiraz, Iran) with a 2-year history of pruritic erythematous lesions involv-

ing the left leg, back, shoulders, right arm and forearm. The lesions were treated erroneously as eczema in three other medical centers, and she received topical corticosteroids, emollients and antihistamines. Her past medical history did not reveal any significant disease. In terms of drug history, she did not use any drug on regular basis except for the above-mentioned drugs.

On physical examination, erythematous, sharply demarcated lesions were observed on the above-mentioned areas of her body (Fig. 1). Other physical examinations showed nothing abnormal. Routine laboratory tests were within the normal limits. Microscopic examination of skin scrapings from the lesions with potassium hydroxide (KOH) revealed dermatophyte hyphae. *T. rubrum* was detected in the culture of skin scrapings.

A course of 4-week fluconazole (150 mg daily) was started. The patient did not present to our clinic for follow up.

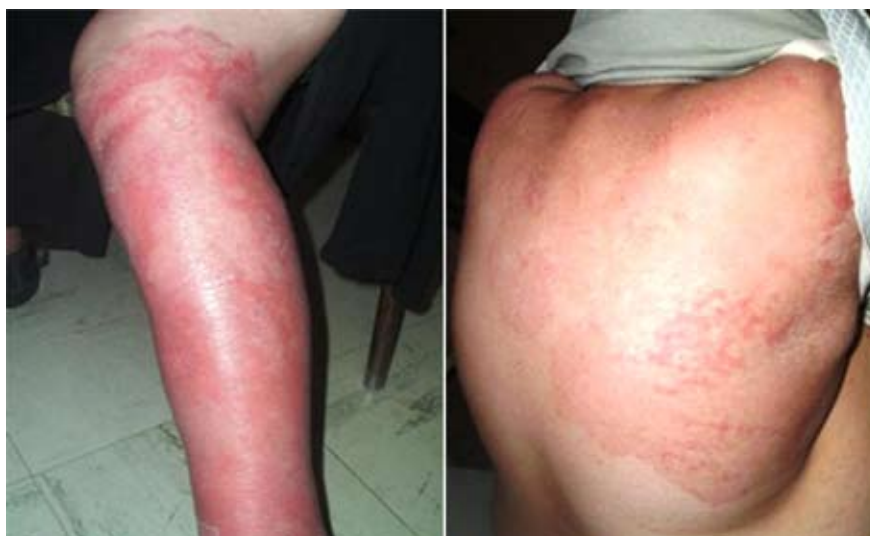

Figure 1. Erythematous, sharply demarcated lesions on the leg and back, with active margin and scaling surface.

Two weeks after ending the treatment course, the patient presented again to one of the above-mentioned dermatologic centers. They suspected pustular psoriasis and decided to start therapy with methotrexate. Before starting the new treatment, the patient presented to our dermatologic clinic. On physical examination, previous lesions were found to have changed to well-demarcated and round plaques with scaling and pustules on the back, face, arms, and right leg (Fig. 2). KOH smear and fungal culture indicated the diagnosis of *T. rubrum* dermatophytosis again, thus the previous 4-week course of fluconazole was reintroduced. After four weeks, complete resolution of all lesions was observed. Six-month follow up was normal.

Tinea corporis may be caused by either zoophilic fungi or anthropophilic organisms, less frequently

by geophilic fungi (2). As a result of misdiagnosis or presence of pre-existing pathologies treated with local steroids, the clinical appearance of the lesions may mimic other skin conditions (1). Crawford *et al.* (4) report on not only corticosteroids but also new class topical non-steroidal medications including pimecrolimus and tacrolimus to have induced tinea incognito.

Generalized dermatophyte infections of the skin are typically observed in immunocompromised patients (e.g., patients receiving long-term immunosuppressive therapy, patients with HIV infection or with underlying lymphoproliferative disorders) (5). There are a few descriptions in the literature of widespread tinea corporis in immunocompetent patients (6), but there are some reports of widespread and chronic

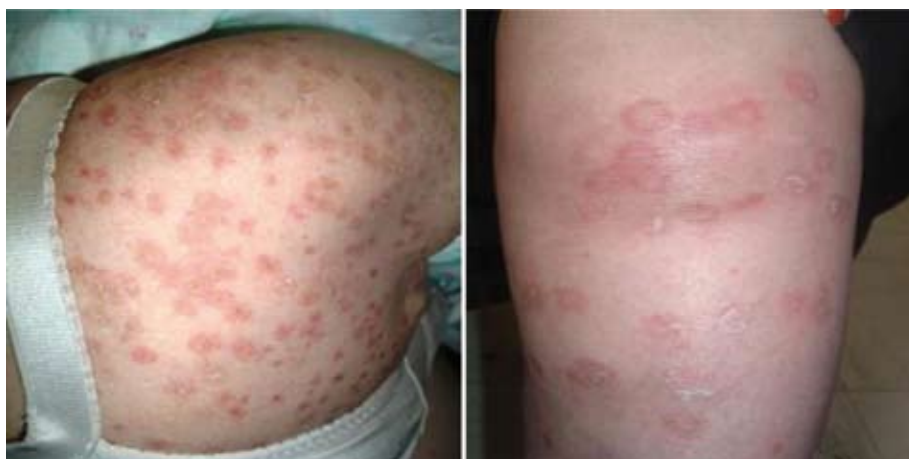

Figure 2. Erythematous, well demarcated round plaques with scaling and pustules on the back and arm.

dermatophyte infections in atopics (2) and in patients with Cushing's syndrome (7).

The novel case described herein presented with pustular psoriasis-like generalized tinea corporis lesions. Serarslan (8) reports on a patient with tinea incognito characterized by pustular inflammatory skin lesions after receiving steroid and emollient therapy, as in our patient. *T. rubrum* is a fungus that most frequently induces both widespread dermatophytosis and atypical features and may cause pustular reaction (2).

Ilkit *et al.* (9) report on plaques with erythema and papules in the neck and breast area due to *T. rubrum* in a 20-year-old female. She was treated with corticosteroids for a long time. They conclude that tinea incognito could present in various clinical features, usually due to wrong treatment modalities. They suggest investigation of fungi in atypical erythematous plaques. Kastelan *et al.* (10) report on a 72-year-old woman treated unsuccessfully with topical steroid cream for 3 months. Multiple nummular scaly papules and plaques were found on her arms and trunk. They describe circular and erythematous lesions with sharp demarcated and raised scaly edges. Finally, *T. rubrum* was cultured on Sabouraud's agar. They suggest that in patients previously treated with steroids, disseminated scaly infiltrate lesions should be investigated for fungal infection.

Although we treated our patient with fluconazole, terbinafine remains a good first-line treatment because *T. rubrum* is still highly sensitive to terbinafine (11). In conclusion, concerning clinical features of the case presented, dermatophyte infection may be considered on differential diagnosis of generalized pustular dermatoses.

References

- Romano C, Maritati E, Gianni C. Tinea incognito in Italy: a 15-year survey. *Mycoses* 2006;49:383-7.
- Gorani A, Schiera A, Oriani A. Case report. Widespread tinea corporis due to *Trichophyton rubrum*. *Mycoses* 2002;45:195-7.
- Ive FA, Marks R. Tinea incognito. *Br Med J* 1968;3:149-52.
- Crawford KM, Bostrom P, Russ B, Boyd J. Pimecrolimus-induced tinea incognito. *Skinmed* 2004;3:352-3.
- Hoetzenecker W, Schanz S, Schaller M, Fierlbeck G. Generalized tinea corporis due to *Trichophyton rubrum* in ichthyosis vulgaris. *J Eur Acad Dermatol Venereol* 2007;21:1129-31.
- Vittorio CC. Widespread tinea corporis in an immunocompetent patient resistant to all conventional forms of treatment. *Cutis* 1997;60:283-5.
- Canizares O, Shatin H, Kellert AJ. Cushing's syndrome and dermatomycosis. *Arch Dermatol* 1959;80:705-12.
- Serarslan G. Pustular psoriasis-like tinea incognito due to *Trichophyton rubrum*. *Mycoses* 2007;50:523-4.
- Ilkit M, Karakas M, Yuksel T. A tinea incognito case caused by *Trichophyton rubrum* with clinical and mycological cure and review of the literature. *Mikrobiyol Bul* 2010;44:149-53. (in Turkish)
- Kastelan M, Massari LP, Brajac I. Tinea incognito due to *Trichophyton rubrum* – a case report. *Coll Antropol* 2009;33:665-7.
- Diogo HC, Melhem M, Sarpieri A, Pires MC. Evaluation of the disk-diffusion method to determine the *in vitro* efficacy of terbinafine against subcutaneous and superficial mycoses agents. *An Bras Dermatol* 2010;85:324-30.

Amir Feily¹, Mohammad Reza Namazi², Hamidreza Seifmanesh³

¹Infectious Research Center and Department of Dermatology, Jundishapur University of Medical Sciences, Ahvaz; ²Shiraz Skin Research Center, Shiraz University of Medical Sciences, Shiraz; ³Tehran University of Medical Sciences, Tehran, Iran

Corresponding author:

Mohammad Reza Namazi, MD
Department of Dermatology
Faghihi Hospital
Shiraz
Iran
namazi_mr@yahoo.com

Received: May 24, 2010

Accepted: July 14, 2011