

Central Type of Chondrosarcoma with a Fulminant Course – A Case Report

Dubravka Matanić¹, Melita Kukuljan², Emina Grgurević², Bojan Miletić³, Veljko Flego¹ and Damir Muhvić⁴

¹ University of Rijeka, Rijeka University Hospital Center, Department of Pulmology, Rijeka, Croatia

² University of Rijeka, Rijeka University Hospital Center, Department of Radiology, Rijeka, Croatia

³ Opatija Thalassotherapia, Opatija, Croatia

⁴ University of Rijeka, School of Medicine, Department of Physiology and Immunology, Rijeka, Croatia

ABSTRACT

Primary chondrosarcoma is a rare malignant tumor. The five types of chondrosarcomas are: central, peripheral, mesenchymal, differentiated and clear cell. The classic chondrosarcomas are central (arising within a bone) or peripheral (arising from the surface of a bone). We describe a patient with central chondrosarcoma of the humerus who underwent surgery and only two weeks later presented with multiple metastases of the lung and small pulmonary tumor embolisms mimicking bilateral pneumonic infiltrates. Therefore, such a fulminant course of central chondrosarcoma, which is not described so far, must be taken into consideration during the treatment of patients with primary chondrosarcoma.

Key words: *primary chondrosarcoma, central chondrosarcoma, multiple metastases of the lung, pulmonary tumor embolisms, fulminant course*

Introduction

Chondrosarcoma (CS) is the second most common primary malignant spindle cell tumor of bone¹. Chondrosarcomas form a heterogeneous group of tumors whose basic neoplastic tissue is cartilaginous without evidence of direct osteoid formation². Occasionally, bone formation occurs from differentiation of cartilage. If evidence is found of direct osteoid or bone production, the lesion is classified as an osteosarcoma. The five types of chondrosarcomas are central, peripheral, mesenchymal, differentiated and clear cell^{1,3}. The classic chondrosarcomas are central (arising within a bone) or peripheral (arising from the surface of a bone). The other three are variants and have distinct histologic and clinical characteristics. Both central and peripheral chondrosarcomas can arise as primary tumors or secondary to underlying neoplasm. Seventy-six percent of primary chondrosarcomas arise centrally^{1,3,4}. Secondary chondrosarcomas most often arise from benign cartilage tumors. The multiple forms of benign osteochondromas or enchondromas have a higher rate of malignant transformation than the corresponding solitary lesions^{4,5}. Markers of cell differentiation, ac-

tivation, genetics and cell signaling may offer important prognostic information^{6–8}.

We describe a central type of chondrosarcoma arising within humerus with unusual, fulminant course. Multiple pulmonary metastases were developed only two weeks after surgery mimicking pneumonic infiltrates. The patient died ten days later from subacute respiratory and cardiac insufficiency. Post mortem pathohistology showed multiple tumor emboli of the lungs accompanied by multiple tumor emboli of the pulmonary artery.

Case Report

A 38-year-old man was admitted to the orthopedic clinic because of pain in the right shoulder. The X-ray revealed radiological suspicion of the tumor of the right humerus. Fine needle aspiration biopsy was performed, but material was inadequate for cytological analysis. Therefore an open biopsy was performed. Pathohistological diagnosis was CS grade I. All the laboratory findings and

chest radiography at this time were normal (Figure 1). After that the patient underwent surgery – the tumor was extirpated, arthrodesis of the right humeroscapular joint and spongioplastic of the humerus with homotransplantations was made. Postoperative patohistological diagnosis was CS grade II (Figure 2). Two weeks after the surgery the patient become high febrile with productive cough and dyspnea. The laboratory analysis showed leukocytosis of $11.3 \times 10^9/L$ (normal range = $NR 4-9 \times 10^9/L$), elevated sedimentation rate 115 (NR 2–10 mm/h), C reactive protein 150 mg/L (NR <5), alkaline phosphatase 204 (NR 3–104 U/L), gamaglutamyltransferase 171 (NR 7–32 U/L), aspartataminotransferase 48 (NR 6–35 U/L), alaninaminotransferase 119 (NR 6–35 U/L), fibrinogen 9.6 (NR 1–3.5 mmol/L) and D-dimer 527 (NR <192 mg/L). All other biochemical and hematological findings were within normal limits. Chest radiography showed bilateral infiltrates of the lung pointing to pneumonia. The patient was transferred to the department of pulmology. Computer tomography (CT) of the chest confirmed bilat-

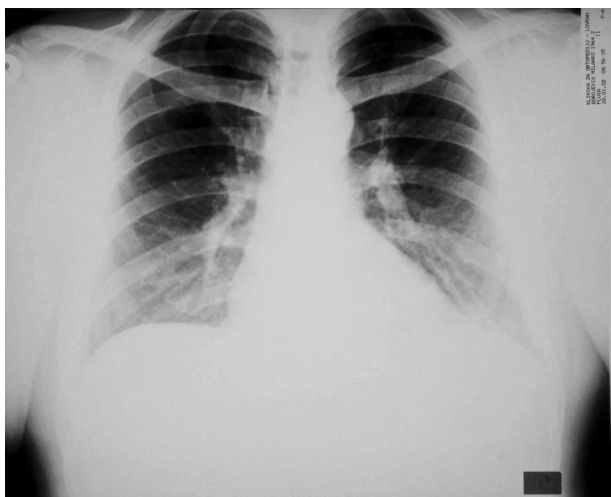


Fig. 1. Chest radiograph before surgery appears normal.

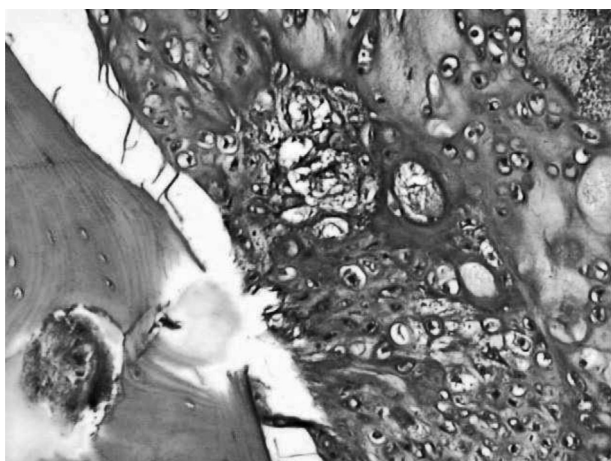


Fig. 2. Tumor biopsy specimen shows chondrosarcoma grade II that is infiltrating the bone and expanding to neighbor soft tissue.

eral pneumonia. Fiber optic bronchoscopy demonstrated only yellow secretion in tracheobronchal system. Microbiological, mycological and cytological findings of the specimens obtained by bronchial washing were negative. Mycobacteria Growth Indicator Tube test was negative. All the hemocultures were negative too, the serological tests on respiratory viruses and HIV as well. The radiography of the right shoulder showed no local abnormalities after surgery. On the initial combined antimicrobial therapy the patient did not react. He remained high febrile and developed small pleural effusion. The pleural puncture was performed. The cytological finding pointed to the inflammation. Microbiological finding was negative. Control chest radiography showed bilateral pneumonia-like infiltrates (Figure 3) and CT showed progression of the disease and few nodular infiltrates were observed pointing to possible metastasis process (Figure 4). CT guided transthoracal puncture was performed – cytological finding was typical for inflammation. Despite changed antimicrobial therapy clinical worsening occurred and the patient died two weeks later. The autopsy showed multiple metastases of the lung with multiple small thromboemboli of the lung by tumor cells.

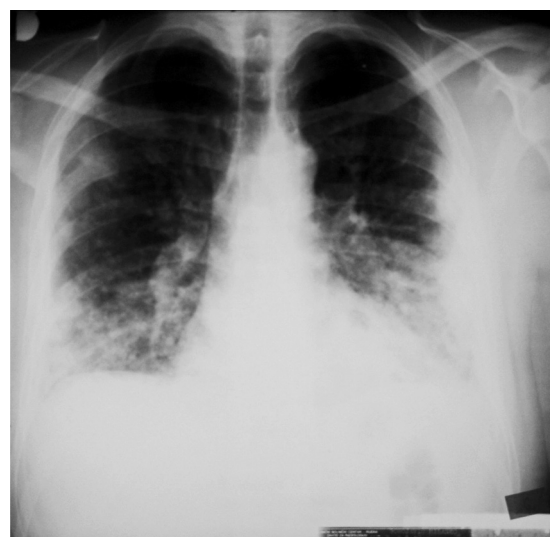

Fig. 3. Chest radiograph shows bilateral pneumonia like patchy consolidations.

Discussion and Conclusion

Primary bone tumors are rare tumors, compared with other malignant tumors⁹. The appearance of chondrosarcoma in our patient was in the age of 38 years and that was very close to age over 40 years in which one half of all chondrosarcoma occur¹. Primary CS is the second most common malignant tumor of bone¹⁰. The most affected bones are the pelvis (31%), femur (21%) and shoulder girdle (13%)^{4,5}. Chondrosarcomas of the proximal humerus is an uncommon malignant bone tumor¹¹. As in our case, the most common presentation of the tumor is local pain (81.4% of the cases) with radiological signs of

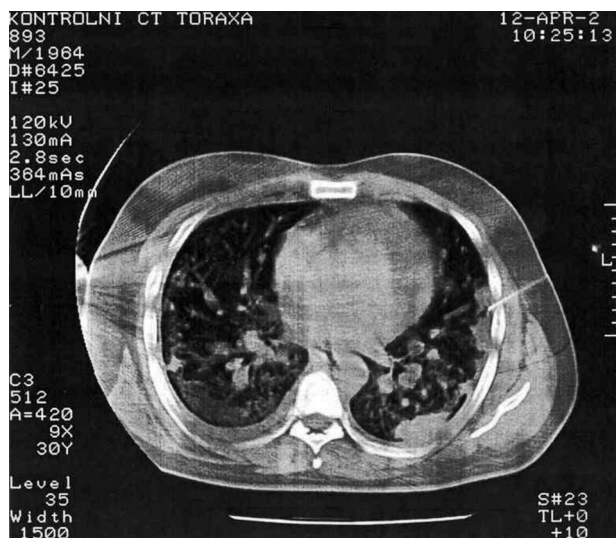


Fig. 4. Transverse computer tomography scan (CT) of the chest obtained during the fine needle aspiration biopsy (FNAB) shows bilateral nodular consolidations representing metastases.

bone tumor¹². Pain, which indicates active growth, is an ominous sign of central cartilage lesion¹³. Fine needle aspiration biopsy (FNAB) is the first step of the initial evaluation of the CS, especially in cases with classic clinical and radiological findings^{14,15}. A possible substitution can be open surgical biopsy if the material provided by FNAB is inadequate. It is not uncommon to make a mistake grading the tumor in this phase of diagnosis and change it to high-grade tumor at the final diagnosis. The same CS, because of lack of experience, can be graded differently at different institutions, and some authors have described even mistakes determining the type of the malignant bone tumor before and after the surgery¹⁶. We think that similar problems could be responsible for discrepancy between pathohistological grade between an open

biopsy (CS grade I) an postoperative pathohistological diagnosis (CS grade II). The importance of these mistakes can be illustrated by the fact that development of metastases ranges from 0% in patients with grade I tumor to 20% in grade II tumor, 60% in grade III tumor, and 75% in patients with dedifferentiated CS¹⁷. Some researches have proven that localization of the tumor, type of surgery and duration of symptoms are of no prognostic significance¹⁸. This makes histological grading even more important in predicting the clinical course of CS.

The development of metastases together with local recurrence and subtype of CS have significant influence on survival rate. Most commonly affected localizations with metastases are lung, bones and visceral organs. In general, CS shows slow biologic evolution, and metastases usually develop one or more years after surgery. In a study provided by Sheth this time ranged from 1 to 111 months¹⁷. Surgery with large tumor excision remains the most reliable treatment option. Aside from the benefit, surgical intervention means the risk of pulmonary tumor embolism as in the case described by Newkirk, where embolism occurred during operation¹⁹. Similar pathway of tumor dissemination could happened in our case where it is probably that the small tumor emboli disseminated in the lungs during surgery or even postoperatively provoking two weeks later multiple tumor metastases. We did not find, however, any case in the literature where the growth of metastases occurred so fast. Also, all the results of the diagnostic procedures performed on our patient pointed to pneumonia, as a most possible postoperatively complication, and misled us in the treatment of the patient. Therefore, even rare, such fulminant and unusual course must be taken into consideration by experienced and cooperative team of specialists to prevent any pitfalls in the diagnosis and treatment of the patient with CS.

REFERENCES

1. DORFMAN HD, CZERNIAK B, *Cancer*, 75 (1995) 203. DOI: 10.1002/1097-0142(19950101)75.
2. HEALEY JH, LANE JM, *Clin Orthop Relat Res*, 204 (1986) 119.
3. LEE FY, MANKIN HJ, FONDREN G, GEBHARD MC, SPRINGFIELD DS, ROSENBERG AE, JENNINGS LC, *J Bone Joint Surg Am*, 81 (1999) 326.
4. MARCOVE RC, *Orthop Clin North Am*, 8 (1977) 811.
5. GARRISON RC, UNNI KK, MCLEOD RA, PRITCHARD DJ, DAHLIN DC, *Cancer*, 49 (1982) 1890. DOI: 10.1002/1097-0142(19820501)49.
6. CHOW WA, *Curr Opin Oncol*, 19 (2007) 371. DOI: 10.1097/CCO.0b013328121430d9.
7. LOZIĆ B, PRIMORAC D, GLAVINIĆ R, SAMIJA RK, ZEMUNIK T, *Coll Antropol*, 35 (2011) 385.
8. ŠPANJOL J, DJORDJEVIĆ G, MARKIĆ D, KLARIĆ M, FUČKAR D, BOBINAC D, *Coll Antropol*, 34 (2010) 119.
9. LETSON D, FALCONE R, MURO-CACHO CA, *Cancer Control*, 6 (1999) 283.
10. RIZZO M, GHERT MY, HARRELSON JM, SCULLY SP, *Clin Orthop*, 391 (2001) 224. DOI: 10.1097/00003086-20010000-0025.
11. MOURIKIS A, MANKIN HJ, HORNICEK FJ, RASKIN KA, *J Shoulder Elbow Surg*, 21 (2007) 133.
12. BJORNSSON J, MCLEOD RA, UNNI KK, ILSTRUP DM, PRITCHARD DJ, *Cancer*, 83 (1998) 2105. DOI: 10.1002/(SICI)1097-0142(19981115)83:10<2105.
13. LITRELL LA, WENGER DE, WOLD LE, BERTONI F, UNNI KK, WHITE LM, KANDEL R, SUNDARAM M, *Radiographics*, 24 (2004) 1397. DOI: 10.1148/rg.245045009.
14. ROZEMAN LB, CLETON-JANSEN AM, HOGENDOORN PC, *Int Orthop*, 30 (2006) 437. DOI: 10.1007/s00264-006-0212-x.
15. WARD WG, SAVAGE P, BOLES CA, KILPATRICK SE, *Cancer Control*, 8 (2001) 232.
16. JELINEK JS, MURPHEY MD, WELKER JA, HENSHAW RM, KRANSDORF MJ, SHMOOKLER BM, MALAWER MM, *Radiology*, 223 (2002) 731. DOI: 10.1148/radiol.2233011050.
17. SHETH DS, YASKO AW, JOHNSON ME, AYALA AG, MURRAY JA, ROMSDAHL MM, *Cancer*, 78 (1996) 745. DOI: 10.1002/(SICI)1097-0142(1996815)78:4<745.
18. FIORENZA F, ABUDU A, GRIMER RJ, CARTER SR, TILLMAN RM, AYOUB K, MANGHAM DC, DAVIES AM, *J Bone Joint Surg Br*, 84 (2002) 93. DOI: 10.1032/0301-620x.84B1.11942.
19. NEWKIRK L, VATER Y, OXORN D, MULLIGAN M, CONRAD E, *Can J Anaesth*, 50 (2003) 886. DOI: 10.1007/BFO03018733.

D. P. Muhvić

*University of Rijeka, School of Medicine, Department of Physiology and Immunology, Braće Branchetta 20,
51000 Rijeka, Croatia
e-mail: damirm@medri.hr*

CENTRALNI TIP HONDROSARKOMA S FULMINANTNIM TIJEKOM – PRIKAZ SLUČAJA

S A Ž E T A K

Primarni hondrosarkom je rijetka zloćudna novotvorina. Postoji pet tipova hondrosarkoma: centralni, periferni, mezenhimalni, diferencirani i svjetlostanični. Klasični hondrosarkomi su centralni (javljaju se u unutrašnjosti kosti) ili periferni (javljaju se na površini kosti). Prikazan je slučaj pacijenta s centralnim hondrosarkomom nadlaktične kosti kod kojeg su se svega dva tjedna po operativnom zahvatu pojavile višestruke metastaze na plućima i mali tumorski emboli u plućima koji su imitirali obostrane plućne upalne infiltrate. Zbog prethodno iznesenog, ovakav, do sada neopisan u literaturi, fulminantni tijek centralnog hondrosarkoma treba uzeti u razmatranje prilikom liječenja pacijenata s primarnim hondrosarkomom.