

TWELVE FACTS THAT EVERY DOCOTOR OF DENTAL MEDICINE SHOULD KNOW ABOUT THE ORAL CAVITY CARCINOMA

Mišo Virag, Lana Đonlagić

Department of Maxillofacial Surgery, School of Medicine,
University of Zagreb, Zagreb, Croatia.

Summary

The most frequent malignant tumor of the oral cavity is squamous cell carcinoma, tumor that should be easy recognizable and treated successfully if diagnosed at an early stage. Unfortunately, many of this tumors remain unrecognized until advanced stages when treatment demands extensive surgery or chemoradiotherapy. Treating oral cancer in late stages is often combined with poor outcomes, incomplete recovery and lower quality of life. The authors outline the most important questions necessary for early diagnosis and better understanding of the disease with a goal of preventing delayed diagnosis or misdiagnosis of an oral cavity cancer.

Key words: oral cavity carcinoma; precancerosis; diagnosis; metastatic potential; treatment; prognosis.

INTRODUCTION

Our goal is to discover oral cancer before patients present with pain, a mass, bleeding, otalgia or dysphagia. A thorough, systematic examination of the mouth and neck takes only a few minutes and can detect cancer at an early and curable stage. Errors in diagnosis are most often the ones of omission and therefore, the importance of a systematic approach to the oral, head and neck examination cannot be overemphasized.

THE TWELVE FACTS

Twelve facts are outlined in this text that we consider most important for dental medicine practitioners to be aware of. The knowledge of these facts should reduce

the number of patients seen in everyday practice that were not diagnosed in a timely manner or were mistreated for prolonged period of time and should enable better understanding of the disease.

This text leads through the twelve questions that are easy to memorize and are to be considered during examination in a daily routine as well as follow-up.

1. Who are the patients?

Mostly, it is a population of alcohol and/or cigarette abusers that make over 90% of patients diagnosed with oral cavity cancer. People who use both tobacco and alcohol are at greater risk than people who use them alone. Additionally, many of those ignore the symptoms until in very developed stage of the disease with bleeding and/or dysphagia. Based on the information gathered from our database; over 90% of the patients in our population are male, over 40 years of age, cigarettes and alcohol abusers (*Figure 1*). One study from France showed that extremely heavy drinkers (greater than 100 grams of alcohol per day) had a 30 times greater risk of developing oral and oropharyngeal cancer (a typical serving of beer, wine or liquor contains 10 to 15 grams of alcohol), [1]. Of even greater significance is the synergistic effect of alcohol and smoking; some subsets of patients who are both heavy smokers and heavy drinkers can have over one hundred times greater risk for developing a malignancy [1,2].

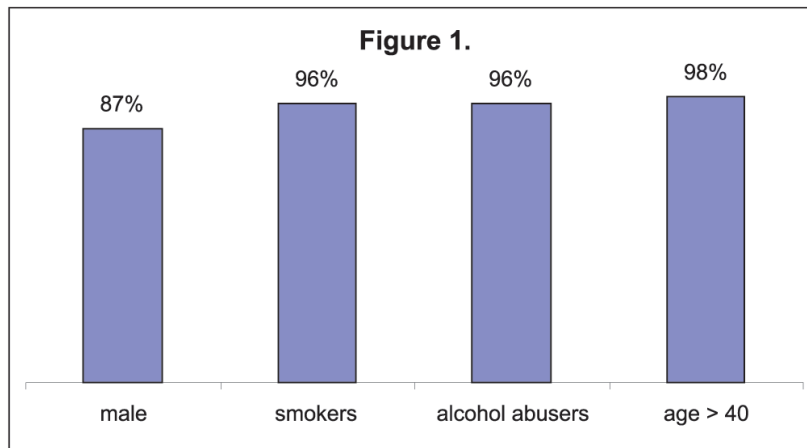


Figure 1. Predominant type of patients.

2. What is the role of Human Papilloma Virus in development of oral cavity cancer?

Recently some very strong evidence has shown that HPV-positive oropharyngeal cancers comprise a distinct molecular, clinical and pathologic disease entity that is causally associated with HPV infection [3-7]. It is also stressed that the incidence of tonsillar carcinoma is increasing despite a decline in tobacco use, supporting the existence of other important risk factors such as HPV infection [8]. The group of French authors did a research on Human Papilloma Virus genotype distribution in oropharynx and oral cavity cancer in France with the results of overall HPV prevalence of 46.5% in oropharyngeal carcinomas and 10.5% in oral cavity carcinomas and higher prevalence in female than in male cases (63.5% vs 42.2% in oropharynx and 17.2% vs 8.0% in oral cavity), [9]. HPV-16 has been detected in up to 22 percent of oral cancers, and HPV-18 has been found in up to 14 percent of cases [4]. HPV is mostly associated with oral cavity carcinomas at younger age and carries better prognosis. The question remains whether HPV vaccination will diminish the increasing number of this diagnosis.

3. Which factors do not lead to the development of oral cavity cancer?

Opposite to the common understanding and many textbooks, irritation of the mucosa due to dental prosthesis, carious teeth or spiced food do not promote the development of oral cavity cancer.

4. Where is initial carcinoma situated?

It almost always begins on the thin mucosa that covers the floor of the mouth, ventral side of the tongue and palatal arches. It is suggested that there is a greater incidence of oral cavity carcinoma at the lower portions of the oral cavity where saliva is accumulated together with all its potentially containing carcinogens (e.g. alcohol, tobacco). This "pool" of saliva is not being exposed to carcinogenic effect of alcohol only during the consumption period (up to 20 minutes) but also after the reabsorption where the effect of saliva excreted alcohol at the floor of the mouth lasts approximately 7,7 hours [10,11]. Moreover, the floor of the mouth is covered by a thinner, nonkeratinized mucosa, which provides less protection against carcinogens. Tobacco/alcohol lesions tend to favor the anterior tongue and mouth, and HPV positive lesions tend to favor the posterior oral cavity. Benign lesions occurring on the dorsum of the tongue have at times been diagnosed as carcinoma. A retrospective study has shown that the occurrence of primary carcinoma on the dorsum of the tongue is an extremely rare entity. It may be erroneously diagnosed in cases of me-

dian rhomboid glossitis, granular cell myoblastoma and any other lesion associated with pseudoepitheliomatous hyperplasia. These conditions should always be considered when examining lesions in this location. Histological diagnosis, although difficult, is greatly facilitated by good biopsy technique but, above all, good liaison between surgeon, radiotherapist and pathologist is essential if these mistakes in diagnosis are to be avoided [12].

5. Which are the precanceroses?

Multiple studies have consistently shown that the earliest manifestation of many oral and oropharyngeal squamous cell cancers is a persistent erythroplastic lesion. It is a reddish lesion that either precedes to or already is a carcinoma. Leukoplakia or lichen planus are also precancerous lesions, but the incidence of malignant transformation is much lower (less than 10%). As defined by the World Health Organization, leukoplakia is "a white patch or plaque that cannot be characterized clinically or pathologically as any other disease" [13]. As such, leukoplakia should be used only as a clinical term [14]. In the evaluation of the patient, leukoplakia is a clinical diagnosis of exclusion. Similar to this definition, erythroplakia is a clinical term that refers to a red patch that cannot be defined clinically or pathologically as any other condition [13]. This definition excludes inflammatory conditions that may result in a red clinical appearance. Some lesions may be intermixed with white areas (erythroleukoplakia). Clinicians must therefore be on the lookout for both red and white (leukoplakia) lesions on the oral mucosa, as well as detection through palpation of indurated and fixed masses within the tissues [15].

6. How does the initial carcinoma look like?

At the earliest stage it is the superficial, reddish, vulnerable, velvet lesion - erythroplakia, later the ulcer develops. As the lesion grows, it may become an exophytic mass with a fungating or papillary surface or an endophytic mass characterized by a depressed, ulcerated surface with a raised, rolled border. The evolving cancer slowly becomes a crusted, nontender, often totally asymptomatic, specially at an early stage. Squamous cell carcinoma is never to be found under the intact mucosal layer.

7. How often does the general or dental medicine practitioner makes the diagnosis of oral cavity cancer?

Unfortunately, rarely. At least 2/3 of the patients were not diagnosed as carcinoma during the initial examination [16].

8. What is the differential diagnosis in patients with unclear or atypical clinical picture?

There are many benign tissue changes that occur in the mouth, and things as simple as a bite on the inside of the cheek may mimic the look of a dangerous tissue change. Traumatic ulcer should always be taken in consideration, thorough examination should reveal the possible cause. Necrotizing sialometaplasia (NS) is a nonneoplastic inflammatory condition of the salivary glands. In 1973, Abrams et al first reported on this condition [17]. Both clinical and histopathologic features of necrotizing sialometaplasia often mimic those of malignancies such as squamous cell carcinoma or salivary gland malignancy. All subsequent reports of necrotizing sialometaplasia stress the importance of correct diagnosis. Familiarity with necrotizing sialometaplasia and correct diagnosis are paramount in avoiding misdiagnosis and over- treatment. Ischemia of salivary gland tissue leading to infarction (trauma) is the most likely cause. In small salivary glands tumors, when lesion becomes larger it can ulcerate the mucosal layer making it difficult to determine their submucosal origin. Also, pathology such as mucosal melanoma can be presented as a pigmented or non-pigmented lesion of oral mucosa.

9. How high is the risk of metastasis?

Fortunately, low. About 40 % of our patients have regional (lymph node) metastases which are in most cases surgically curable and in less than the 1% metastases are distant and thus incurable.

10. How do we treat oral cancer?

Depending on the stage and grade of the tumor the decision is made whether to operate only the primary tumor or to include lymph nodes and preform a neck dissection as well. (See TNM classification, *Table 1*). Extensive "commando" operation which involves resection of the tumor, cervical lymph nodes and often partial resection of the mandible is necessary only at the developed stages of the carcinoma. Smaller tumors can be removed as radically with a peroral approach with much better functional and aesthetic outcomes. Radiation and chemotherapy options may be used adjunctively or palliatively. For some tumors radiation therapy is also an option for curative treatment.

Table 1. TNM Classification - Oral cavity UICC/AJCC 2002.

T1	2 cm or less
T2	> 2 to 4 cm
T3	> 4 cm
T4a	invades adjacent structures: cortical bone, deep muscles of tongue, maxillary sinus, skin of face
T4b	invades adjacent structures: Masticator space, pterygoid plates, skull base, internal carotid artery
N0	no metastasis
N1	homolateral, single, ≤ 3 cm
N2	
	N2a homolateral, single, >3 to 6 cm
	N2b homolateral, single, ≤ 6 cm
	N2c homo and/or contralateral, ≤ 6 cm
N3	> 6 cm
M0	no distant metastasis
M1	distant metastasis

11. What about the prognosis?

This depends on the stage of the disease. At stage I, over 80 % of the patients are cured. Every following stage diminishes the prognosis for 20% down to only 20% successfully treated at the stage IV. Patients with cancers treated in the early stages have less post-treatment disfigurement.

12. How long do we follow-up patients after initial treatment?

Lifelong. Almost all of the local recurrences and metastases occur in first two years, but monitoring should be continued for most of the patients have high susceptibility to develop a new primary tumor of the upper gastrointestinal or respiratory tract as a result of field cancerization. New primary carcinoma is seen in almost 30% of cured patients and the regular monitoring is the best way for early diagnosis and a basis for a successful treatment of the newly developed tumors.

CONCLUSION

The most important message is that early detection of the asymptomatic stage oral cancer translates in general terms to satisfactory clinical outcome and cure in most patients.

Unfortunately, there has been little improvement in the early detection of oral cancer because many patients ignore their symptoms until at very late stage of the disease and both the general practitioners and dentists lack the necessary knowledge and experience. In order to improve oral cancer survival, public education efforts are also necessary to encourage patients to avoid high risk behaviors and to ask their health care providers about regular oral cancer screening examinations. The ability to control oral and oropharyngeal cancer will depend on two cornerstones: prevention and early diagnosis.

References

- [1] *Andre K, Schraub S, Mercier M, et al.* Role of alcohol and tobacco in the aetiology of head and neck cancer: A case-control study in the Doubs region of France. *Oral Oncol Eur J Cancer.* 1995;31B:301-9.
- [2] *Blot WJ, McLaughlin JK, Winn DM, et al.* Smoking and drinking in relation to oral and pharyngeal cancer. *Cancer Res.* 1988;48:3282-7.
- [3] *Miller CS, White DK.* Human papillomavirus expression in oral mucosa, premalignant conditions, and squamous cell carcinoma. A retrospective review of the literature. *Oral Surg Oral Med Oral Pathol Oral Radiol Endod.* 1996;82:57-68.
- [4] *Sugerman PB, Shillito EJ.* The high risk human papillomaviruses and oral cancer: Evidence for and against a causal relationship. *Oral Dis.* 1997;3:130-47.
- [5] *Lindel K, Beer KT, Laissue J, et al.* Human papillomavirus positive squamous cell carcinoma of the oropharynx: A radiosensitive subgroup of head and neck carcinoma. *Cancer.* 2001;92:805-13.
- [6] *Gillison ML, Shah KV.* Human papillomavirus-associated head and neck squamous cell carcinoma: Mounting evidence for an etiologic role for human papillomavirus in a subset of head and neck cancers. *Curr Opin Oncol.* 2001;13:183-8.
- [7] *Mork J, Lie AK, Glattre E, et al.* Human papillomavirus infection as a risk factor for squamous cell carcinoma of the head and neck. *N Engl J Med.* 2001;344:1125-31.
- [8] *Frisch M, Hjalgrim H, Jaeger A, et al.* Changing patterns of tonsillar squamous cell carcinoma in the United States. *Cancer Causes Control.* 2000; 11:489-95.
- [9] *St Guily JL, Jacquard AC, Prétet JL, Haesebaert J, Beby-Defaux A, Clavel C, Agius G, Birembaut P, Okaïs C, Léocmach Y, Soubeyrand B, Pradat P, Riethmuller D, Mouglin C, Denis F.* Human papillomavirus genotype distribution in oropharynx and oral cavity cancer in France-The EDiTH VI study. *J Clin Virol.* 2011; 51:100-4.
- [10] *Macan D, Virag M, Božikov J.* Alcohol levels in saliva related to the anatomic sites of the oral cavity cancer. 6th International Conference on Head and Neck Cancer. Washington: American Head and Neck Society, 2004; p. 220
- [11] *Jovanovic A, Schulten EA, Kostense PJ et al.* Tobacco and alcohol related to the anatomical site of oral squamous cell carcinoma, *J Oral Path Med.* 1993;72:1369-75.

- [12] *Ogus HD, Bennett MH.* Carcinoma of the dorsum of the tongue: a rarity or misdiagnosis. *Br J Oral Surg.* 1978;16(2):115-24.
- [13] *Kramer IR, Lucas RB, Pindborg, JJ, et al.* WHO Collaborating Centre for Oral Precancerous Lesions. Definition of leukoplakia and related lesions: An aid to studies on oral precancer. *Oral Surg Oral Med Oral Pathol.* 1978;46:518-39.
- [14] *Shafer WB, Waldron CA.* A clinical and histopathologic study of oral leukoplakia. *Surg Gynecol Obstet.* 1961;112:411-20.
- [15] *Mashberg A, Samit A.* Early diagnosis of asymptomatic oral and oropharyngeal squamous cancers. *CA-A Cancer J Clin* 1995;45(6):328-51.
- [16] *Virag M.* Diagnosis of intraoral carcinoma in primary medical care. *Lijec Vjesn.* 1983;105(11-12):443-8.
- [17] *Abrams AM, Melrose RJ, Howell FV.* Necrotizing sialometaplasia. A disease simulating malignancy. *Cancer.* 1973;32(1):130-5.

Sažetak

Dvanaest činjenica koje bi svaki doktor dentalne medicine trebao znati o karcinomu usne šupljine

Planocelularni karcinom, nesumljivo najčešći karcinom usne šupljine, vjerojatno je jedan od tumora koji bi se trebao najlakše prepoznati i uspješno liječiti. Nažalost, niti jedno nije stvarnost, mnogi od ovih tumora prepoznaju se u kasnim stadijima kada liječenje zahtjeva opsežan operativni zahvat ili kemoradioterapiju. Liječenje karcinoma usne šupljine u kasnim stadijima često je povezano sa visokom stopom smrtnosti, a u mnogim slučajevima znači nepotpun oporavak i smanjenu kvalitetu života. U ovom članku, autori žele naglasiti najvažnija pitanja koja su neophodna za rano prepoznavanje i bolje razumijevanje bolesti kako bi se preveniralo pogrešno dijagnosticiranje i kasno otkrivanje karcinoma usne šupljine.

Ključne riječi: karcinom usne šupljine; prekanceroze; dijagnoza; metastatski potencijal; liječenje; prognoza.

Corresponding author:

Lana Đonlagić

e-mail: lana.donlagic@gmail.com