

Scientific paper

## TWO RARE CASES OF CENTRAL NERVOUS SYSTEM OPPORTUNISTIC MYCOSES\*

Emilija MLINARIĆ MISSONI<sup>1</sup> and Bruno BARŠIĆ<sup>2,3</sup>

Reference Centre for Mycological Diagnostics of Systemic and Disseminated Infections, Croatian National Institute of Public Health<sup>1</sup>, University Hospital for Infectious Diseases<sup>2</sup>, University of Zagreb School of Medicine<sup>3</sup>, Zagreb, Croatia

Received in May 2012  
CrossChecked in August 2012  
Accepted in November 2012

This article presents two cases of opportunistic mycoses (OMs) of the central nervous system (CNS) caused by *Cryptococcus neoformans* and *Aspergillus nidulans*, respectively. The patients were hospitalised in local hospitals between 2009 and 2011 because of unspecific symptoms (fever, headache, and/or weight lost). Duration of symptoms varied from 4 days to over 2 weeks. The patients were treated with antibiotics and symptomatically. OM was not suspected in any of them. The patients became critically ill with symptoms of CNS involvement and were transferred to the Intensive Care Unit (ICU) of the University Hospital for Infectious diseases (UHID) in Zagreb. None of the patients belonged to the high-risk population for developing OMs. They were not HIV-infected, had no transplantation of bone marrow or solid organ, and were not on severe immunosuppressive chemotherapy. Fungi were isolated from cerebrospinal fluid (CSF) samples and, in one patient, from aspirate of cerebral abscess. Isolation and mycological identification of all fungal isolates and *in vitro* antifungal susceptibility testing of these isolates were done at the Reference Centre for Mycological Diagnostics of Systemic and Disseminated Infections (RCMDSDI) in Zagreb. The patient with cryptococcal meningitis was treated with amphotericin B and fluconazole and the patient with cerebral aspergilloma with voriconazole.

**KEY WORDS:** *Aspergillus nidulans*, CNS, *Cryptococcus neoformans*

The incidence of opportunistic mycoses (OMs) is increasing at an alarming rate, presenting an enormous challenge to healthcare professionals (1). This increase is directly related to the ever-growing population of immunocompromised patients, including individuals undergoing blood and bone marrow transplantation, solid organ transplantation, major surgery, those with HIV/AIDS, neoplastic diseases, and immunosuppressive therapy (1). This group of high-risk hosts has recently been extended to apparently immunocompetent intensive care unit (ICU) patients and persons with anatomic abnormalities (1).

The most common causes of OMs include *Candida albicans* and *Aspergillus fumigatus* (1). In addition to these agents, increasingly important is the growing list of opportunistic yeasts and moulds that includes non-*albicans* *Candida* species, non-*fumigatus* *Aspergillus* species, *Cryptococcus neoformans*, yeast-like fungi such as *Trichosporon* spp., *Malassezia* spp., *Rhodotorula* spp., the zygomycetes, hyaline moulds such as *Fusarium* spp., *Acremonium* spp., *Scedosporium* spp., and a wide variety of dematiaceous fungi such as *Cladophialophora* spp. and *Aureobasidium* spp. (1-6).

Infections with these fungi may have various clinical presentations ranging from fungemia and disseminated infections to more localised infections

\* The subject of this article has partly been presented at the International Symposium "Power of Fungi and Mycotoxins in Health and Disease" held in Primošten, Croatia, from 19 to 22 October 2011.

involving the lung, skin, and paranasal sinuses (7). Given the complexity of the patients at risk and the diverse array of fungal pathogens, OMs pose a considerable diagnostic and therapeutic challenge. Diagnosis depends on a heightened clinical suspicion and obtaining appropriate material for culture. Isolation and identification of the infecting organisms as well as *in vitro* antifungal susceptibility testing of isolates are very important in properly managing infections due to less common opportunistic fungi (1-7).

Here we report two cases of OMs of the central nervous system (CNS) caused by *Cryptococcus neoformans* and *Aspergillus nidulans*, respectively. The aim was to show how efficient cooperation between clinicians and medical mycologists can help the patient and to raise clinicians' awareness of fungal diseases even in apparently immunocompetent individuals.

## CASE REPORTS

### Case 1

A 27-year-old pregnant woman, 2 weeks before admission to ICU of the University Hospital for Infectious diseases (UHID) in Zagreb, presented at the emergency room of a local hospital with fever, headache, and elevated blood pressure. Since preeclampsia was presumed, she delivered a vital male premature infant by caesarean section. The symptoms continued for about 2 weeks and were not resolved by antibiotics. A few days before admission to the ICU, the patient's temperature rose as high as 40.8 °C. She developed left-sided supranuclear facial palsy, right-sided oculomotorius paresis and deviation of the tongue to the left. She had a history of episodic seizures, arterial hypertension, and cerebral atrophy. Because of oligophrenia, she had been prescribed atenol and carbamazepine, but these were taken irregularly.

On admission to the ICU, blood and cerebrospinal fluid (CSF) samples were taken for laboratory analysis. The patient's CSF cell count was 450 mm<sup>-3</sup> with a predominance of polymorphonuclear neutrophils (57 %). Glucose and chloride levels were low (0.6 mmol L<sup>-1</sup> and 105 mmol L<sup>-1</sup>, respectively), and the total protein level was 1.5 g L<sup>-1</sup>. She tested negative for HIV-1 and HIV-2. CD4+ T-cell count was below

300 mm<sup>-3</sup> on two occasions (250 mm<sup>-3</sup> and 257 mm<sup>-3</sup>, respectively). Despite intensive evaluation, no alternative explanation could be found for CD4+ lymphocytopenia.

Intravenous amphotericin B therapy (0.75 mg kg<sup>-1</sup>) was started after receiving a preliminary report from the Reference Centre for Mycological Diagnostics of Systemic and Disseminated Infections (RCMDSDI) indicating cryptococcosis due to the presence of several encapsulated budding blastoconidia in India ink preparation of the patient's CSF and moderate elevated capsular antigen titres in CFS and serum samples detected by the latex agglutination (LA) test (Pastorex Crypto Plus, Bio-Rad). Cryptococcal meningitis was confirmed by cryptococcal isolation from patient's CSF sample on Sabouraud's glucose agar (SGA) and Brain-Heart Infusion agar (BD Diagnostics). Cryptococcaemia was not documented. CSF, blood, urine, and respiratory tract cultures did not show bacteria, acid fast bacilli or other fungi. *C. neoformans* isolate was identified using the ID32C method (bioMérieux) and morphology on cornmeal agar (BD Diagnostics). *In vitro* susceptibility profiles of the *C. neoformans* isolate to flucytosine, amphotericin B, fluconazole, itraconazole and voriconazole were determined with minimum inhibitory concentrations (MICs) using the ATB FUNGUS 3 (bioMérieux) microdilution method. *C. neoformans* isolate was susceptible to all tested antifungal agents. A follow-up lumbar puncture was performed five days after antifungal therapy started. The India ink and LA test were still positive for *C. neoformans*, but cryptococcal culture was negative. The patient's condition improved clinically and the initial symptoms gradually resolved. After three weeks, amphotericin B was replaced by oral fluconazole (400 mg per day) for four weeks. During this period, repeated CFS and serum cryptococcal antigen analyses showed a persistent drop in titres. Microscopic CSF analysis was normal on day 16 of antifungal therapy. Home treatment was continued with oral fluconazol (200 mg per day) for a total of five months. Follow up CD4+ T-cell count was 276 mm<sup>-3</sup>. The patient was otherwise well and the results of mycological analyses of control CSF and serum samples were negative.

*C. neoformans* is an encapsulated basidiomycetous yeast common in soil, especially is the one containing pigeon droppings (8-10). Despite the high prevalence of this fungus in the environment, human cryptococcosis is rare, except in patients with disorders of cell-

mediated immunity such as HIV infection or lymphoreticular malignancies, or in patients with immunosuppression after steroid therapy or organ transplantation (11, 12).

In Croatia, nearly 900 HIV-infected persons had been registered from 1985, when HIV was first diagnosed, to December 2010 (13). The widespread use of highly active antiretroviral therapy (HAART) has lowered the incidence of cryptococcosis in HIV-infected persons in medically developed countries and in Croatia (11, 13). Between 2005 and 2010, RCMDSI verified cryptococcosis in five (33.3 %) HIV-infected patients and ten (66.7 %) non-HIV-infected patients (13). The latter were patients with haematological malignancies (n=9) and one with idiopathic CD4+ lymphocytopenia, presented in this report. There was no evidence of *in vitro* resistance of clinical *C. neoformans* isolates to amphotericin B or fluconazole during this period.

*C. neoformans* enters the host primarily through the respiratory tract and causes the primary infection of the lung. Subsequent bloodstream dissemination from the lungs, usually to the CNS, produces, almost uniformly, fatal cryptococcal meningoencephalitis in susceptible individuals, if it is not diagnosed and treated properly (11, 12). The mycological diagnosis of cryptococcal meningoencephalitis is based on positive CSF and/or serum cryptococcal antigen findings, presence of encapsulated blastoconidia in India ink preparation of CSF, and/or on isolation of *C. neoformans* from CSF (14). Perfect et al. (11) have issued specific recommendations for the management of cryptococcal meningoencephalitis in non-HIV-infected, nontransplant hosts. The key management steps are induction therapy with fungicides such as polyene followed by consolidation and maintenance therapy with fluconazole (11). Thanks to such antifungal regimen *C. neoformans* was eradicated and our patient survived the infection without chronic neurological complications.

#### Case 2

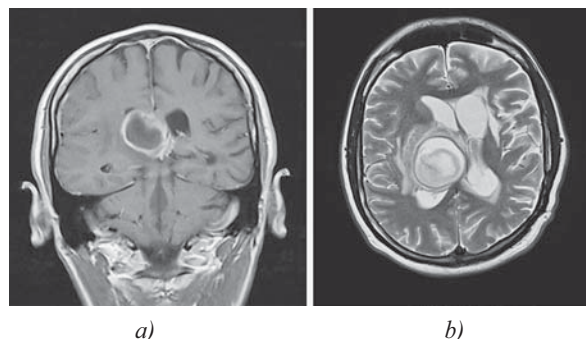
The second 41-year-old male patient was admitted to the ICU of UHID due to four days of fever, headache and confusion. Relevant data from his medical history include peptic ulcer, pulmonary tuberculosis treated 16 years earlier, tongue haemangioma operated eight years earlier, and a stroke as a complication of temporal lobe abscess 6 years earlier. After antibiotic treatment and surgery he recovered fully. One year earlier he had been diagnosed with sideropenic

anaemia. His family history reveals that his mother also suffered from occasional gastrointestinal bleeding and sideropenia.

On admission, erythrocyte sedimentation rate was 30 mm per hour, haemoglobin level was 103 g L<sup>-1</sup>, and lactate was 2.68 mmol L<sup>-1</sup>. HIV-1 and HIV-2 infections were excluded. Laboratory data of the patient's CFS sample included a total cell count of 725 mm<sup>-3</sup> with 70 % neutrophils, 14 % monocytes, 6 % reactive lymphocytes, 2 % macrophages, and 1 % plasma cells. Total protein level was 1.5 g L<sup>-1</sup>. CSF-blood glucose ratio was 0.54.

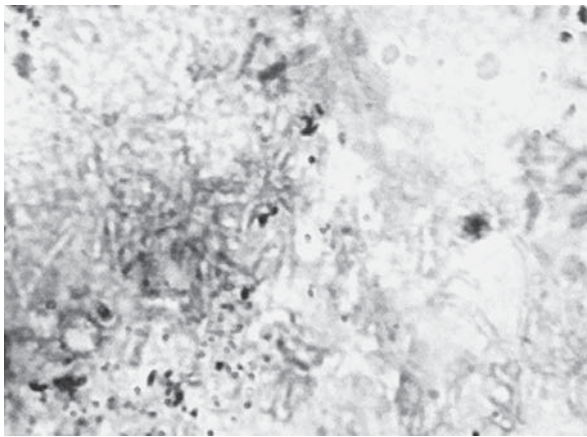
Brain magnetic resonance imaging (MRI) showed a lesion involving the right temporal and parietal lobe, suggestive of brain abscess (Figure 1). This intracranial mass was aspirated by stereotactically and sent for microbiological diagnosis of conventional bacteria, fungi, and acid fast bacilli. Routine microscopic examination of Giemsa-Romanowsky (GR) stained preparations showed the presence of fungal fragments with morphology consistent with hyalohyphomycetes other than zygomycetes (Figure 2).

Following this preliminary report from RCMDSI, intravenous voriconazole [(400+0+200) mg per day] was initiated. Three days later, there was a significant growth of mould on SGA plates at 25 °C and 37 °C (Figure 3). Whitish colonies became powdery to granular, dark green in colour with brownish red on the reverse. Culture for conventional bacteria and acid fast bacilli remained sterile. Identification of *Aspergillus nidulans* was based on a characteristic microscopic appearance of reproductive structure (Figure 3). The *in vitro* activities of four systematically active antifungal agents against *A. nidulans* isolate were

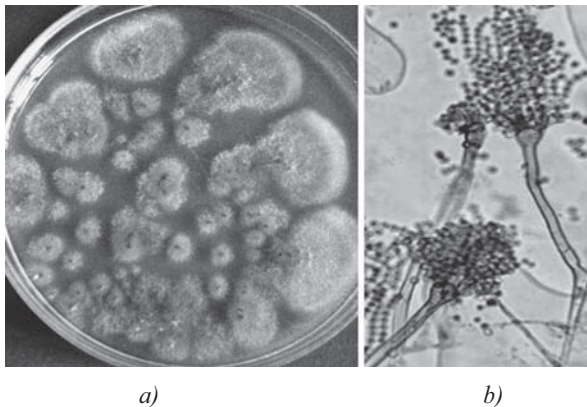


**Figure 1** MRI of the brain a) post-contrast T1WI (weighted imaging) revealed expansive lesion in the right temporal and parietal lobe near the right lateral ventricle, with intensive ring enhancement. A mild perilesional oedema is also visible; b) axial T2WI of the same lesion. These images are consistent with the morphology of brain abscess.





**Figure 2** The hyphae are narrow, septate, branched, of uniform width, variably stained by GR and stand out in sharp contrast to the purulent exudate. Their resemblance to various hyalohyphomycetes such as those of the *Aspergillus* species, *Fusarium* species, *Acremonium* species, *Scedosporium* species make the microscopic differentiation of these fungi difficult. The mass of closely septate, aberrant forms is characteristic of chronic lesions (1000x magnification)



**Figure 3** Macromorphology and micromorphology of *Aspergillus nidulans* isolated from brain abscess aspirate: a) a five-day-old colony culture grown on SGA at 37 °C; b) conidial heads are short, columnar and biserial in Lactophenol cotton blue mount from the colony. Conidiophores are short, brownish and smooth-walled. Conidia are globose and rough-walled (400x magnification).

determined by the Etest method (AB bioMérieux). The activities of the new extended-spectrum triazoles (voriconazole and posaconazole) were considerably better (MICs were 0.016  $\mu\text{g mL}^{-1}$  and 0.032  $\mu\text{g mL}^{-1}$ , respectively) than of amphotericin B (MIC=4  $\mu\text{g mL}^{-1}$ ) and caspofungin (MIC=32  $\mu\text{g mL}^{-1}$ ). Intravenous therapy with voriconazole continued for another 29 days (30 days in total). The patient made a full clinical and radiological recovery. He continued to take

voriconazole orally (2x200 mg per day for the next 3 months).

*A. nidulans*, anamorph of *Emericella nidulans* (Eidam) Vuill. is an airborne hyaline mould found everywhere on various types of substrate, especially soil, and in hospital water systems (15, 16). This *Aspergillus* species has been reported as the cause of diverse infections in humans, either alone or in combination with other opportunistic fungi, including pulmonary or cerebral infections, sinusitis, endophthalmitis, osteomyelitis, eumycotic mycetoma, nail infections, and disseminated aspergillosis (15, 17-19). These infections have been reported almost exclusively in children with chronic granulomatous disease (CGD) (20). In these patients *A. nidulans* is more virulent than other *Aspergillus* species, judging by its propensity to spread from the lungs to adjacent structures and the death rate it has in this population (17-20).

Our patient was an adult without CGD. He had no detectable paranasal sinus, lung, or any other organ involvement at the time of the clinical presentation of brain abscess. The patient was remarkably well before presenting with neurological symptoms. In contrast, cerebral aspergillosis arising from immunosuppression or malignancy is invariably associated with disseminated fungal disease (17-21). Chakrabarti et al. (21) have already reported about cerebral aspergilloma caused by *A. nidulans* in two adult patients. They were operated on and received systemic therapy with amphotericin B, but the infection proved fatal in both.

In order to establish the underlying cause of cerebral aspergilloma in our patient, we thoroughly reviewed his medical history data and the test results. It turned out to be Osler-Weber-Rendu (OWR) syndrome. This autosomal dominant disorder, also known as hereditary haemorrhagic telangiectasia, is typically identified by multiorgan arteriovenous malformations (AVMs), associated haemorrhage, and a positive family history of the disorder (22). Cerebral abscess is the most common neurological manifestation of the OWR syndrome due to filtering function failure of the pulmonary vasculature because of pulmonary AVMs (22).

Conventional techniques including direct microscopy, histopathology and culture of appropriate specimens remain the reference standard for mycological diagnosis of disseminated aspergillosis (15, 23). The increasing diversity of opportunistic hyaline moulds and their differences in susceptibilities

to antifungal agents make identification of the infecting isolate at the species level and determination of its *in vitro* antifungal susceptibility profiles mandatory (15, 23). Novel systems for detection of circulating fungal cell wall markers and/or DNA in blood and other body fluids or in affecting tissues may improve the laboratory diagnosis of disseminated aspergillosis (15, 23). Our results of *in vitro* resistance to amphotericin B and susceptibility to voriconazole were comparable with the published data on *in vitro* activities of these antifungal agents for 13 worldwide clinical *A. nidulans* isolates from different body sites including brain/CSF (24). Poor response and high failure rates have been reported in patients with *A. nidulans* cerebral infection who were treated with amphotericin B (21). Surgery remains the mainstay of therapy in the management of cerebral aspergillosis followed by voriconazole (20, 21). In our patient, treatment with voriconazole and extensive stereotactic aspiration followed by prolonged treatment with the same antifungal agent resulted in an excellent clinical response.

In conclusion, our two cases illustrate how important it is to suspect fungal aetiology of CNS infections. Furthermore, given the ever increasing list of documented fungal pathogens even in apparently immunocompetent individuals, both clinicians and microbiologists should become familiar with various fungi, their epidemiological and pathogenic features, and the optimal approaches to diagnosis and therapy.

## REFERENCES

1. Pfaller MA, Diekema DJ. Rare and Emerging Opportunistic Fungal Pathogens: Concern for Resistance beyond *Candida albicans* and *Aspergillus fumigatus*. *J Clin Microbiol* 2004;42:4419-31.
2. Kutleša M, Mlinarić-Missoni E, Hatvani L, Vončina D, Šimon S, Lepur D, Baršić B. Chronic fungal meningitis caused by *Aureobasidium proteae*. *Diagn Microbiol Infect Dis* 2012;73:271-2.
3. Bolignano G, Criseo G. Disseminated nosocomial fungal infection by *Aureobasidium pullulans* var. *melanigenum*: a case Report. *J Clin Microbiol* 2003;41:4483-5.
4. Gunde-Cimerman N, Grube M, de Hoog GS. The emerging potential of melanized fungi: black yeast between beauty and the beast. *Fungal Biol* 2011;115:935-6.
5. Revankar SG, Sutton DA. Melanized fungi in human disease. *Clin Microbiol Rev* 2010;23:884-928.
6. Michael H, Robert R, Crystal S, Wendy V. *Aureobasidium pullulans* infection: fungemia in an infant and a review of human cases. *Diagn Microbiol Infect Dis* 2005;51:209-13.
7. Segal BH, Almyroudis NG, Battiwalla M, Herbrecht R, Perfect JR, Walsh TJ, Wingard JR. Prevention and early treatment of invasive fungal infection in patients with cancer and neutropenia and in stem cell transplant recipients in the era of newer broad-spectrum antifungal agents and diagnostic adjuncts. *Clin Infect Dis* 2007;44:402-9.
8. Cafarchia C, Camarda A, Romito D, Campolo M, Quaglia NC, Tullio D, Otranto D. Occurrence of yeasts in cloacae of migratory birds. *Mycopathologia* 2006;161:229-34.
9. Randhawa SH, Kowshik T, Chowdhary A, Sinha P, Khan UZ, Sun S, Xu J. The expanding host tree species spectrum for *Cryptococcus gattii* and *Cryptococcus neoformans* and their isolations from surrounding soil in India. *Med Mycol* 2008;46:823-33.
10. Costa AK, Sidrim JJ, Cordeiro RA, Brilhante RS, Monteiro AJ, Rocha MF. Urban pigeons (*Columba livia*) as a potential source of pathogenic yeasts: a focus on antifungal susceptibility of *Cryptococcus* strains in Northeast Brazil. *Mycopathologia* 2010;169:207-13.
11. Perfect JR, Dismukes WE, Dromer F, Goldman DL, Graybill JR, Hamill RJ, Harrison T S, Larsen RA, Lortholary O, Nguyen MH, Pappas PG, Powderly WG, Singh N, Sobel JD, Sorrell TC. Clinical practice guidelines for the management of cryptococcal disease: 2010 update by the infectious diseases Society of America. *Clin Infect Dis* 2010;50:291-322.
12. Park BJ, Wannemuehler KA, Marston B J, Govender N, Pappas PG, Chiller TM. Estimation of the current global burden of cryptococcal meningitis among persons living with HIV/AIDS. *AIDS* 2009;23:525-30.
13. Mlinarić-Missoni E, Hagen F, Chew WHM, Važić-Babić V, Boekhout T, Begovac J. *In vitro* antifungal susceptibilities and molecular typing of sequentially isolated clinical *Cryptococcus neoformans* strains from Croatia. *J Med Microbiol* 2011;60:1487-95.
14. Murray PR, Rosenthal KS, Pfaller MA. *Medical Microbiology*. 6<sup>th</sup> ed. Philadelphia: Mosby Elsevier; 2009.
15. de Hoog GS, Guarro J, Gene J, Figueras MJ. *Atlas of Clinical Fungi*. 4<sup>th</sup> ed. Utrecht: CBS; 2011.
16. Anaissie EJ, Stratton SL, Dignani CM, Summerbell RC, Rex JH, Monson TP, Spencer T, Kasai M, Francesconi A, Walsh TJ. Pathogenic *Aspergillus* species recovered from a hospital water system: a 3-year prospective study. *Clin Infect Dis* 2002;34:780-9.
17. Dotis J, Panagopoulou P, Filioti J, Winn R, Toptsis C, Panteliadis C, Roilides E. Femoral osteomyelitis due to *Aspergillus nidulans* in a patient with chronic granulomatous disease. *Infection* 2003;31:121-4.
18. Dotis J, Roilides E. Osteomyelitis due to *Aspergillus* species in chronic granulomatous disease: an update of the literature. *Mycoses* 2011;54:686-96.
19. Bukhari E, Alrabiaah A. First case of extensive spinal cord infection with *Aspergillus nidulans* in a child with chronic granulomatous disease. *J Infect Dev Ctries* 2009;3:321-3.
20. Segal BH, De Carlo ES, Kwon-Chung KJ, Malech HL, Gallin JI, Holland SM. *Aspergillus nidulans* infection in chronic granulomatous disease. *Medicine* 1998;77:345-54.
21. Chakrabarti A, Marak RSK, Singhi S, Gupta S, Hurst SF, Padhye AA. Brain abscess due to *Aspergillus nidulans*. *J Med Mycol* 2006;16:100-4.

22. Panigrahi A. Pediatric Osler-Weber-Rendu Syndrome [displayed 30 October 2012]. Available at <http://emedicine.medscape.com/article/957067-overview>
23. Dornbusch HJ, Groll A, Walsh TJ. Diagnosis of invasive fungal infections in immunocompromised children. *Clin Microbiol Infect* 2010;16:1328-34.
24. Espinel-Ingroff A, Johnson E, Hockey H, Troke P. Activities of voriconazole, itraconazole and amphotericin B *in vitro* against 590 moulds from 323 patients in the voriconazole. Phase III clinical studies. *J Antimicrob Chemother* 2008;61:616-20.

### Sažetak

#### OPORTUNISTIČKE MIKOZE SREDIŠNJEGA ŽIVČANOG SUSTAVA – PRIKAZ DVAJU BOLESNIKA

U ovom radu prikazana su dva bolesnika oboljela od oportunističkih mikoza (OM) središnjega živčanog sustava uzrokovanih vrstama *Cryptococcus neoformans* i *Aspergillus nidulans*. Bolesnici su bili hospitalizirani u lokalnim bolnicama od 2009. do 2011. godine zbog nespecifičnih simptoma (febrilitet, glavobolja i/ili gubitak tjelesne težine). Trajanje simptoma variralo je od 4 dana do više od 2 mjeseca. Bolesnici su bili liječeni antibioticima i simptomatski. Ni u jednog bolesnika nije postojala sumnja na OM. Kod oba bolesnika razvile su se teške kliničke slike infekcije sa simptomima zahvaćanja središnjega živčanog sustava i stoga su bili primljeni u Jedinicu intenzivnog liječenja Klinike za infektivne bolesti "Dr. F. Mihaljević" u Zagrebu. Nijedan bolesnik nije pripadao skupini bolesnika s najvećim rizikom od razvoja oportunističkih mikoza. Nisu bili inficirani HIV-om, niti su bili liječeni transplantacijom koštane srži ili solidnog organa, kao ni jakim imunosupresivnim lijekovima. Gljivični izolati izdvojeni su iz uzoraka likvora u jednog bolesnika, a u drugog bolesnika iz uzorka aspirata moždanog apscesa. Izolacija i mikološka identifikacija svih gljivičnih izolata i *in vitro* ispitivanje osjetljivosti gljivičnih izolata na antifungalne lijekove bili su provedeni u Referentnom centru za mikološku dijagnostiku sustavnih i diseminiranih infekcija (RCMDSDI) u Zagrebu. Amfotericin B i flukonazol davani su za liječenje kriptokoknog meningitisa, a vorikonazol za liječenje aspergiloma mozga.

**KLJUČNE RIJEČI:** *Aspergillus nidulans*, *Cryptococcus neoformans*, SŽS

#### CORRESPONDING AUTHOR:

Emilija Mlinarić-Missoni  
Reference Centre for Mycological Diagnostics of Systemic  
and Disseminated Infections Croatian National Institute of  
Public Health  
Rockefellerova 2, 10000 Zagreb, Croatia  
E-mail: [emilija.mlinaric-missoni@hzjz.hr](mailto:emilija.mlinaric-missoni@hzjz.hr)