

# Effects of Alpha-MSH on Corneal Epithelial Lesions in Rats

Josip Pavan<sup>1</sup>, Adrian Lukenda<sup>1</sup>, Nikola Štambuk<sup>2</sup>, Paško Konjevoda<sup>2</sup>, Snježana Kaštelan<sup>1</sup> and Marko Ćurković<sup>1</sup>

<sup>1</sup> University of Zagreb, Dubrava University Hospital, Department of Ophthalmology, Zagreb, Croatia.

<sup>2</sup> »Ruder Bošković« Institute, Zagreb, Croatia

## ABSTRACT

We investigated the influence of alpha-melanocyte stimulating hormone ( $\alpha$ -MSH) on the healing of corneal epithelial lesions in male Wistar rats. The lesions were induced by abrading corneal epithelium with a surgical lancet under a biomicroscope. Before the abrasion corneal epithelium was softened with 40% ethanol.  $\alpha$ -MSH drops in a concentration of  $1 \times 10^{-4}$  mg/mL significantly promoted epithelial healing, when compared to the control group treated with 0.9% NaCl. Significant reduction of ocular irritation was also observed. Topical  $\alpha$ -MSH medication could promote the healing of corneal wounds and reduce local inflammatory response without the major side effects of the corticosteroid therapy.

**Key words:** alpha-MSH, cornea, drops, epithelization, wound, healing, irritation

## Introduction

Alpha-melanocyte stimulating hormone ( $\alpha$ -MSH) is a peptide deriving from the post-translational processing of the pro-opiomelanocortin (POMC) molecule<sup>1,2</sup>. The POMC prohormone gives rise to a variety of biologically active peptides including adrenocorticotropin (ACTH) and  $\alpha$ -MSH<sup>1,2</sup>.  $\alpha$ -MSH corresponds to the first 13 amino acids of the ACTH sequence. A synthetic peptide fragment of ACTH<sup>4-10</sup> has been shown to improve the rabbit cornea wound healing<sup>3</sup>.

Other results indicated that in addition to strong anti-inflammatory and cytoprotective effects on different organs and tissues  $\alpha$ -MSH elicits antimicrobial and anti-fungal effects<sup>1,2,4,5</sup>.

Impaired and prolonged reepithelization of corneal lesions may result in long lasting corneal defects, which can possibly be followed by serious complications such as microbial and fungal inflammation and corneal opacification. Therefore, we have investigated the effects of  $\alpha$ -MSH on the corneal healing and reduction of eye irritation caused by the abrasion of rat corneal epithelium.

## Materials and Methods

### Animals

Wistar male albino rats weighing from 160 to 180 g were used as the experimental animals. They were kept

under standard conditions with a 12 hour light/dark cycle. The rats were divided in groups of 6 animals and a control group had 8 animals.

### Corneal abrasion

Standardized 3 mm wide circular lesions were induced by abrading corneal epithelium with a surgical lancet under a hand-held biomicroscope (Heine HSL 100)<sup>6</sup>. Before scraping the cornea, epithelium was softened with a circular filter paper soaked in 40% ethanol, placed on cornea for 30 seconds and irrigated with saline solution. Abrasion procedure was done in light ether anesthesia (Narkosaether, Lek, Slovenia). Immediately after the abrasion, corneas were dyed with a sterile fluorescein solution. High resolution digital camera (Panasonic NV-GX7, 1200000 pixels) was used to make the photographs of abraded corneas under a cobalt blue UV lamp at 0, 2, 8, 16 and 24 hour intervals.

### Treatment protocol

Corneal lesions were treated with two eye drops of  $\alpha$ -MSH (SYSMEHFRWGKPV, >97% purity<sup>7</sup> administered in 10 seconds intervals, at 0, 2, 8 and 16 hours after the injury. The following eye drop concentrations were used: 1 mg/mL,  $1 \times 10^{-1}$  mg/mL,  $1 \times 10^{-2}$  mg/mL,  $1 \times 10^{-3}$

mg/mL,  $1 \times 10^{-4}$  mg/mL. The control group was treated with 0.9% NaCl (1 drop = 0.05 mL).

*Evaluation and scoring of corneal lesions and ocular irritation*

The healing of corneal lesions was scored after the initial abrasion using a modified Draize test<sup>6,8</sup>. Originally, Draize test is used to score the advancement of a lesion after application of an irritant. In this experiment we have reversed the method. The score was calculated as follows: score 0 for no corneal lesion detected, score 1 for 0–25%, score 2 for 25–50%, score 3 for 50–75% and score 4 for 75–100% of initial lesion surface still not healed. The relative size of each lesion was compared to the whole surface of the cornea using image processing software (ImageJ). The intensity of conjunctival irritation was described by numbers, from 1 (for a minimal) to 10 (for a maximal irritation as seen in saline treated eyes). The mean of the left and right eye score was used.

*Data analysis*

Statistical analysis and comparison of control and treated groups was performed with Steel’s test – a non-parametric version of Dunett’s test. The analysis was made by using KyPlot software (version 4.0) and Graph-Pad Prism software (version 5.0).

**Results**

Five groups of experimental animals were treated with  $\alpha$ -MSH drops in the following range of concentrations: 1 mg/mL,  $1 \times 10^{-1}$  mg/mL,  $1 \times 10^{-2}$  mg/mL,  $1 \times 10^{-3}$  mg/mL and  $1 \times 10^{-4}$  mg/mL. The control group was treated with 0.9% NaCl drops.

$\alpha$ -MSH concentrations in the range from 1 mg/1 mL to  $1 \times 10^{-3}$  mg/mL did not significantly affect the rate of corneal healing (Table 1). The peptide concentration of  $1 \times 10^{-4}$  mg/mL significantly promoted epithelial healing in rat corneas when compared to the control group, 16

**TABLE 1**  
EFFECTS OF DIFFERENT CONCENTRATIONS OF  $\alpha$ -MSH ON THE HEALING OF CORNEAL EPITHELIAL DEFECTS 2, 8, 16 AND 24 HOURS AFTER ABRASION (DESCRIPTIVE STATISTICS)

Control (0.9% NaCl)	N	$\bar{X}$	Median	Min	Max	Q1	Q3	SD	Steel test
2 h	8	99.8	101.4	60.6	140.6	87.1	109.9	24.2	
8 h	8	68.9	70.1	22.3	92.6	65.0	83.0	21.5	
16 h	8	43.7	38.2	16.8	84.0	29.3	56.9	22.6	
24 h	8	16.3	14.0	2.7	49.0	7.6	17.9	14.2	
Alpha-MSH ( $1 \times 10^{-4}$ mg/mL)	N	$\bar{X}$	Median	Min	Max	Q1	Q3	SD	p value
2 h	6	75.7	72.5	53.4	110.5	70.6	74.8	18.8	0.608
8 h	6	62.1	57.4	52.1	89.6	52.4	63.5	14.4	>0.999
16 h	6	10.4	5.8	3.5	25.2	4.5	17.45	8.9	0.008
24 h	6	0.1	0.0	0.0	0.6	0.3	0.6	0.2	0.007
Alpha-MSH ( $1 \times 10^{-3}$ mg/mL)	N	$\bar{X}$	Median	Min	Max	Q1	Q3	SD	p value
2 h	6	78.5	78.8	58.8	99.6	68.1	86.7	14.2	>0.999
8 h	6	66.9	70.9	42.7	85.3	56.4	75.3	15.3	>0.999
16 h	6	24.9	23.5	7.6	42.1	10.1	38.5	14.2	>0.999
24 h	6	1.2	0.0	0.0	5.2	0.00	3.7	2.1	0.001
Alpha-MSH ( $1 \times 10^{-2}$ mg/mL)	N	$\bar{X}$	Median	Min	Max	Q1	Q3	SD	p value
2 h	6	85.4	85.8	69.4	103.5	76.4	91.4	12.1	>0.999
8 h	6	57.0	58.2	43.3	68.4	51.9	62.2	8.7	>0.999
16 h	6	20.2	19.8	8.2	36.8	8.5	27.9	11.1	0.695
24 h	6	13.4	10.7	3.9	31.1	5.1	24.5	9.9	0.996
Alpha-MSH ( $1 \times 10^{-1}$ mg/mL)	N	$\bar{X}$	Median	Min	Max	Q1	Q3	SD	p value
2 h	6	88.3	93.0	65.7	102.9	72.3	102.8	16.3	>0.999
8 h	6	73.3	77.2	45.0	92.0	61.2	87.1	17.5	>0.999
16 h	6	31.0	29.6	10.6	50.8	18.3	47.3	16.6	>0.999
24 h	6	19.5	19.4	0.0	42.0	4.5	34.6	14.6	0.996
Alpha-MSH (1mg/mL)	N	$\bar{X}$	Median	Min	Max	Q1	Q3	SD	p values
2 h	6	9.0	113.8	73.4	138.1	95.3	119.7	22.2	>0.999
8 h	6	75.7	77.9	50.6	91.1	74.5	82.1	13.7	>0.999
16 h	6	24.6	24.3	13.9	41.3	14.9	28.8	10.2	>0.999
24 h	6	17.3	18.7	5.2	25.6	7.8	25.4	8.2	0.853

Alpha-MSH – alpha-melanocyte stimulating hormone

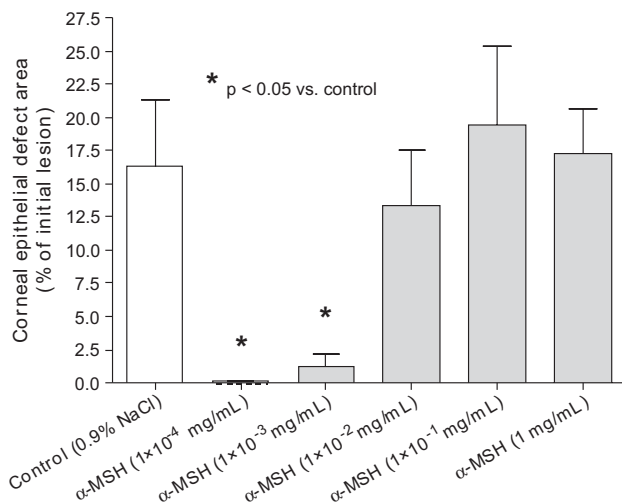


Fig. 1. Healing of corneal defects – percentage of the initial lesion after 24 hours.  $\alpha$ -MSH – alpha-melanocyte stimulating hormone.

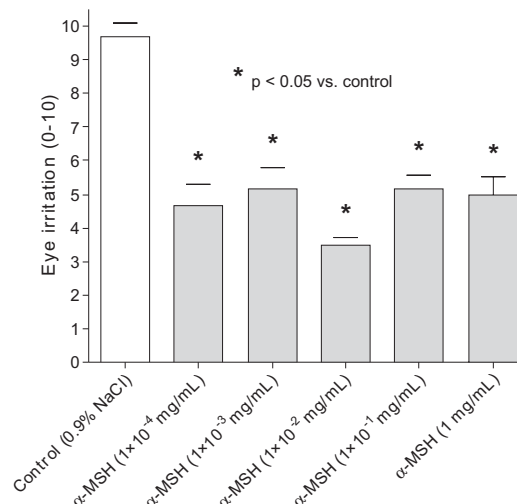


Fig. 2. Ocular irritation in  $\alpha$ -MSH treated groups and controls 16 hours after epithelial abrasion.  $\alpha$ -MSH – alpha-melanocyte stimulating hormone.

and 24 hours after epithelial abrasion (Table 1, Figure 1).  $\alpha$ -MSH concentration of  $1 \times 10^{-3}$  mg/mL was also effective 24 hours after epithelial abrasion (Table 1, Figure 1). Compared to the animals treated with 0.9% NaCl drops  $\alpha$ -MSH drops elicited a significant reduction of conjunctival hyperemia in all treated groups 16 hours after corneal abrasion ( $p < 0.05$ , Table 2, Figure 2).

**TABLE 2**  
EFFECTS OF  $\alpha$ -MSH ON OCULAR IRRITATION 16 HOURS AFTER EPITHELIAL ABRASION (INTENSITY SCORE FROM 1 FOR MINIMAL TO 10 FOR MAXIMAL CONJUNCTIVAL HYPEREMIA)

Substance	$\bar{X}$	SD	Median	Steel test (p)
Control 0.9% NaCl	9.7	1.22	10.0	
$\alpha$ -MSH 1 mg/mL	4.7	1.50	4.0	0.007
$\alpha$ -MSH $1 \times 10^{-4}$ mg/mL	5.2	1.47	5.5	0.007
$\alpha$ -MSH $1 \times 10^{-3}$ mg/mL	3.5	0.55	3.5	0.006
$\alpha$ -MSH $1 \times 10^{-2}$ mg/mL	5.2	0.98	5.5	0.007
$\alpha$ -MSH $1 \times 10^{-1}$ mg/mL	5.0	1.27	4.5	0.007

$\alpha$ -MSH – alpha-melanocyte stimulating hormone

## Discussion

Integrity of ocular surface epithelium and corneal re-epithelization is vital for normal hydration and transparency of the cornea. It may therefore have influence on visual function and present a key process in prevention of corneal and intraocular infection<sup>9</sup>. During the healing process the migration and proliferation of the corneal epithelium takes place. Simultaneously, activation of different growth factors as well as some cytokines occurs as part of an inflammatory reaction<sup>10</sup>. Inflammatory and immunological reactions inside the cornea may cause fi-

brosis which could subsequently reduce corneal transparency and lead to blindness. Corticosteroids applied locally have a beneficial effect on fibrosis prevention after injury. However, they also inhibit wound healing and thus can not be used until the integrity of the ocular surface is re-established. Moreover, they have a number of known side effects such as ocular hypertension, glaucoma, cataract formation, epithelial toxicity, crystalline keratopathy, decreased wound strength and therefore they should be applied very cautiously<sup>11,12</sup>.

Although several substances have been reported to improve the corneal healing rate<sup>6,12</sup>, it is still necessary to search for substances that could facilitate corneal re-epithelization and prevent fibrosis at the same time. Besides the observed beneficial effects on corneal epithelization and irritation,  $\alpha$ -MSH is known to play an important role as a mediator of immunoregulatory and immunosuppressive processes which occur in the aqueous humor<sup>13</sup>. In anti-inflammatory reactions  $\alpha$ -MSH is involved by suppression of prostaglandin E2 (PGE2), tumor necrosis factor- $\alpha$  (TNF- $\alpha$ ), interleukin-1 (IL-1), interleukin-6 (IL-6) and monocyte chemotactic protein-1 (MCP-1) production as well as by blocking cyclo-oxygenase-2 (COX-2) expression<sup>14</sup>. Furthermore, it may also be useful as an anti-inflammatory agent in ocular trauma treatment maintaining blood-aqueous barrier integrity as opposed to steroids<sup>14</sup>. After penetrating corneolimb cut systemic and topical treatment with  $\alpha$ -MSH in rabbits equal or better results in reducing intraocular inflammatory reactions compared to topical application of corticosteroids were shown<sup>15</sup>. In the same animal model its hypotensive ocular effect with sustained reduction of intraocular pressure after a single topical application was also established<sup>16</sup>. Moreover, the local subconjunctival treatment with  $\alpha$ -MSH reduced allojection of rat corneal grafts<sup>17</sup>.

Our investigation demonstrates that topical application of  $\alpha$ -MSH could facilitate hyperemia and promote re-epithelization of the cornea in rats without significant side effects. However, the influence on the corneal epithelium healing was dose dependent with observed statistically significant influence at a concentration of  $1 \times 10^{-4}$  mg/mL of  $\alpha$ -MSH. This is in accordance with the fact that  $\alpha$ -MSH induced ocular hypotensive effect is also dose dependent<sup>15,16</sup> just as its activity in the nervous system<sup>18</sup>, skin<sup>19</sup> and its influence as an anti-inflammatory agent<sup>20</sup>. The favorable hypotensive effect of  $\alpha$ -MSH on intraocular pressure was achieved with aqueous physiological doses ( $10^{-8}$  M –  $10^{-9}$  M)<sup>15</sup>. Our results are consistent with the data of Naveh et al.<sup>15,16</sup> since we observed that two most efficient doses with respect to the corneal wound healing ranged from  $6 \times 10^{-8}$  M ( $1 \times 10^{-3}$  mg/mL) to  $6 \times 10^{-9}$  M ( $1 \times 10^{-4}$  mg/mL). In some previous studies  $\alpha$ -MSH was used in higher non-physiological doses causing flare and increased values of intraocular pressure after its application<sup>21,22</sup>. Considering that these values were far greater than the physiological it is reasonable to conclude that we could benefit only if the doses close to the physiological ones in the aqueous humor are applied<sup>15,16</sup>. The possible topical application of  $\alpha$ -MSH could provide an advantage when compared to some long-established but more aggressive methods that have proven to facilitate corneal epithelial healing<sup>23</sup>.

In summary, we have demonstrated that topical  $\alpha$ -MSH medication could promote the healing of corneal

wounds and simultaneously reduce the inflammatory response without the major side effects of corticosteroid therapy. Further studies are therefore necessary to determine the most effective doses with the longest and most permanent outcome with minimal relapses. Thus we can suggest that  $\alpha$ -MSH could be considered as a possible future therapy for corneal defects.

## Conclusions

$\alpha$ -MSH concentration of  $1 \times 10^{-4}$  mg/mL significantly promoted epithelial healing in rat corneas when compared to the control group, at 16 hours and 24 after epithelial abrasion.

Compared to the animals treated with with 0.9% NaCl,  $\alpha$ -MSH drops elicited a significant reduction of ocular irritation in all treated groups 16 hours after corneal abrasion.

Topical  $\alpha$ -MSH medication promotes the healing of corneal wounds and reduces local irritation and inflammation.

## Acknowledgements

The support by the Ministry of Science, Education and Sports, Republic of Croatia is thankfully acknowledged (Grant No. 098-0982929-2524).

## REFERENCES

1. BRZOSKA T, LUGER TA, MAASER C, ABELS C, BÖHM M, Endocr Rev, 29 (2008) 581. DOI: 10.1210/er.2007-0027. — 2. GETTING SJ, Pharmacol Ther, 111 (2006) 1. DOI: 10.1016/j.pharmthera.2005.06.022. — 3. ZIANGIROVA GG, BOCHAROV VE, MALAEVA LV, OLINOVICH VB, SHERSTNEV VV, Vestn Oftalmol, 113 (1997) 26. — 4. LIPTON JM, CATANIA A, Immunol Today, 18 (1997) 140. DOI:10.1016/S0167-5699 (97)01009-8 — 5. CUTULI M, CRISTIANI S, JAMES M, LIPTON JM, CATANIA A, J Leukoc Biol, 67 (2000) 233. — 6. KONJEVODA P, NASIĆ M, ČURKOVIĆ T, SIKIRIĆ P, SEIWERTH S, ŠTAMBUK N, Effects of BPC 157 on the healing of corneal lesions. In: OHNO S, AOKI K, USUI M, UCHIO E (Eds) Uveitis Today (Elsevier, Amsterdam, The Netherlands (1998)). — 7. KONJEVODA P, ŠTAMBUK N, ARALICA G, POKRIĆ B, J Physiol - Paris, 95 (2001) 277. DOI: 10.1016/S0928-4257(01)00038-9. — 8. DRAIZE JH, WOODARD G, CALVERY H, J Pharmacol Exp Therap, 82 (1944) 377. — 9. KLENKLER B, SHEARDOWN H, Exp Eye Res, 79 (2004) 677. DOI: 10.1016/j.exer.2004.07.008. — 10. LU L, REINACH PS, KAO WW, Exp Biol Med, 226 (2001) 653. — 11. BARBA KR, SAMY A, LAI C, PERLMAN JI, BOUCHARD CS, J Cataract Refract Surg, 26 (2000) 893. DOI: 10.1016/S0886-3350(00)00364-3. — 12. MCGHEE CN, DEAN S, DANESH-MEYER H, Drug Saf, 25 (2002) 33. DOI: 10.2165/00002018-

- 200225010-00004. — 13. TAYLOR AW, Chem Immunol Allergy, 92 (2007) 71. — 14. ZIESKE JD, GIPSON IK, Agents that affect corneal wound healing: modulation of structure and function. In: ALBERT DM, JAKOBIEC FA (Eds) Principles and Practice of Ophthalmology and Basic Sciences (WB Saunders, Philadelphia, USA, 1994). — 15. NAVEH N, MARSHALL J, Graefes Arch Clin Exp Ophthalmol, 239 (2001) 840. DOI: 10.1007/s00417-001-0379-1. — 16. NAVEH N, KAPLAN-MESSAS A, MARSHALL J, Br J Ophthalmol, 84 (2000) 1411. DOI: 10.1136/bjo.84.12.1411. — 17. HAMRAH P, HASKOVA Z, TAYLOR AW, ZHANG Q, KSANDER BR, DANA MR, Transplantation, 88 (2009) 180. DOI: 10.1097/TP.0b013e3181ac11ea. — 18. CERIANI G, MACALUSO A, CATANIA A, LIPTON JM, Neuroendocrinology, 59 (1994) 138. DOI: 10.1159/000126650. — 19. HUNT G, Pathobiology, 63 (1995) 12. — 20. MACALUSO A, MCCOY D, CERIANI G, WATANABE T, BILTZ J, CATANIA A, LIPTON JM, J Neurosci, 14 (1994) 2377. — 21. HERNANDEZ DE, SIMONS KB, SPAMPIATO D, PEIFFER RLJ, DRAGO F, Neuropeptides, 6 (1985) 553. DOI: 10.1016/0143-4179(85)90118-0. — 22. MCCULLEN RK, PEIFFER RL, JENNES L, HERNANDEZ DE, Neuropeptides, 12 (1988) 213. DOI: 10.1016/0143-4179(88)90057-1 — 23. DEKARIS I, MRVIC I, BARISIC A, DRACA N, PAUK M, Coll Antropol, 34 (2010) Suppl 2 15.

J. Pavan

University of Zagreb, Dubrava University Hospital, Department of Ophthalmology, Avenija Gojka Šuška 6, 10000 Zagreb, Croatia.

e-mail: josip.pavan@zg.htnet.hr

## DJELOVANJE $\alpha$ -MSH NA OŠTEĆENJA EPITELA ROŽNICE U ŠTAKORA

### S A Ž E T A K

Istraživali smo utjecaj alfa-melanostimulirajućeg hormona ( $\alpha$ -MSH) na cijeljenje epitelnih oštećenja rožnice u mužjaka Wistar štakora. Lezije su izazvane abrazijom epitela rožnice kirurškom lancetom pod kontrolom biomikroskopa. Prije abrazije epitel je omekšan djelovanjem 40% etanola. Primjena  $\alpha$ -MSH kapi u koncentraciji od  $1 \times 10^{-4}$  mg/mL značajno pospješuje cijeljenje epitela u usporedbi s kontrolnom grupom liječenom kapima 0,9% NaCl uz značajno smanjenje hiperemije oka. Lokalna primjena  $\alpha$ -MSH može pospješiti cijeljenje rana rožnice uz smanjenje lokalnog upalnog odgovora bez izraženijih nuspojava kortikosteroidne terapije.