

# Hernia of Morgagni – Case Report

Zvonko Zadro<sup>1</sup>, Ivan Frketić<sup>1</sup>, Zdenko Boban<sup>1</sup>, Ana Šoštarčić Zadro<sup>2</sup>, Jurica Fudurić<sup>1</sup>, Zoran Veir<sup>3</sup> and Zoran Jurjević<sup>2</sup>

<sup>1</sup> Karlovac General Hospital, Department of Surgery, Karlovac, Croatia

<sup>2</sup> Karlovac General Hospital, Department of Radiology, Karlovac, Croatia

<sup>3</sup> University of Zagreb, Zagreb University Hospital Center, Department of Plastic Surgery, Zagreb, Croatia

## ABSTRACT

*Morgagni's hernia is result of penetration of the abdominal contents into the chest through an anterior retrocosto-xiphoid defect in the anterior midline of the diaphragm. It can be manifested with symptoms since birth as a bloated feeling, nausea and belching after meals. We present a patient with symptomatic herniation of the torqued antral part of stomach and loops of the transverse colon. In our case, chest and abdominal radiography after oral intake of contrast are used to diagnose this condition. Herniation was reduced surgically by a transabdominal approach. At the control examination one year after surgery in our patient all symptoms have disappeared, and was given 15 kg of body weight.*

**Key words:** Morgagni's hernia, gastric volvulus, elderly

## Introduction

Morgagni's hernia is one of the diaphragmatic congenital hernias, in which due to inherent defect in the sternocostal hiatus of the diaphragm leads to prolapse of abdominal organs in to the chest cavity<sup>1,2</sup>. Congenital diaphragmatic hernia occurs in one over 3.000 newborns, of which 5-10% belongs to cases of Morgagni's hernia<sup>3-5</sup>.

Although it is a congenital disorder, the diagnosis is often placed in adult during pulmonary, or gastroenterological clinical examination accidentally, or as a condition that presents with symptoms caused by incarceration of abdominal organs within the hernia<sup>6-8</sup>.

To avoid complications, planned surgery is indicated by accidentally discovered hernia. An emergency operation is needed in the symptomatic hernias. Treatment consists of surgical closure of the defect with direct suture technique or synthetic materials. The surgery is performed by transabdominal or minimally invasive approach<sup>9-13</sup>.

## Case Report

We present a case of a woman aged 77 years that reports on the emergency department because of frequent nausea and vomiting that goes along with pain in upper abdomen for 10 days. Vomiting in jet after eating is one

of the symptoms. She also noticed loss of weight. Denies any trauma to her body.

Clinical examination determines that the patient had stable vital parameter. Auscultation of lung found diffusely impaired respiratory sounds, in epigastric there

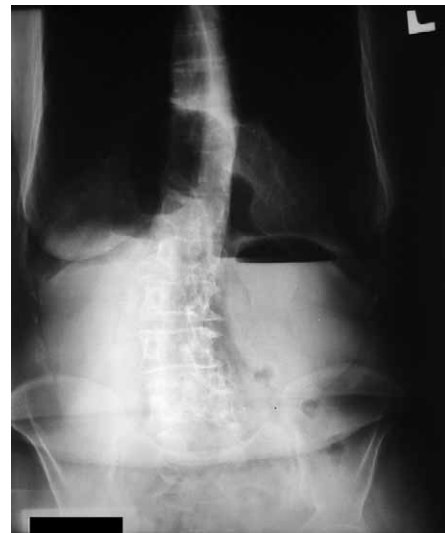

Fig. 1. Initial recorded plain abdominal X-ray picture standing.

could be heard blasting phenomenon. Abdomen is in the level of the chest, soft, painful on deep palpation in the upper parts. We didn't found any signs of peritoneal irritation. Peristalsis was audible.

In radiological examination we make plain abdominal radiography standing on which we didn't found free air under the diaphragm or air fluid levels in the gut. Diaphragm laid low, less reduced, with visible irregularly shaped, a distinct collection of air in the projection of the heart (Figure 1).

We requested a contrast oesophago-gastro-duodenal radiography. Examination is done with Gastrografin contrast medium in our case. Images showed that the corpus of the stomach is cranially oriented and that is injected intrathoracic through the diaphragm. Almost all antral part of stomach was located intrathoracic and funnel narrows as the point of volvulus (Figure 2). Prepyloric part of the stomach is not displayed. The recording performed 1 hour after contrast intake showed that the contrast passed through pylorus and a certain amount of contrast was found in loops of jejunum. Pylorus and duodenal bulb were placed intraabdominal and vertically oriented (Figure 3). After 6.5 hours after intake of contrast media on recordings present further herniation of the antrum and corpus of stomach intrathoracic with a larger amount of residual contrast media in intraabdominal located gastric fundus. It is also evident that in the hernia sack is located loop of the colon (Figure 4).

As clinical and radiological findings indicate in favor of volvulus of stomach in the diaphragmatic hernia, this was an indication for surgery. Upper median laparotomy was. It showed a hernia that is in front and on right of the midline and contains the entire torqued gastric antrum and one loop transverse colon. The content is released, whereby it is determined proper vitality of these organs. Hernia, which is 10 cm deep and 5 cm wide, is closed with running sutures. We also founded smaller

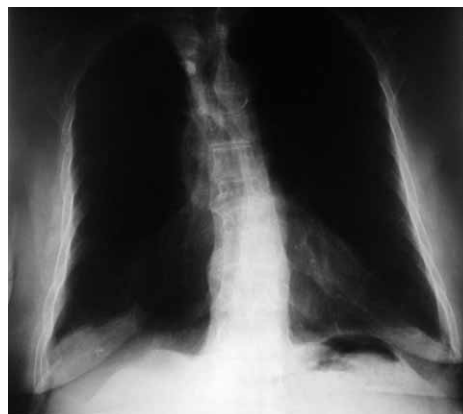


Fig. 5. Control X-ray picture after surgery.

hernia on the front of diaphragm, on the left side of the midline, which is stitched with simple sutures. Postoperative course was normal and 8 days after surgery the patient is released within normal general and local condition. Control X-ray pictures showed a normal intraabdominal status (Figure 5).

### Discussion and Conclusion

In the elderly the symptoms of gastrointestinal obstruction can be caused in rare cases by Morgagni's congenital diaphragmatic hernia<sup>6,8</sup>. Plain routine abdomen radiography and plain chest radiography may suggest to this unusual condition. Doubt requires further confirmed by additional radiologic studies<sup>14,15</sup>. In our case, herniation of the stomach and the loop of the colon was confirmed with the radiography after oral intake of contrast (Gastrografin). Given that this is a symptomatic condition, surgery was indicated. The importance of timely operative treatment is to prevent the development of complications.

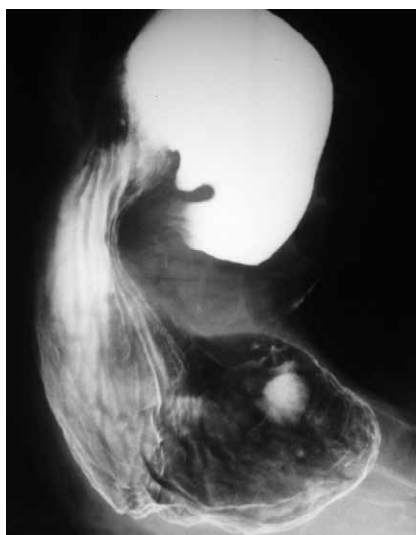


Fig. 2. The recording performed immediately after contrast intake.

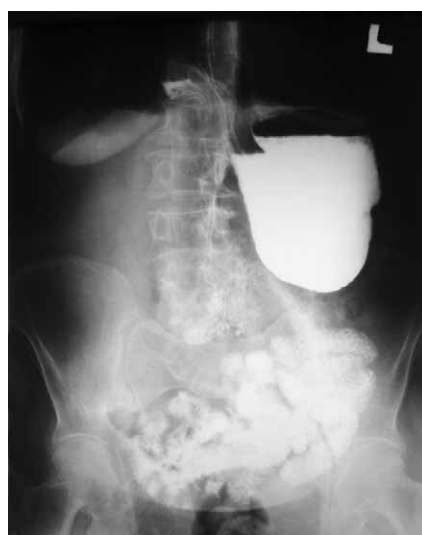

Fig. 3. The recording performed 1 hour after contrast intake.

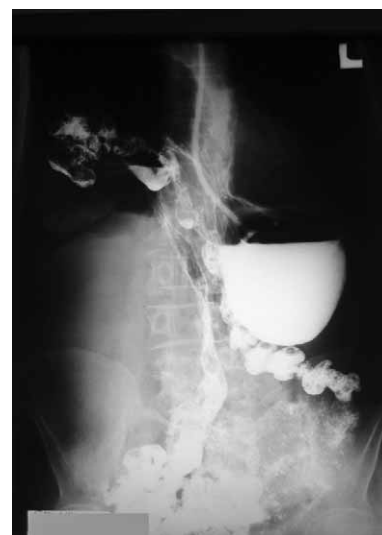

Fig. 4. Recording 6.5 hours after intake of contrast media.

## REFERENCES

1. IRISH MS, HOLM BA, GLICK PL, Clin Perinatol, 23 (1996) 625.
- 2. LOONG TPF, KOCHER HM, Postgrad Med J, 81 (2005) 41. DOI: dx.doi.org/10.1136/pgmj.2004.022996.
- 3. BUTLER N, CLAIREAUX AE, Lancet, 1 (1962) 659. DOI: 10.1016/S0140-6736(62)92878-7.
- 4. WOLLOCH Y, GRUNEBAUM M, GLANZ I, Am J Surg, 127 (1974) 601. DOI: 10.1016/0002-9610(74)90327-4.
- 5. BRAGG WD, BUMPERS H, FLYNN W, Am Fam Physician, 54 (1996) 2021.
- 6. SAKALKALE RP, SANKHE M, NAGRAL S, PATEL CV, J Postgrad Med, 37 (1991) 228.
- 7. NAUNHEIM KS, Chest Surg Clin N Am, 8 (1998) 359.
- 8. BARUT I, TARHAN OR, CERCI C, AKDENIZ Y, BULBUL M, J Thorac Imaging, 20 (2005) 220. DOI: 10.1097/01.rti.0000154078.59689.36.
- 9. CORNER TP, CLAGETT OT, J Thorac Cardiovasc Surg, 52 (1966) 461.
- 10. MOGHISSI K, Thorax, 36 (1981) 392. DOI: 10.1136/thx.36.5.392.
- 11. RAU HG, SCHARDEY HM, LANGE V, Surg Endosc, 8 (1994) 1439. DOI: 10.1007/BF00187355.
- 12. HUNTIGTON TR, J Laparoendosc Surg, 6 (1996) 131.
- 13. HUSSONG RL, JR, LANDRENEAU RJ, COLE FH, JR, Ann Thorac Surg, 63 (1997) 1474. DOI: 10.1016/S0003-4975(97)00216-6.
- 14. RAI SP, KAMATH M, SHETTY A, SHENOY S, KUMAR A, J Emerg Trauma Shock, 3 (2010) 89. DOI: 10.4103/0974-2700.58654.
- 15. MINNECI PC, DEANS KJ, KIM P, MATHISEN DJ, Ann Thorac Surg, 77 (2004) 1956. DOI: 10.1016/j.athoracsur.2003.12.028.

Z. Zadro

Karlovac General Hospital, Department of surgery, Dr. Andrije Štampara 3, 47000 Karlovac, Croatia  
e-mail: zvonko.zadro@zg.htnet.hr

## MORGAGNIJEVA HERNIJA

### SAŽETAK

Morgagnijeva hernija označava prodor intraabdominalnih organa u prsište kroz otvor u prednjem dijelu ošita. Može se manifestirati simptomatskim tegobama od rođenja kao osjećaj nadutosti, mučnine i podrigivanja nakon obroka. Prikazujemo pacijenticu s hernijacijom torkviranog antruma želuca te vijuge transverzalnog kolona. U našem slučaju, za dijagnostiku tog stanja korištene su rentgenske snimke prsnih organa i trbuha nakon peroralnog unosa kontrastnog sredstva (Gastrografin). Hernijacija je razriješena kirurški, transabdominalnim pristupom. Na kontrolnom pregledu godinu dana nakon operativnog zahvata kod naše pacijentice sve tegobe su nestale te je dobila 15 kg na tjelesnoj težini.