

An Exceptional Case of Dental Calculus in a Merovingian Skeleton from Mannheim-Seckenheim

• Hansen JL, Alt KW •

Johannes Gutenberg Universität, Institut für Anthropologie, Bioarchaeometry Group, Mainz, Germany

Address for correspondence:

Univ. Prof. Kurt Werner Alt Mail
Johannes Gutenberg Universität
Institut für Anthropologie, Bioarchaeometry Group
Fachbereich 10 (1050)
Colonel-Kleinmann-Weg 2 (SBII)
D-55099 Mainz, Germany
E-mail: altkw@uni-mainz.de

Bull Int Assoc Paleodent. 2012;6(2):70-76.

Abstract

The remains of an individual from grave 595 of the Merovingian cemetery at Mannheim-Seckenheim, excavated between 2001 and 2004, displays extreme deposits of dental calculus. The 1st and 2nd upper right molars of the male aged 50+ were the most affected and almost completely encased by the deposits. The substantial calculus accumulation might be ascribed to the antemortem loss of the occluding teeth which would have rendered normal mastication impossible. Invasive tests to analyse the formation and element composition of the deposits might indicate endogenous factors to be the cause for this oral dysfunction. Aside from the calculus severe dental caries, abrasion, and periodontal disease (particularly periapical defects) were observed. Although there are similar instances of considerable dental calculus in archaeological human remains, this individual is an exceptional case within the Mannheim-Seckenheim assemblage.

Keywords: Dental Calculus; Oral Pathology; Early Medieval

Introduction

Calculus is mineralized plaque adhering to tooth surfaces (1-3). Cement-like in hardness, calculus deposits can be found above (supragingival) and below (subgingival) the gum line (3). Subgingival calculus seems to be correlated with loss of attachment and periodontitis (1, 3-4). Calculus is composed of an inorganic and an organic component; the former comprises 80-85% of the mass and consists mainly of calcium and phosphorus similar to hydroxyapatite (HAP), the main component of

enamel and bone (1, 3, 5). Aside from HAP other phosphate salts, such as whitlockite, octocalcium phosphate (OCP) or dicalcium phosphate dihydrate (DCPD), can be found in calculus deposits (1, 3, 6). The organic constituent consists of carbohydrates, amino-acids, peptides, proteins, and lipids. Calculus deposits are usually covered by a non-mineralized plaque (1, 6). This layer of plaque is comprised of bacteria and an extra-cellular matrix. Common bacteria found in this plaque are Streptococci and Actinomycetes (6).

The process of calculus formation starts with the deposition of the pellicle, an organic layer, on the tooth surfaces. Microorganisms, especially bacteria, colonize the pellicle and form the dental plaque (1, 6). These bacteria are embedded in a matrix made up of proteins and products of the bacteria. During the mineralization process, calcium phosphate crystals, originating from saliva and crevicular fluids, are deposited into the plaque matrix. Prerequisite for the precipitation is a supersaturation of calcium phosphate crystals in the plaque fluid (3).

A few factors, such as the concentrations of mineral ions in the saliva (7) or those of silicones in the diet (8) influence the formation of calculus. Due to the influence of these factors in the formation process, the chemical composition of calculus is highly variable (3).

As the mineral salts making up the calculus deposit originate mainly from the saliva, the areas close to the excretory ducts of the salivary glands (the lingual surfaces of mandibular anterior teeth and the buccal surfaces of the maxillary molars) are increasingly affected by calculus (9).

Materials and methods

The burial site of Bösfeld is situated in the Rhine Neckar Triangle in Seckenheim, a district of the city of Mannheim (see Figure 1). The cemetery was in use from the early 6th to the late 8th century. Over the time, more than 900 people were interred in Bösfeld (10-11). The cemetery is probably associated with the nearby village Hermsheim (10). Hermsheim represents one of the settlements that were founded in the course of Frankish expansionism into regions east of the Rhine. The village disappeared during the early 13th century and was rediscovered in 1933/34 and excavated under the supervision of Hermann Gropengießer (13). The cemetery of Bösfeld was initially discovered in 1906/07 although the main excavation took place between 2001 and 2004 by the Reiss-Engelhorn-Museen.

The individual examined for this study comes from grave 595 and displays considerable deposits of dental calculus. Both mandibular and maxillary dentitions were available for examination. Using standard aging and sexing methods (14-16) remains were identified to be those of a male at least 50 years old at the time of death.

Description

The maxillary and mandibular dentitions were examined by means of macroscopic and radiographic methods. In total nine teeth were recovered and could be examined. The dentition consists of the complete right maxillary arch and both left mandibular premolars. The rest of the mandibular dentition was lost due to antemortem tooth loss (AMTL) while some of the teeth of the left maxillary arch were lost antemortem and others postmortem (PMTL, see Figures 2 and 3). Dental calculus is present in varying degrees on all maxillary teeth while the two mandibular teeth are free of such deposits. Teeth 16 and 17 exhibit particularly large accumulations, almost dwarfing the teeth themselves (see Figures 3 A and 4), although that on 17 was damaged postmortem. Buccal (and partly occlusal) surfaces are those most affected on these two teeth.

The corresponding teeth of the mandible were lost antemortem so that a reduction of calculus due to masticatory processes did not occur. The calculus deposits are mostly supragingival but small subgingival accretions are apparent on 13, 14, and 16. The surface of the calculus is porous but there are areas with smooth surfaces interdentally. The largest deposit is located on tooth 16 and its buccal surface possesses a convex curvature which seems to mirror the inside of the cheek. This accumulation is 24.33 mm high x 23.37 mm wide x 12.38 mm deep.

All teeth display moderate to severe wear. That of tooth 16 is severe with complete loss of the lingual crown. Periodontal disease in the forms of alveolar resorption and profound guttering is apparent on both jaws (see Table 1). In teeth 16 and 17 the distance between the cemento-enamel junction (CEJ) and alveolar crest is increased due to considerable alveolar resorption. The tooth sockets are almost completely compromised due to periodontal disease so that the teeth were held in place mostly by the gingiva and possibly the calculus itself.

Periapical lesions are present on five of the sites where teeth were lost antemortem (see Table 1). An especially large defect is present at position 36 (see Figure 5). Of the nine remaining teeth, caries are only present on one. The crown of 15 is completely destroyed by caries and the pulp chamber is exposed (see Figure 3 A). This led to an infiltration of bacteria into the pulp chamber and ultimately to the formation of a periapical lesion in the surrounding bone. The remaining teeth are not affected by caries, although especially in teeth 16 and 17 the calculus deposits prevent an examination of some of the tooth surfaces.

Discussion

The combination of all these observed pathologies (calculus, caries, periodontal disease and AMTL) indicate poor oral health of the individual from grave 595. The insufficient bony support of teeth 16 and 17, formation of calculus even on their occlusal surfaces, and absence of occlusal dentition indicate that the teeth were not used for mastication for some time before death.

Dietary composition is one factor in the formation of calculus but not the predominant one. Oral

microorganisms mainly obtain their nutrients from the oral fluids and not from the diet that periodically passes the oral cavity (1-2). Still, diet does indirectly affect the oral pH. An increased protein intake leads to an elevated blood urea level which indirectly results in increased oral fluid urea levels. Oral microorganisms metabolize urea thus increasing alkalinity. These alkaline conditions in turn promote further calculus formation. Therefore diets high in protein can encourage calculus formation (1). Aside from diet many factors like individual variation of phosphate/calcium levels in saliva, salivary flow rate, fluid consumption, and mechanical properties of diet also influence calculus formation (1,2, 17).

Conclusions

The individual's inability to masticate made normal consumption of food difficult if not impossible. This suggests that the consistency of the individual's diet was probably paste-like or even liquid. The lack of mastication then led to the accretion of more and more calculus. Poor oral hygiene contributed to the heavy calculus formation. The accumulation of calculus deposits this size may have taken years to form with the individual likely being care-dependent.

Acknowledgements

We are grateful to the Institut für Rechtsmedizin in Mainz for access to their x-ray equipment. Also, we thankfully acknowledge Dr. Johanna Morgan for her input to this study.

References

1. Lieveverse AR. Diet and the aetiology of dental calculus. *Int J Osteoarchaeol.* 1999;9:219-232
2. Hillson S. *Dental anthropology.* Cambridge University Press; 2002.
3. White DJ. Dental calculus: recent insights into occurrence, formation, prevention, removal and oral health effects of supragingival and subgingival deposits. *Eur J Oral Sci.* 1997;105(5 Pt 2):508-522
4. Whittaker DK, Molleson T, Nuttall T. Calculus deposits and bone loss on the teeth of Romano-British and eighteen-century Londoners. *Arch Oral Biol.* 1998;43(12):941-8
5. Capasso L, Di Tota G, Jones KW, Tuniz C. Synchrotron radiation microprobe analysis of human dental calculi from an archaeological site: a new possible perspective in palaeonutrition studies. *Int. J. Osteoarchaeol.* 1995;5:282-288
6. Greene TR, Kuba L, Rish JD. Quantifying calculus. A suggested new approach for recording an important indicator of diet and dental health. *Homo.* 2005;56(2):119-132
7. Mandel I D. Biochemical aspects of calculus formation I. *J. Periodont. Res.* 1974 a;9:10-17
8. Hidaka S, Okamoto Y, Abe K. Possible regulation roles of silicic acid, silicia and clay minerals in the formation of calcium phosphate precipitates. *Archs. oral. Biol.* 1993;38(5):405-413
9. Hellwig E, Klimek J, Attin T. *Einführung in die Zahnerhaltung.* München - Wien - Baltimore: Urban & Schwarzenberg Verlag; 1995.
10. Link T. Zwischen Adlern und Hamstern: fränkische Gräber im Hermsheimer Bösfeld, Mannheim-Seckenheim. *Archäologische Ausgrabungen in Baden-Württemberg.* 2002;163-176
11. Koch U. Das Merowingerzeitliche Gräberfeld im Hermsheimer Bösfeld, Mannheim-Seckenheim. *Archäologische Ausgrabungen in Baden-Württemberg.* 2003;155-157.
12. d-maps.com; 2007-2012 [accessed 2012 Aug 24] Deutschland/Bundesrepublik Deutschland, Grenzen, Flüsse,

Landeshauptstädte. Available from: http://d-maps.com/carte.php?num_car=4694&lang=de

13. Wirth K, Koch U, Rosendahl W. Tatort Bösfeld. Die Entdeckung eines sensationellen Gräberfeldes. *Badische Heimat*. 2007;87:166-176

14. Phenice TW. A newly developed visual method of sexin the os pubis. *Am J Phys Anthropol*. 1969;30:297-302

15. Rösing FW, Graw M, Marré B, Ritz-Timme S, Rothschild MA, Röttscher K, Schmeling A, Schröder I, Geserick G. Empfehlungen für die forensische Geschlechts- und Altersdiagnose am Skelett. *Rechtsmedizin*. 2005;15(1):32-38

16. Lovejoy CO. Dental wear in the libben population: its funtional pattern and role in the determination of adult skeletal age at death. *Am J Phys Anthropol*. 1985;68:47-56.

17. Dawes C. Effects of diet on salivary secretion and composition. *J Dent Res*. 1970;49(6):1263-73.

| | 18 | 17 | 16 | 15 | 14 | 13 | 12 | 11 | 21 | 22 | 23 | 24 | 25 | 26 | 27 | 28 |
|-----|----|----|----|----|----|----|----|----|----|----|----|----|----|----|----|----|
| CAL | | + | + | + | + | + | + | + | | | | | | | | |
| PER | | + | + | + | + | + | | | | + | + | + | + | - | - | |
| PL | | - | - | + | - | - | | | - | + | - | | - | - | - | |
| PL | - | - | - | - | - | - | | | | + | + | - | - | + | - | - |
| PER | + | + | + | + | + | + | | | | | | + | + | + | + | + |
| CAL | | | | | | | | | | | | | - | - | | |
| | 48 | 47 | 46 | 45 | 44 | 43 | 42 | 41 | 31 | 32 | 33 | 34 | 35 | 36 | 37 | 38 |

Table 1. distribution of dental pathologies with CAL: calculus, PER: periodontal disease, and PL: periapical lesion; +: present, -: absent

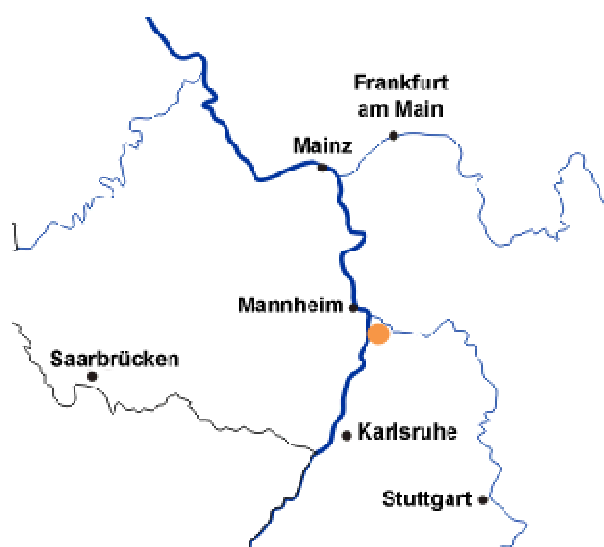

Figure 1 map showing Rhine-Main-Neckar region, orange dot: location of Bösfeld cemetery, modified after (12)

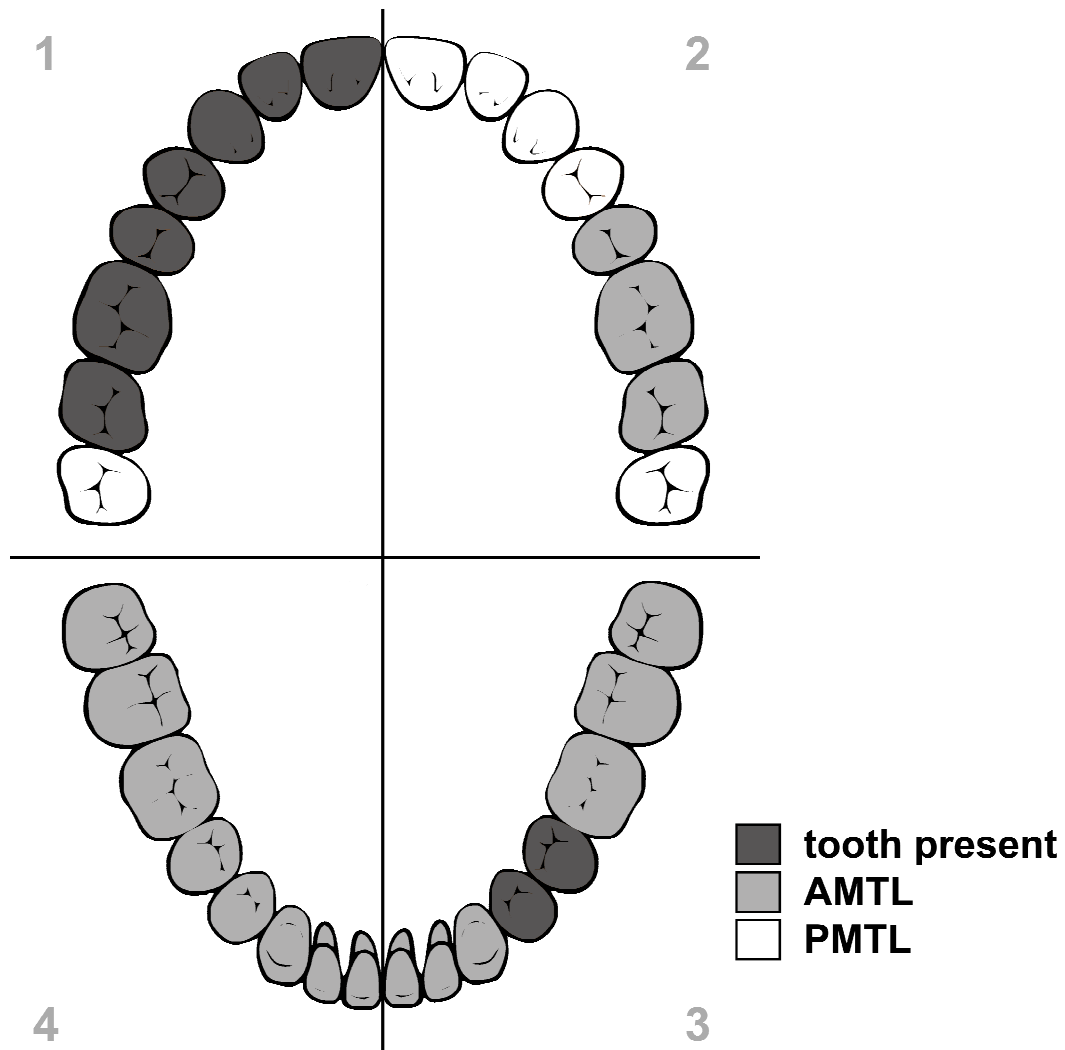


Figure 2 remaining teeth of grave 595 with teeth present, teeth lost intra vivam and teeth lost postmortem, numbering per the FDI system

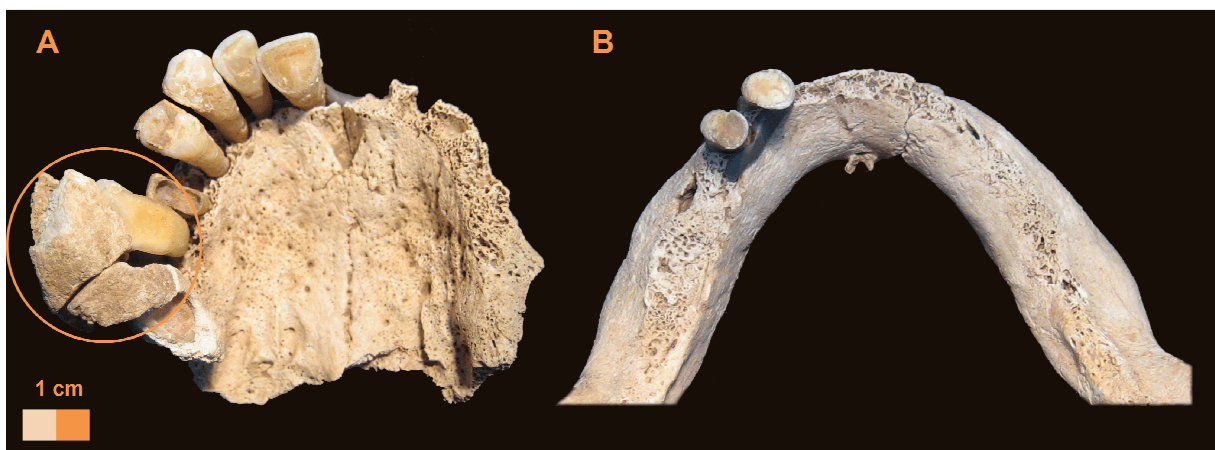


Figure 3 A occlusal view of maxillae, framing: severe calculus accumulation on 16 and 17. B. occlusal view of the mandible

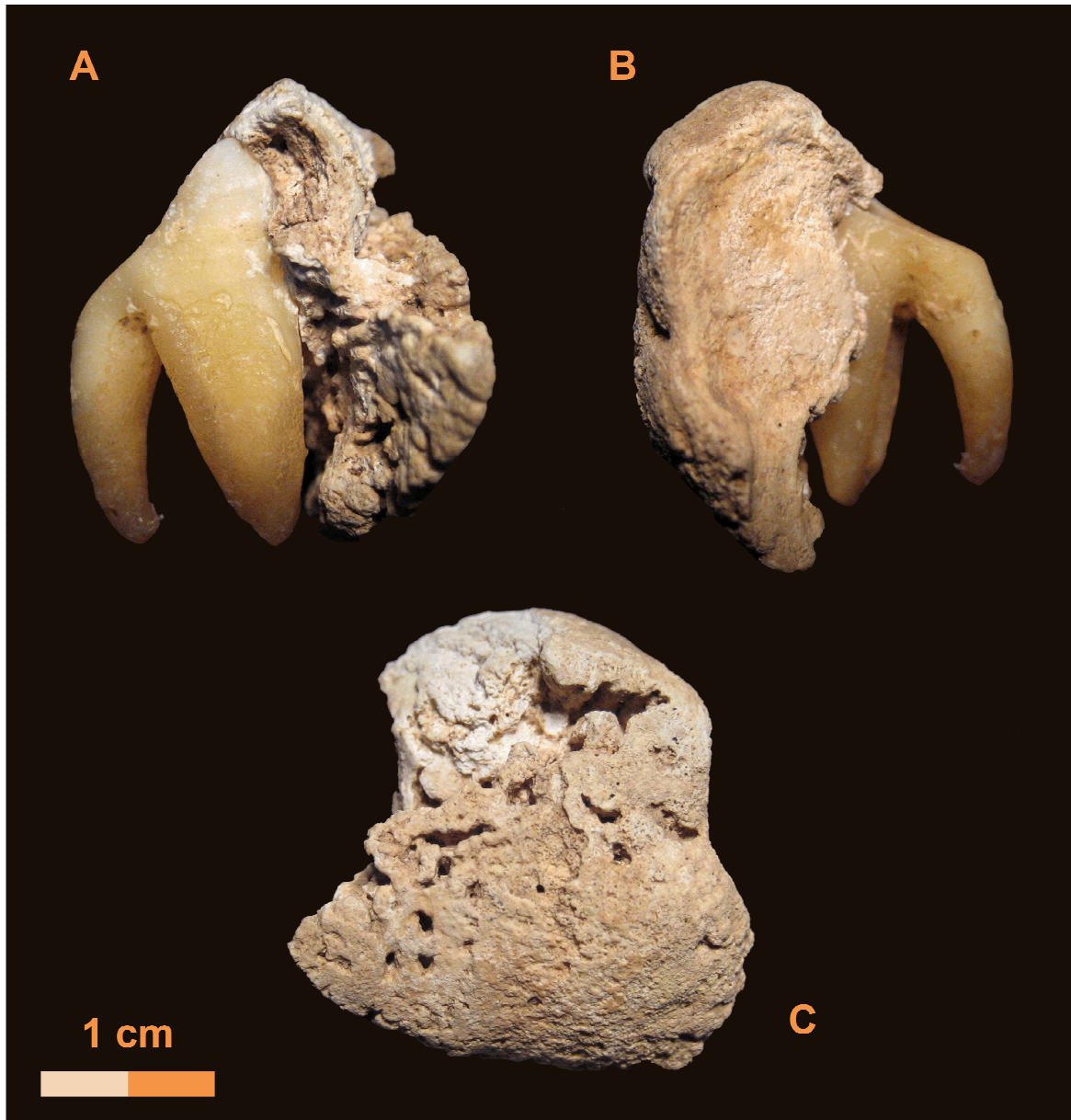


Figure 4 calculus deposits on tooth 16. A: mesial view, B: distal view, C: buccal view

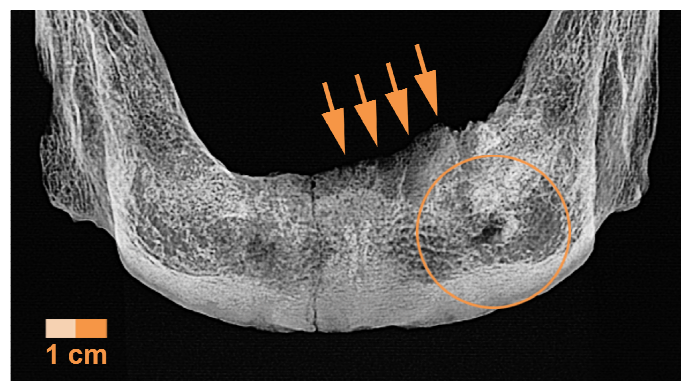


Figure 5 radiograph of anterior mandible, framing: periapical lesion, arrows: alveolar resorption and guttering