

# The Value of Serum Thyreoglobulin Levels and Whole Body (I-131) Scintigraphy in the Follow-Up of the Thyroid Cancer Patients after Thyroidectomy

Elma Kućukalić-Selimović<sup>1</sup>, Jasminka Alagić<sup>2</sup>, Amina Valjevac<sup>3</sup>, Almira Hadžović-Džuvo<sup>3</sup>, Amela Begić<sup>1</sup> and Nermina Bešlić<sup>1</sup>

<sup>1</sup> Clinical Center University of Sarajevo, Clinic for Nuclear Medicine, Sarajevo, Bosnia and Herzegovina

<sup>2</sup> Clinical Center University of Sarajevo, ENT Clinic, Sarajevo, Bosnia and Herzegovina

<sup>3</sup> University of Sarajevo, School of Medicine, Department of Physiology, Sarajevo, Bosnia and Herzegovina

## ABSTRACT

*Serum thyreoglobulin (Tg) and whole body scintigraphy (I-<sup>131</sup> WBS) have been used to detect recurrent and metastatic thyroid cancers postoperatively. However, discordant results of Tg measurement and <sup>131</sup>I WBS have been reported. Negative <sup>131</sup>I WBS and a positive Tg test are usually found, but less common occurrence of positive <sup>131</sup>I WBS and a negative Tg test has also been demonstrated in a small but significant number of cases. Therefore, the aim of the study was to retrospectively analyse patients with positive <sup>131</sup>I WBS after total thyroidectomy and again 1 year after the radioactive iodine. There were 52 patients included in the study. Four weeks after surgery, during which thyroid hormone treatment was not introduced, each patient received an ablative dose of <sup>131</sup>I. The evaluation of the WBS was qualitative and considered positive if thyroid remnant, lymphatic node or metastasis were detected. WBS and serum Tg was measured 12 months after <sup>131</sup>I ablation with thyroid hormone suppression. We considered positive any Tg level above the sensitivity values and negative if lower than this level. Tg levels were related to the existence of a positive scan or a negative one. In our 52 WBS positive patients concordant positive Tg levels were observed in 42 patients while in 10 patients we found a negative Tg levels after the surgery. After 1-year follow-up, out of initially 42 concordant patients 8 patients showed remaining concordant positive Tg and WBS values. Discordant results were observed in 13 patients (4 patients were Tg- and WBS+ while 9 patients were Tg+ and WBS-). In the majority of patients (50%) remained with concordant results but changed from Tg+ and WBS+ to Tg- and WBS-. Diagnostic WBS is an additional valuable tool, besides Tg levels, in the follow up of patients after total thyroidectomy.*

**Key words:** total thyroidectomy, thyreoglobulin, whole-body scan, radioiodine-<sup>131</sup>

## Introduction

The predominant method for treatment of differentiated thyroid carcinoma (DTC) is total or near-total thyroidectomy followed by <sup>131</sup>I remnant ablation and thyroid hormone suppression of thyroid-stimulating hormone (TSH).

Local recurrences and distant metastases are not seen frequently, particularly during the first years of follow-up, but sometimes occur many years later, with the overall survival decline to 40% when distant metastases are present<sup>1</sup>. Therefore, long-term monitoring of DTC recurrence and metastases is essential throughout the pa-

tient's life. Generally, 2 »markers« of thyroglobulin (Tg) and <sup>131</sup>I whole-body scanning (WBS), when used at the same time, offer the best possibilities in the follow-up of patients with DTC<sup>2</sup>.

The concentration of circulating Tg can increase substantially due to follicular destruction through inflammation or haemorrhage, as well as through rapid disordered growth of thyroid tissue, as may be observed in Graves' disease or follicular cell-derived neoplasms. Serum Tg concentrations were found to be increased in a range of thyroid disorders, most prominently in advan-

ced thyroid carcinoma<sup>3,4</sup>. However, substantial overlap was found between levels observed in benign thyroid disorders and those observed in tumor patients. Moreover, many patients with relatively small thyroid carcinomas had serum Tg concentrations that fell within the range of values found in healthy individuals. Tg was found to be useful for detecting residual or recurrent disease in patients with very small, or absent, thyroid remnants. Two key changes in medical practice enabled this observation to be translated into the routine serum Tg monitoring of virtually all thyroid cancer patients that has become the *de facto* standard of care to date.

Serum Tg levels during thyroid hormone withdrawal (Tg-off) is usually correlated with the results of diagnostic WBS (WBS). Undetectable Tg levels with negative WBS (WBS<sup>-</sup>) suggest complete remission, whereas detectable or elevated Tg concentrations are associated with the presence of <sup>131</sup>I uptake in local or distant metastases<sup>5</sup>. However, discordant results of Tg measurement and <sup>131</sup>I WBS have been reported. Negative <sup>131</sup>I DWBS and a positive Tg test (WBS<sup>-</sup> Tg<sup>+</sup>) were found in most of these cases<sup>6-8</sup>. The uncommon occurrence of positive <sup>131</sup>I WBS and a negative Tg test (WBS<sup>+</sup> Tg<sup>-</sup>) has also been demonstrated in a small but significant number of cases<sup>9,10</sup>.

Only thyroid follicular cells produce Tg. Therefore, if all normal and malignant thyroid tissue is successfully ablated, any Tg that is detected subsequently in a patient with DTC can only be the product of recurrent malignancy. This concept led to the initial studies that indicated the usefulness of isolated and serial serum Tg determinations as a marker for DTC and as an indicator of the effectiveness of surgery and <sup>131</sup>I therapy<sup>11</sup>. In patients with DTC, the Tg level depends on the capacity of the tumor to respond to endogenous or exogenous TSH stimulation, the ability of the tumor to synthesize and release immunologically active Tg, the amount of thyroid tissue remnant, and the tumor size<sup>12</sup>.

## Materials

### Patients

We retrospectively evaluated 65 patients with differentiated thyroid carcinoma who had undergone total thyroidectomy for differentiated thyroid carcinoma and had been subsequently referred to the Clinic of Nuclear Medicine for <sup>131</sup>I ablation during 2008-2010. We excluded patients with known metastasis at the moment of diagnosis, those with negative Tg and positive Tg antibodies, patients with TSH under 30 mU/mL and those with incomplete thyroidectomy or soft tissue infiltration. Therefore, 52 patients were included in the study corresponding to 42 women and 10 males. All the body scans were included for their valuation and simultaneous determination of Tg and Tg antibodies with TSH  $\geq$ 30mU/mL.

### Methods

All patients were given oral information of the study procedures to be carried out at the Clinic for Nuclear medicine at the Clinical Center University of Sarajevo. Informed consent was obtained from all the patients included in the study.

Four weeks after surgery, during which thyroid hormone treatment was not introduced, each patient received an ablative dose of <sup>131</sup>I. <sup>131</sup>I was administered to the patients fasting 8 h. The treatment dose was based on the following criteria: patients with tumor restricted to the thyroid gland and no lymph node involvement received 3.7 GBq (100 mCi); patients with lymph node involvement or extrathyroidal invasion received 4.44 GBq (120 mCi); patients with evidence of distant metastasis received 5.55 GBq (150 mCi). Just before <sup>131</sup>I ablation therapy, the level of thyroid stimulating hormone (ablation-TSH) was above 30  $\mu$ mL, and the serum Tg level (ablation-Tg) was measured. A postablation <sup>131</sup>I WBS was performed 3 to 5 days after the administration of <sup>131</sup>I.

Images were obtained after 48-72 h, and if necessary after 5 days. The evaluation of the WBS was qualitative, a scan was considered positive when increased tracer activity appeared and did not correspond to physiological elimination; therefore the scan that only demonstrated neck activity was also considered positive image.

Tg was analysed by means of radioimmunoassay with sensitivity in our laboratory at <0.1 ng/mL. The serum Tg was measured 12 months after <sup>131</sup>I ablation with thyroid hormone suppression. Ablation success was defined as an undetectable level of Tg 12 months after ablation therapy.

We considered positive any Tg level above the sensitivity values and negative if lower than this level. Patients with positive anti-Tg antibodies were excluded only if Tg negative. All patients with a positive scan were surgically treated if indicated, but if only neck remnants appeared, a new therapeutic <sup>131</sup>I dose was given in order to obtain total elimination of functioning thyroid tissue.

Tg levels were related to the existence of a positive scan (thyroid remnants-lymph nodes-metastasis) or a negative one. The concordant results were considered if both Tg and body scans were positive (Tg+ and WBS+) or both negative (Tg- and WBS-). Discordant results were any other combination.

## Results

In our 52 WBS+ patients concordant positive Tg levels were observed in 42 patients (WBS+ and Tg+). In 10 patients we found a negative Tg levels and discordant results with WBS (WBS+ and Tg-) after the ablation dose (Figure 1).

After 1 year follow-up, out of initially 42 concordant patients 8 patients showed remaining concordant positive Tg and WBS values (Tg+ and WBS+). Out of those 8 patients with concordant positive results 5 showed cervical remnants and in 3 patients distant metastasis were

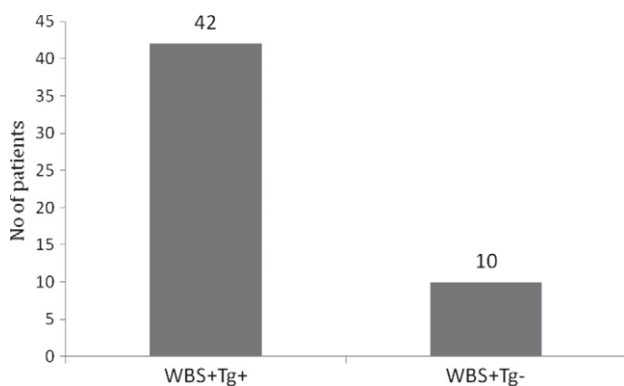


Fig. 1. Conocordant (WBS+Tg+) and discordant (WBS+Tg-) results in the patients after the first therapeutic dose.

observed. Serum Tg levels were higher in patients with distant metastasis (20-42 ng/mL) while in patients with cervical remnants serum Tg levels were slightly above the sensitivity level (3-5 ng/mL) (Table 1). Discordant results were observed in 13 patients (4 patients were Tg-and WBS+ while 9 patients were Tg+ and WBS-).

**TABLE 1**  
PATIENTS WITH CONCORDANT AND DISCORDANT RESULTS 1 YEAR AFTER THE INITIAL TREATMANT

	WBS+Tg+	WBS+Tg-
No of patients	8	9
Cervical remnants	5	6
Lymphatic nodes		2
Distant metastasis	3	1

WBS+Tg+ – positive <sup>131</sup>I whole body scintigraphy and positive serum thyreoglobulin test

WBS+Tg- – positive <sup>131</sup>I whole body scintigraphy and negative serum thyreoglobulin test

Majority of the patients, 50% (21 patients) remained with concordant results but changed from Tg+ and WBS+ to Tg- and WBS- (Figure 2). All of the 10 initially

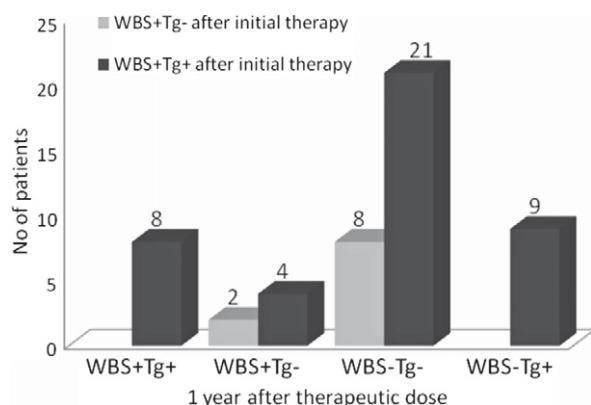


Fig. 2. Results of WBS and Tg serum levels after 1 year post total thyroidectomy according to WBS and Tg concordance after initial <sup>131</sup>I therapy. WBS- whole body scintigraphy; Tg-thyreoglobulin.

Tg- and WBS + patients remained Tg- after 1 year, out of whom 8 converted to WBS- and 2 remained WBS+ (Figure 2).

## Discussion

WBS+ Tg- has been documented in a small but significant number of cases<sup>9, 10</sup>. Muller-Gartner et al.<sup>13</sup> reported that false-negative serum Tg test results occurred in patients with small papillary carcinoma with cervical or mediastinal lymph node metastases and suggested that the small tumor mass might account for undetectable Tg production. Mertens et al.<sup>10</sup> presented the case of a 54-y-old woman with metastatic follicular thyroid cancer and false-negative Tg. Many years after the patient had a subtotal thyroidectomy, metastatic bone disease was found. When the bone metastases were detected, serum Tg values remained undetectable, whereas <sup>131</sup>I WBS demonstrated abundant uptake in the metastases during the follow-up period. This case indicates that the combination of <sup>131</sup>I scintigraphy and serum Tg values is superior to the measurement of serum Tg alone in detecting DTC. The reliability of very low serum Tg-off levels (<3 ng/mL) was evaluated in 224 patients without Tg Ab—who had undergone total thyroidectomy (125 patients) or thyroidectomy followed by 1 or more courses of <sup>131</sup>I therapy (99 patients)—by performing WBS after a therapeutic dose of <sup>131</sup>I with Tg measurement at the same time. WBS+ Tg- was found in 79 patients (35%). In 60 patients, the <sup>131</sup>I uptake was limited to the thyroid bed, but in 19 patients (8.5%), metastases were demonstrated<sup>9</sup>. This study indicates that even serum Tg-off is not a completely reliable method for follow-up of DTC patients.

In our study, 52 WBS positive patients 42 (81%) also had positive Tg levels, while false negative Tg results were observed in 10 patients after the first therapeutic dose. The possible causes of false-negative Tg might include low functional sensitivity of Tg methods to detect small amounts of thyroid tissue when TSH is suppressed; presence of Tg antibodies, immunologically inactive Tg evades detection in a given Tg RIA. Tg produced by the tumor contains unique epitopes and altered biochemical features may obscure recognition by the antibodies used in the assay<sup>12</sup>, which result in falsely low Tg values. The dedifferentiated DTC cells can still concentrate iodine but are unable to synthesize or release Tg. It was observed that the least differentiated metastases are prone to be associated with lower Tg levels. This could be explained by a decrease in the synthesis or release of a normal Tg and by the synthesis of an immunologically inert Tg unrecognized by antibodies used in routine assays or there is a more rapid clearance of Tg from the plasma<sup>9</sup>.

Iodine uptake is a prerequisite for <sup>131</sup>I WBS diagnosis. Loss of iodine uptake provides a reason for the DWBS—that is observed frequently in metastasized DTC. As many as 15% of DTC patients with an elevated Tg level but a DWBS- are found on further evaluation to have persistent, recurrent, or metastatic disease<sup>14</sup>. The possi-

ble causes might include: defective Iodine-Trapping Mechanism, Loss of Differentiation, Dispersed Microscopic Metastases, Improper Patient Preparation Before  $^{131}\text{I}$  WBS. Iodine uptake is an indicator of differentiated behavior, as is the expression of sodium/iodine symporter (NIS), Serum thyroid peroxidase (TPO), Tg, and TSH receptor. Any defect in them will contribute to false-negative  $^{131}\text{I}$  WBS. Limitations in the detection of recurrent or metastatic lesions occur when progressive dedifferentiation of DTC cells leads to a loss of iodine-concentrating ability, but retaining the Tg synthesizing capability, thereby becoming more difficult to monitor and less responsive to traditional therapeutic modalities<sup>15</sup>.

False-positive WBS occurs for a wide range of reasons, including external contamination through saliva and sweat, internal contamination through nasopharyngeal secretion, as well as physiologic uptake in nonthyroidal tissue such as choroid plexus, salivary glands, gastric mucosa, and urinary tract. Shapiro et al.<sup>16</sup> provide a logical classification and pathophysiologic interpretation of the disparate literature of the host of artifacts, anatomic and physiologic variants, and nonthyroidal diseases that are responsible for false-positive  $^{131}\text{I}$  WBS, such as ectopic foci of normal thyroid tissue; nonthyroidal physiologic sites; contamination by physiologic secretions; ectopic gastric mucosa; other gastrointestinal abnormalities; urinary tract abnormalities; mammary abnormalities; serous cavities and cysts; inflammation and infection; nonthyroidal neoplasms; and currently unexplained causes. These cases of nonspecific  $^{131}\text{I}$  accumulation make more acute the urgency to be familiar with unusual but possible causes that may mimic uptake by DTC metastases<sup>15</sup>.

In our experience, the persistence of thyroid remnants 1 year after surgery and therapeutic  $^{131}\text{I}$  dose was high (total 19 patients remained WBS +, 36,5%). Out of these 11 patients had undetectable Tg levels.

A major problem encountered during careful follow-up evaluations is the finding of a positive serum Tg concentration in a patient without demonstrable carcinoma

on the diagnostic WBS. It might be that the tumour can trap  $^{131}\text{I}$  adequately but is too small to be visualised with current diagnostic scanning procedures<sup>17</sup>. Although, as a consequence, the tumour may be invisible on radioiodine scanning, it may still produce enough Tg for serum detection and sufficiently trap  $^{131}\text{I}$  for therapy. An aspect that has come under consideration in recent years is whether it is reasonable to use the presence of Tg in serum as an indicator for  $^{131}\text{I}$  therapy when the diagnostic WBS is negative. Schlumberger et al.<sup>17</sup> report that 80% of patients with a serum Tg-off level above 10 ng/ml will have detectable  $^{131}\text{I}$  uptake in the neck or at distant sites after the administration of a therapeutic activity of  $^{131}\text{I}$ ; in patients with a serum Tg-off level above 10 ng/mL and a negative post-therapeutic scan, metastases may emerge clinically some years later. The authors suggest a Tg-off cut-off point of 10 ng/mL for  $^{131}\text{I}$  therapy without prior diagnostic scan. If post-therapy uptake is noted, they continue to treat the patient until the post-therapeutic WBS becomes negative. The authors state that generally three cycles of  $^{131}\text{I}$  therapy (3,700 MBq per therapy) are sufficient to reach this point. Early discovery of metastases may permit a reduction in the cumulative activity necessary for eradication of the tumour and hence a reduction in total body irradiation. From a dosimetric point of view, the relevant parameter is the concentration of  $^{131}\text{I}$  in the tumour, i.e. the ratio between  $^{131}\text{I}$  uptake and mass of functioning tissue: a low uptake in a small metastasis may result in a higher  $^{131}\text{I}$  concentration than a higher uptake in a much larger metastasis<sup>17</sup>. This means that it is reasonable to conclude that a patient with a detectable Tg-off in combination with a negative  $^{123}\text{I}$  WBS should be treated with a therapeutic activity of  $^{131}\text{I}$ .

## Conclusion

Based on our results, Tg as a solitary marker of thyroid remnant might give false negative results and therefore we suggest the diagnostic WBS as an additional valuable argumentarium in the follow up of patients after total thyroidectomy.

## REFERENCES

- SCHLUMBERGER MJ, *N Engl J Med*, 338 (1998) 297. DOI: 10.1056/NEJM199801293380506 — 2. PACINI F, PINCHERA, A. *Biochimie*, 81(1999) 463. DOI: 10.1016/S0300-9084(99)80096-0 — 3. VAN HERLE AJ, ULLER RP, *J. Clin. Invest.*, 56 (1975) 272. DOI: 10.1172/JCI108181 — 4. GERFO PL, COLACCHIO T, COLACCHIO D, FEIND C, *J. Am. Med. Assoc.*, 241 (1979) 923. DOI: 10.1001/jama.1979.03290350043022 — 5. DEGROSSI OJ, ROZADOS IB, DAMILANO S, DEGROSSI EB, DE GANINO L, PINKAS M, GARCÍA DEL RÍO H, ARTAGAVEYTÍA D, *Medicina (B Aires)*, 51 (1991) 291. — 6. PACINI L, AGATE R, ELISEI M. *J Clin Endocrinol Metab*, 86 (2001) 4092. DOI: 10.1210/jc.86.9.4092 — 7. DE KEIZER B, KOPPESCHAAR HP, ZELISSEN PM, LIPS CJ, VAN RIJK PP, VAN DIJK A, DE KLERK JM, *Eur J Nucl Med*. 28 (2001) 198. — 8. KOH JM, KIM ES, RYU JS, HONG SJ, KIM WB, SHONG YK, *Clin Endocrinol (Oxf)*, 58 (2003) 421. DOI: 10.1046/j.1365-2265.2003.01733.x — 9. BRENDDEL AJ, LAMBERT B, GUYOT M, JEANDOT R, DUBOURG H, ROGER P, WYNCHAUK S, MANCIET G, LEFORT G, *Eur J Nucl*

- Med*, 16 (1990) 35. DOI: 10.1007/BF01566010 — 10. MERTENS IJ, DE KLERK JM, ZELISSEN PM, THIJSSSEN JH, SIE-GO DM, HAN SH, VAN RIJK PP, *Clin Nucl Med*, 24 (1999) 346. DOI: 10.1097/00003072-199905000-00011 — 11. CLARK PM, BECKETT G, *Ann Clin Biochem*, 39 (2002) 196. DOI: 10.1258/0004563021902125 — 12. TORRENS JI, BURCH HB, *Endocrinol Metab Clin North Am*, 30 (2001) 429. DOI: 10.1016/S0889-8529(05)70194-8 - 13. MULLER-GARTNER HW, SCHNEIDER C, *Cancer*, 61 (1988) 976. DOI: 10.1002/1097-0142(19880301)61:5<976::AID-CNCR2820610520>3.0.CO;2-U — 14. PACINI F, LIPPI F, FORMICA N, ELISEI R, ANELLI S, CECCARELLI C, PINCHERA A, *J Nucl Med*, 28 (1987) 1888. — 15. MA C, KUANG A, XIE J, MA T, *J Nucl Med*, 46 (2005) 1473. DOI: 10.1016/j.nucmedbio.2005.04.018 — 16. SHAPIRO B, RUFINI V, JARWAN A, GEATTI O, KEARFOTT KJ, FIG LM, KIRKWOOD ID, GROSS MD, *Semin Nucl Med*, 30 (2000) 115. DOI: 10.1053/nm.2000.5414 — 17. SCHLUMBERGER M, MANCUSI F, BAUDIN E, PACINI F, *Thyroid*, 7 (1997) 273. DOI: 10.1089/thy.1997.7.273.

*E. Kućukalić-Selimović*

*Clinical Center University of Sarajevo, Clinic for Nuclear Medicine, Bolnička 25, 71 000 Sarajevo  
e-mail: elma.kucukalic@yahoo.com*

## **ZNAČAJ SERUMSKOG TIREOGLOBULINA I SCINTIGRAFIJE CIJELOG TIJELA JODOM-131 U PRAĆENJU PACIJENATA SA KARCINOMOM ŠTITNJAČE NAKON TIREOIDEKTOMIJE**

### **S A Ž E T A K**

Serumski tireoglobulin (Tg) i scintigrafija cijelog tijela jodom-131 ( $^{131}\text{I}$  SCT) se koriste u praćenju recidiva i metastaza karcinoma štitnjače u postoperativnom periodu. Objavljeni su oprečni rezultati o koristnosti mjerenja Tg i  $^{131}\text{I}$  SCT kod pacijenata sa karcinomom štitnjače. Negativan  $^{131}\text{I}$  SCT nalaz i pozitivan serumski Tg se uočavaju u najvećem broju slučajeva, ali je pozitivan nalaz  $^{131}\text{I}$  SCT i negativan Tg test prisutan u manjem, ali značajnom, broju slučajeva. Stoga je cilj studije bio da se retrospektivno analiziraju slučajevi pacijenata sa pozitivnim  $^{131}\text{I}$  SCT nalazom nakon totalne tireoidektomije i ponovo 1 godinu nakon terapije radioaktivnim jodom. U studiju je bilo uključeno ukupno 52 pacijenta. Svaki pacijent je primio ablativnu dozu  $^{131}\text{I}$  tokom 4 sedmice postoperativno bez uvođenja tireoidne supstitucione terapije. Evaluacije SCT je bila kvalitativna i nalaz je smatran pozitivan ukoliko su uočeni: ostatno tkivo štitne žlijezde, limfni čvorovi ili metastaze (SCT+). SCT i serumski Tg je mjeren 12 mjeseci nakon ablacije sa  $^{131}\text{I}$ . Tg test je smatran pozitivan (Tg+) ukoliko je serumski Tg bio iznad donje granice senzitivnosti. Nivo Tg u serumu je upoređivan sa nalazom SCT. Od ukupno 52 SCT+ pacijenta, njih 42 su imali i pozitivan serumski Tg, dok je 10 pacijenata imalo negativan Tg test postoperativno. Nakon 1-godišnjeg perioda praćenja, od inicijalnih 42 Tg+ i SCT+ pacijenta, utvrđeno je da je 8 pacijenata i dalje imalo pozitivan i Tg i SCT test, dok su se kod 13 pacijenata uočili oprečni rezultati (4 pacijenta su bila Tg-i SCT+ dok je 9 pacijenata imalo Tg+ i SCT-). Kod većine pacijenata u studiji (50%) utvrđeni su konkordantni rezultati Tg i SCT testa, s tim da su inicijalno pacijenti sa pozitivnim Tg testom i SCT nalazom nakon 1 godine imali negativan i Tg test i SCT nalaz. Dijagnostički SCT je pored Tg testa, dodatna značajna pretraga u praćenju pacijenata nakon totalne tireoidektomije.