

# Hidradenoma of the External Auditory Canal: Clinical Presentation and Surgical Treatment

Petar Drviš, Mihael Ries, Krešo Zurak, Robert Trotić, Jakov Ajduk and Siniša Stevanović

University of Zagreb, »Sestre milosrdnice« University Hospital Center, Department of Otolaryngology-Head and Neck Surgery, Zagreb, Croatia

## ABSTRACT

*The aim of this article is to present clinical features, diagnostic procedures and surgical treatment of a rare ear tumor. We report a case of 78 year old female with hidradenoma of the external auditory canal. Patient had a sensation of pain and fullness with permanent otorrhea from the right ear for one year. Temporal bone computed tomography showed a tumor of the external ear, 6 centimeters in diameter, without bone, temporomandibular joint or intracranial invasion; the tumor was limited medially by the tympanic membrane. Biopsy was performed and pathohistology finding was: hidradenoma nodulare atypicum. Surgical intervention and wide tumor removal in general endotracheal anesthesia was performed. One year after the surgery there was no sign of tumor recurrence. Hidradenoma is rare ear tumor arising from the epithelial cells of sweat glands of the external auditory canal. Radiological evaluation and pathohistology confirmation of hidradenoma is necessary and wide excision of the tumor is the treatment of choice.*

**Key words:** hidradenoma, external auditory canal tumor

## Introduction

Hidradenoma is a rare tumour of ceruminous glands of the external auditory meatus, which as modified apocrine sweat glands normally produce secretion, a constituent of cerumen<sup>1</sup>. Ceruminous glands are localized deep in the skin mostly in the cartilaginous part of the external auditory canal<sup>2</sup>. Tumors arising from the epithelial cells of sweat glands of the external ear canal can present a diagnostic dilemma because of their varied clinical and histologic manifestations and variable nomenclature used to describe these tumors. These terms do not suggest a specific diagnosis, clinical behavior, treatment alternatives and long-term clinical outcome. It is important to separate benign from malignant sweat gland tumors. Hidradenomas are classified histologically as: adenoma, pleomorphic adenoma, adenoid cystic carcinoma and adenocarcinoma<sup>3</sup>. This classification aids treatment and prognosis. Very often chronic middle or external ear inflammation mimicks the tumor<sup>4</sup>. Some malignant hidradenomas develop from their benign counterparts. The most often symptom of hidradenomas of the external auditory meatus is the unilateral conductive hearing loss and other symptoms of this tumor like the pain or ear discharge can result from external otitis secondary to ear canal ob-

struction. These tumors are characterized by rare occurrence and controversial histogenesis. The initial diagnosis is clinical, followed by histopathological confirmation. Cerumen pigment, CK7 and p63 can help to distinguish hidradenoma from other neoplasms that occur in this region<sup>5</sup>. Patients mostly present clinically with a mass of the outer half of the external auditory canal and the most often symptoms are the unilateral conductive or mixed hearing loss, ear pain, ear discharge and external otitis secondary to the meatus obstruction. The aim of presenting this case is to describe clinical features, diagnostic procedures and surgical treatment of hidradenoma of the external auditory canal.

## Case Report

The case of 78 year old female with hidradenoma of external auditory canal is reported. The tumor of external auditory canal (Figure 1) was presented by ear pain and fullness in the right ear and chronic ear drainage for one year. The patient had bilateral hearing loss: mixed hearing loss of the right ear and sensorineural hearing loss

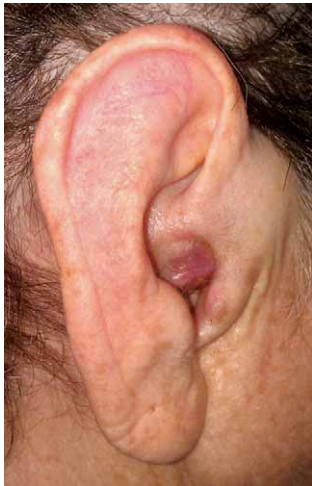

Fig. 1. Hidradenoma of external auditory canal.

of the left ear. The patient had previous history of two operations in a regional hospital: incision of the furuncle of external auditory canal and biopsy of the lesion of external auditory canal, pathohistology finding was without carcinoma. Temporal bone CT scan showed tumor mass of the external ear canal, 6 centimeters in diameter, without bone, temporomandibular joint or intracranial invasion (Figure 2); the tumor was limited medially by the

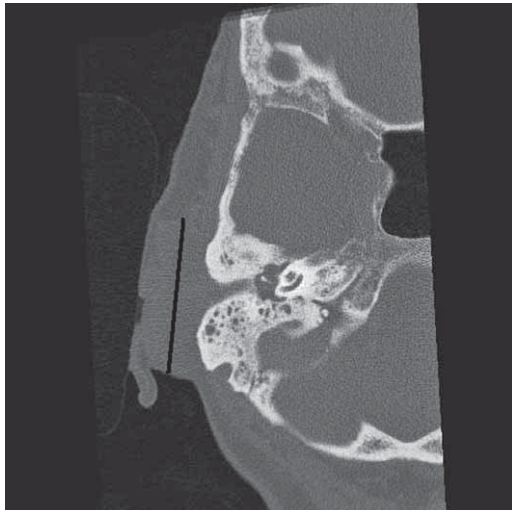


Fig. 2. CT scan: tumor mass of the external auditory canal.

tympanic membrane. In our institution biopsy was performed and pathohistology finding was: *hidradenoma nodulare atypicum*. Wide tumor removal with combined retroauricular-endaural approach in general anesthesia was performed, keeping the auricle and tympanic membrane intact (Figure 3). In the second stage procedure reconstruction of the external auditory canal with the regional skin flap was performed (Figure 4). One year after the surgery there was no sign of recurrence (Figure 5).

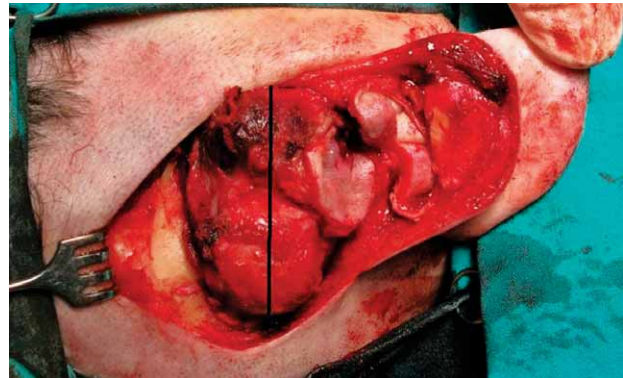


Fig. 3. Surgery – first stage: retroauricular-endaural approach.

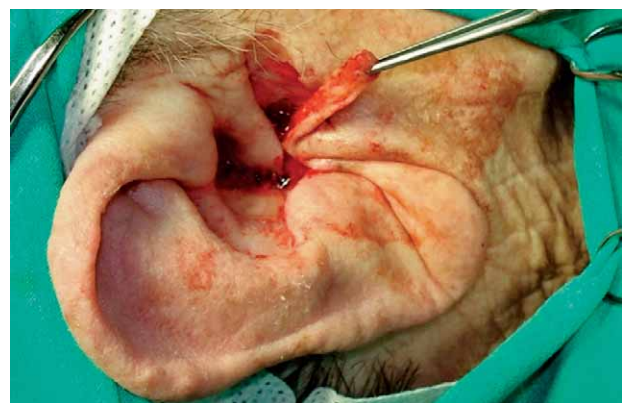

Fig. 4. Surgery – second stage: reconstruction of the external auditory canal.

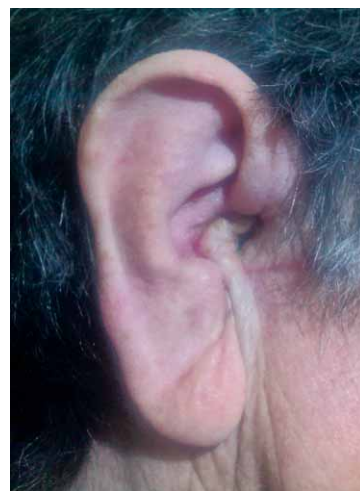

Fig. 5. One year follow-up.

## Discussion

Hidradenoma is a rare ear tumor arising from the epithelial cells of sweat glands of the external auditory canal. It can cause diagnostic dilemma because of their var-

ied clinical and histologic manifestations. Hidradenomas do not present with clinical characteristics that allows differentiation from other ear canal tumors on the basis of the clinical and macroscopic findings. Clinical diagnosis is difficult and any lesion which shows evidence of enlargement should be confirmed by histological evaluation. Although this rare benign tumor has the potential of local recurrence and malignant transformation, it is commonly reported in the oncology literature, with limited clinical information<sup>5</sup>. Every tumor arising from the external auditory canal should be examined histologically and immunohistochemically in order to choose the best treatment option. Malignant hidradenomas in contrast to the benign forms, tend to invade the surrounding tissue and have a high incidence of recurrence and distant metastasis<sup>6</sup>. Incomplete excision of the tumor leads to the recurrence<sup>7</sup>. To the best of our knowledge, two stage combined surgical technique for removal of these

lesions has not been described so far in the literature. The second stage reconstruction with the regional skin flap was performed to cover the exposed bone of the external auditory canal. This surgical technique was chosen with the objective of removing the entire lesion without rupturing the tympanic membrane and preservation of the auricle.

## Conclusion

Hidradenomas are the most common external auditory canal tumors. The possibility of sweat gland tumors should be considered in the differential diagnosis of ear tumors to ensure early detection and treatment. Radiological evaluation and pathohistology confirmation is necessary and wide excision of tumor is the treatment of choice.

## REFERENCES

- BRADBURY PG, DIENGDORF JV, CROCKARD HA, STERN GM, J Neurol Neurosurg Psychiatry, 47 (1984) 645. DOI: 10.1136/jnnp.47.6.645.
- NAMYSŁOWSKI G, SCIERSKI W, MISIOLEK M, CZECIOR E, LANGE D, Otolaryngol Pol, 57 (2003) 755.
- THOMPSON LDR, NELSON BL, BARNES L, Am J Surg Pathol, 28 (2004) 308. DOI: 10.1097/00000478-200403000-00003.
- ELSURER C, SENKAL HA, BAYDAR DE, SENNAROGLU L, Eur Arch Otorhinolaryngol, 264 (2007) 223. DOI: 10.1007/s00405-006-0166-z.
- MARKOU K, KARASMANIS I, VLACHTSIS K, PETRIDIS D, NIKOLAOU A, VIOTAL V, Am J Otolaryngol, 29 (2008) 142. DOI: 10.1016/j.amjoto.2007.04.005.
- SIRINOGLU H, CELEBIL-ER O, J Craniofac Surg, 22 (2011) 750. DOI: 10.1097/SCS.0b013e3182085501.
- LIAPAKIS IE, KORKOLIS DP, KOUTSOUMBI A, FIDA A, KOKKALIS G, VASSILOPOULOS PP, Anticancer Res, 26 (2006) 2217.

P. Drviš

University of Zagreb, »Sestre milosrdnice« University Hospital Center, Department of Otolaryngology-Head and Neck Surgery, Vinogradska 29, Zagreb, Croatia  
e-mail: pdrvis@gmail.com

## HIDRADENOM ZVUKOVODA: KLINIČKA PREZENTACIJA I KIRURŠKO LIJEČENJE

### SAŽETAK

Cilj je prikazati kliničke značajke, dijagnostičku obradu i kirurško liječenje rijetkog tumora uha. Prikazan je slučaj 78-godišnje pacijentice s hidradenomom zvukovoda. Pacijentica je imala osjećaj punoće, bol i sekreciju iz desnog uha godinu dana unatrag. Kompjutorizirana tomografija temporalnih kostiju je pokazala tumorsku masu zvukovoda, 6 centimetara u promjeru, bez invazije kosti ili temporomandibularnog zgloba te bez intrakranijalnog širenja; tumor je bio medijalno ograničen bubnjićem. Učinjena je biopsija tvorbe, patohistološki nalaz je bio: *hidradenoma nodulare atypicum*. Tumor je kirurški odstranjen kombiniranim retroaurikularno-endaurnim pristupom u općoj endotrahealnoj anesteziji. Godinu dana nakon operacije nije bilo znakova recidiva tumora. Hidradenom spada u rijetke tumore koji potječu od epitelnih stanica znojnih žlijezda. Potrebna je radiološka procjena i patohistološka potvrda hidradenoma, a kirurško odstranjenje tumora u cijelosti je terapija izbora.