

Transoral Excision of a Parapharyngeal Space Tumor: Case Report

Marijan Kovačić, Milan Rudić and Zoran Kranjčec

Zadar General Hospital, Department of Otorhinolaryngology and Head and Neck Surgery, Zadar, Croatia

ABSTRACT

Tumors of the parapharyngeal space are rare tumors comprising less than 1% of all head and neck neoplasms. They are mainly salivary gland or neurogenic tumors. Clinical presentation is very variable. Surgical resection by different approaches remains to be the best possible treatment option. We present a case of 45 years old female patient admitted at the ENT Department due to the unilateral hearing loss and swallowing difficulties. Clinical examination revealed the diagnosis of a pleomorphic adenoma of the parapharyngeal space. Tumor was surgical (transorally) excised. Two years following the surgery there is no recurrence of the initial symptoms and primary disease.

Key words: parapharynx, parotid gland, transoral surgical approach

Introduction

Parapharyngeal space tumors are rare tumors comprising less than 1% of all head and neck neoplasms. Majority of these tumors (70–80%) are benign while 20–30% of these tumors are malignant^{1,2}. They can arise from any structure contained within the parapharyngeal space. The parapharyngeal space is a space lateral to the upper pharynx shaped like an inverted pyramid, extending from the skull base superiorly to the greater cornu of the hyoid bone inferiorly. The parapharyngeal space consists of two compartments. The anteromedial or prestyloid compartment containing the retromandibular portion of the deep lobe of the parotid gland, adipose tissue, and lymph nodes associated with the parotid gland, and a posterolateral or poststyloid compartment containing the internal carotid artery, the internal jugular vein, IX–XII cranial nerves, the sympathetic chain, and lymph nodes^{1,2}. This difference between the prestyloid and poststyloid space is used in imaging studies and can help in achieving the correct diagnosis preoperatively. Most parapharyngeal space tumors are of salivary (prestyloid compartment) or neurogenic origin (poststyloid compartment), although metastatic lesions, lymphoreticular lesions, and a variety of uncommon, unusual lesions may develop in this location^{1,3}. Surgery is the main therapy option for tumors of the parapharyngeal space. The choice of surgical approach depends on the size of the tumor, its location, its relationship to the great vessels, and

the suspicion of malignancy^{2–5}. We present a case of a parapharyngeal space tumor presenting as an intraoral tumor mass and discuss its diagnostic and treatment options.

Case Report

We report a case of a 45 year old female patient admitted at the ENT Department due to a unilateral (left) hearing loss and swallowing difficulties several months prior to hospitalization.

The patient was in a good general health with no concomitant diseases. Clinical examination revealed an oropharyngeal tumor mass with the intact mucosa. Fine needle biopsy was performed and the diagnosis was the tumor mixtus. The MSCCT imaging showed a cystic tumor measuring 5x5cm in diameter firmly attached to the deep lobe of the parotid gland originating from the pterygopalatine fossa and spreading towards the oro and nasopharynx. Tumor cranially spread towards the skull base and laterally extended to the ramus of the mandible and C1–2 vertebrae (Figure 1). The angiography was performed and showed moderate compression of the internal carotid artery by the tumor but not its infiltration. Audiometric findings revealed the left side conductive hearing loss. Laboratory findings were within reference

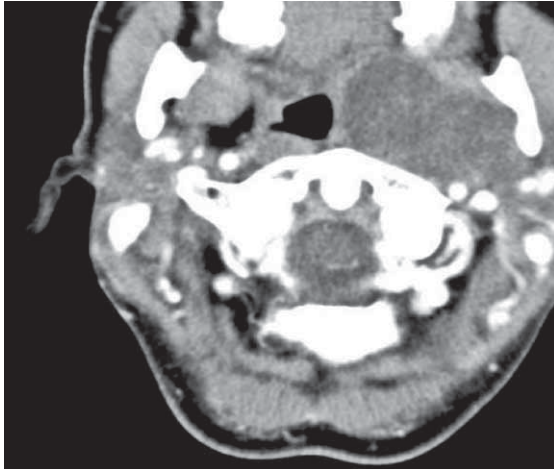


Fig. 1. MSCT scan showing tumor mass of the left parapharyngeal space attached to the deep lobe of the parotid gland.

range. Under the general anesthesia the tumor was removed by the transoral approach (Figure 2). Post-operative period was uneventful. Final diagnosis was pleomorphic adenoma, Tumor mixtus (Figure 3). Two years following the surgery the patient is free of any recurrent disease.

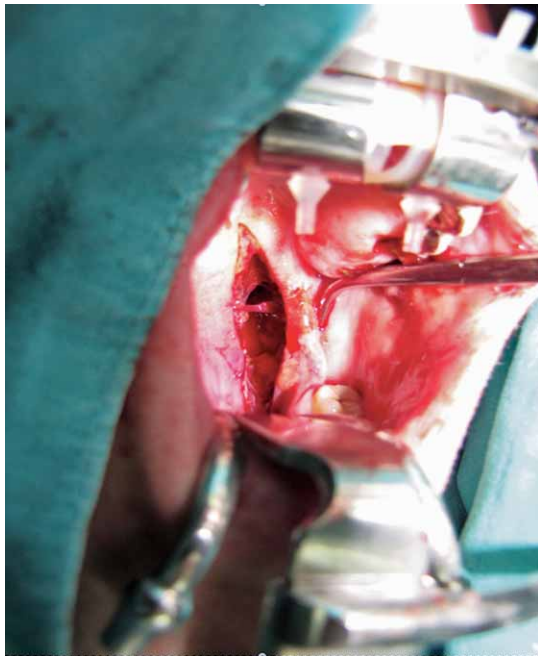

Fig. 2. Tumor excision by the transoral surgical approach.

Discussion

Majority of parapharyngeal space tumors are either salivary glands tumors originating from the deep lobe of the parotid gland or neurogenic tumors originating from the cranial nerves, the cervical sympathetic chain or the

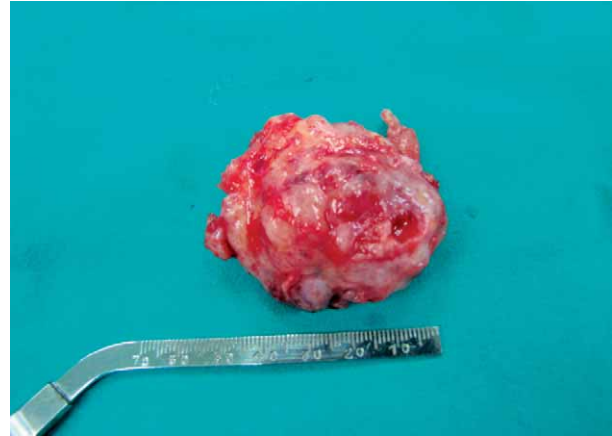

Fig. 3. Excised tumor measuring 5x5cm in diameter. Final diagnosis was pleomorphic adenoma.

glomus bodies (chemoreceptors). Metastatic tumors are mainly thyroid carcinoma, osteogenic sarcoma, and squamous cell carcinoma. Tumors may also extend from surrounding structures and spread to the parapharyngeal space (i.e. mandible, maxilla, nasopharynx, neck, oral cavity, oropharynx, and temporal bone)⁵. Patients with parapharyngeal space tumors should undergo a comprehensive history and complete head and neck examination (careful inspection and examination of the oropharynx and neck, and assessments of the functional integrity of the cranial nerves). Clinical presentation is very variable. Tumors can present as an oropharyngeal or neck mass or with other symptoms such as dysphagia, dyspnea, unilateral conductive hearing loss, hoarseness, true vocal cord palsy, Horner's syndrome and symptoms of catecholamine excess like hypertension and flushing^{1,5}. In our case the tumor presented as an oropharyngeal mass and patient complained of a unilateral hearing loss and swallowing difficulties several months prior to admittance. The CT scan can provide excellent imaging of the parapharyngeal space. The imaging characteristics and anatomic location of tumors originating in parapharyngeal space (prestyloid or poststyloid compartment tumors) can help in diagnosis. Fine needle aspiration of the lesion can be useful in some cases but this should only be performed after imaging to rule out a vascular lesion⁶. If paraganglioma are suspected the patient should undergo a 24-hour urine collection for vanillylmandelic acid and metanephrines. In the present case the MSCT imaging showed a cystic tumor originating from the pterygopalatine fossa firmly attached and not differentiated from the deep lobe of the parotid gland. Surgery is the best treatment option for parapharyngeal space tumors. Different surgical approaches exist (transoral, transcervical, transcervical-transparotid, transcervical-transmandibular and infratemporal-fossa approach). Nonoperative management of parapharyngeal space lesions is an option for elderly patients, those who have a comorbid disease, unresectable lesions and for those who have benign, slow-growing tumors. In the present case after thorough clinical evaluation we decided to remove

the tumor transorally. This approach was reported to be best suitable for small, isolated pleomorphic adenomas that originate from a small salivary gland in the soft palate or lateral pharyngeal wall tumors. The main disadvantage of this approach is limited exposure, increased risk of tumor spillage, and possibility of neurovascular injury. However, this approach gives the best possible postoperative recovery for the patient (lack of postoperative scar, no damage to the cranial nerves, preservation of the superficial lobe of the parotid gland and facial nerve, absence of Frey's syndrome, no need for mandibular osteotomy)^{7–10}. In order to perform this kind of approach for larger tumors like it was in our case, the sur-

geon must have a comprehensive understanding and surgical skills for treatment of tumors of parapharyngeal space. Postoperative period was uneventful and two years following the surgery there is no recurrence of the primary symptoms and disease. The recurrence rate of benign parapharyngeal space neoplasms following surgical extirpation ranges from 0–9%⁵. Radiation therapy could be also considered as a treatment for some parapharyngeal space tumors primarily for malignant neoplasm and in patients with paragangliomas who are poor surgical candidates.

REFERENCES

1. GOURIN CG, JOHNSON JT. Parapharyngeal space tumors. Accessed September 2011. Available from: URL: <http://emedicine.medscape.com/article/849385-overview#a0102>. — 2. SUAREZ-FENTE V, LLORENTE-PENDAS JL, GOMEZ-MARTINEZ J, GARCIA-GONZALEZ LA, LOPEZ-ALVAREZ F, SUAREZ-NIETO C. Acta Otorrinolaringol Esp, 60 (2009) 19, DOI: 10.1016/S0001-6519(09)70313-9. — 3. EISELE DE, NETTERVILLE JL, HOFFMAN HT, GANTZ BJ. Head Neck, 21 (1999) 154, DOI: 10.1002/(SICI)1097-0347(199903)21:2<154::AID-HED9>3.0.CO;2-W — 4. HUGHES KV III, OLSEN KD, MCCAFFREY TV. Head Neck, 17 (1995) 124, DOI: 10.1002/hed.2880170209. — 5. CARRAU RL, MYERS EN, JOHNSON JT. Laryngoscope, 100 (1990) 583. — 6. ARNANSON T, HARD RD, TAYLOR SM, TRITES JR, NASSER JG, BULLOCK MJ. Diagn Cytopathol, 40 (2012) 118, DOI: 10.1002/dc.21508. — 7. INFANTE-COSSIO P, GONZALES-CARDERO E, GONZALES-PEREZ LM, LEOPOLDO- RODADO M, GARCIAPERLA A, ESTEBAN F. Oral Maxillofac Surg, 15 (2011) 211, DOI: 10.1007/s10006-011-0289-2. — 8. PRESUTTI L, MOLTENI G, MALVE L, MARCHIONI D, GHIDINI A, TASSI S, CHIARINI L, ALICANDRI-CIUFELLI M. Eur Arch Otorhinolaryngol, 269 (2012) 265, DOI: 10.1007/s00405-011-1594-y. — 9. BRADELEY PJ, BRADELY PT, OLSEN KD. Curr Opin Otolaryngol Head Neck Surg, 19 (2011) 92, DOI: 10.1097/MOO.0b013e328342b9b4. — 10. DIMITRIJEVIC JM, JESIC SD, MIKIC AA, ARSOVIC NA, TOMANOVIC NR. Int J Oral Maxillofac Surg, 39 (2010) 983, DOI: 10.1016/j.ijom.2010.06.005.

M. Rudić

*Zadar General Hospital, Department of Otorhinolaryngology, B. Peričića 5, 23 000 Zadar, Croatia
e-mail: milan.rudic@yahoo.com*

TRANSORALNA EKSCIZIJA TUMORA PARAFARINGSA: PRIKAZ SLUČAJA

SAŽETAK

Tumori parafaringealnoga prostora predstavljaju svega 1% od ukupnih tumora glave i vrata. Najčešće su porijekla žlijezda slinovnica ili neurogenoga porijekla. Klinička prezentacija je vrlo varijabilna. Kirurška resekcija predstavlja najvažniji oblik liječenja. U radu prikazujemo slučaj bolesnice koja se javlja na Odjel za bolesti uha, grla i nosa zbog višemjesečne jednostrane zagušenosti i teškoća gutanja. Kliničkom obradom (MSCT radiološka obrada, citološka punkcija) ustanovljen je pleomorfni adenom parafaringealnoga prostora. Transoralnim pristupom resecirani je tumor. Dvije godine postoperativno nema znakova recidiva osnovne bolesti.