

# Diffuse Sclerosing Variant of Thyroid Carcinoma Presenting as Hashimoto Thyroiditis: A Case Report

Anamarija Vukasović<sup>1</sup>, Sanja Kusačić Kuna<sup>2</sup>, Karmen Trutin Ostović<sup>3</sup>, Drago Prgomet<sup>4</sup> and Tomislav Banek<sup>1</sup>

<sup>1</sup> Department of Nuclear Medicine, Dubrava University Hospital, Zagreb, Croatia

<sup>2</sup> Department of Nuclear Medicine and Radiation Protection, Clinical Hospital Centre Zagreb, Zagreb, Croatia

<sup>3</sup> Department of Clinical Cytology and Cytometry, Dubrava University Hospital, Zagreb, Croatia

<sup>4</sup> Department of Otorhinolaryngology, Head and Neck Surgery, Clinical Hospital Centre Zagreb, Zagreb, Croatia

## ABSTRACT

*The aim of report is to present a case of a rare diffuse sclerosing variant of a papillary thyroid carcinoma. A 15-year old girl referred for ultrasound examination because of painless thyroid swelling lasting 10 days before. An ultrasound of the neck showed diffusely changed thyroid parenchyma, without nodes, looking as lymphocytic thyroiditis Hashimoto at first, but with »snow-storm« appearance, predominantly in the right lobe. Positive thyroid peroxidase antibodies (TPO-AT) also suggested Hashimoto thyroiditis. Repeated US-FNAB (fine needle-aspiration biopsy) of the right lobe revealed diffuse sclerosing variant of papillary thyroid carcinoma and patient underwent total thyroidectomy. Pathohistologic finding confirmed diffuse sclerosing variant of a papillary thyroid carcinoma in the both thyroid lobes and several metastatic lymph nodes. Two months later patient received radioablative therapy with 3700 MBq (100 mCi) of I-131 followed by levothyroxine replacement. At the moment, patient is without evidence of local or distant metastases and next regular control is scheduled in 6 months. In conclusion, a diffuse sclerosing variant is rare form of papillary thyroid carcinoma that echographically looks similar to Hashimoto thyroiditis and sometimes could be easily overlooked.*

**Key words:** *diffuse sclerosing variant, papillary thyroid carcinoma, Hashimoto thyroiditis, neck ultrasound*

## Introduction

A diffuse sclerosing variant of thyroid papillary carcinoma is rare form of thyroid neoplasm initially described by Crile and Fisher in 1953.<sup>1</sup> with reported incidence in literature from 0.8 to 5.3 % of all papillary cancer<sup>2</sup>. It occurs in young individuals, ranging from 19 to 35 years and has a higher incidence of local metastasis compared to classic papillary thyroid cancer, with poorer prognosis<sup>3,4</sup>. This report include a case of a young girl who referred to Nuclear Medicine Department for thyroid ultrasound examination with symptoms of diffuse goiter.

## Case Report

A 15-year old girl initially presented with symptoms of painless swelling in thyroid area 10 days earlier. Clinical

examination revealed significant enlargement of the right lobe of thyroid, with no palpable cervical lymph nodes. The thyroid function tests (FT4, TSH) were in normal range, but with positive thyroid peroxidase antibodies (TPO-At 57 U/mL; reference range <5.6 U/mL). Ultrasound revealed enlarged thyroid, especially right lobe with hypoechogenic, inhomogeneous echostructure, without nodes, but with a „snow-storm« appearance suggesting multiple microcalcifications in the parenchyma (Figure 1). Vascularity of the right lobe was increased on a color Doppler image. At first glance the thyroid parenchyma seemed changed as Hashimoto thyroiditis, but right lobe was enlarged and a little bit different comparing to the left lobe. <sup>99m</sup>Tc pertechnetate thyroid scan showed decreased uptake of the tracer in the right thyroid lobe (Figure 2). So, instead of completing the exami-

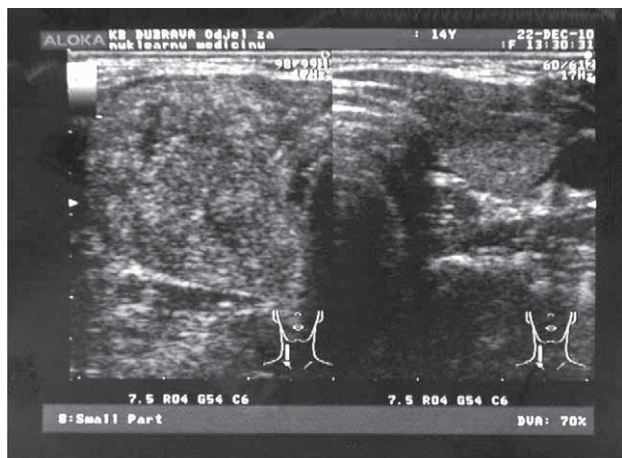


Fig. 1. Ultrasound of the thyroid demonstrated inhomogeneous, hypoechoic structure with numerous punctate microcalcifications.

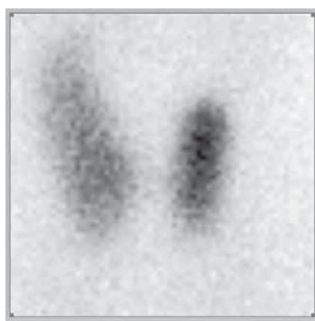

Fig. 2. <sup>99m</sup>Tc pertechnetate thyroid scan showed decreased uptake of the tracer in the right thyroid lobe

nation with the diagnosis of chronic lymphocytic thyroiditis Hashimoto, we decided to perform fine needle aspiration biopsy of the both lobes. Cytological finding suggest diffuse sclerosing variant of papillary thyroid carcinoma in the right lobe and normal finding of the left thyroid lobe with slightly higher number of thyrocytes (Figure 3). The patient underwent total thyroidectomy with se-

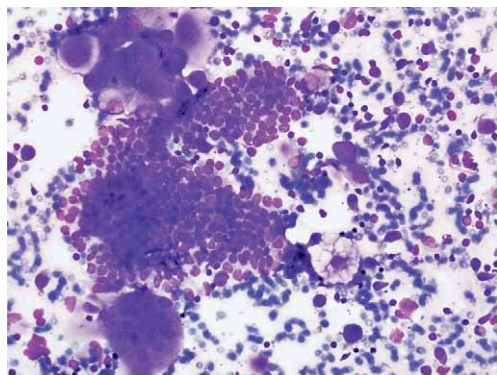


Fig. 3. FNAC of diffuse sclerosing variant of papillary carcinoma of thyroid: highly cellular smear consisted of papillary structures of benign thyrocytes mixed with squamous-like malignant cells against background of dense lymphocytic infiltrate, multinucleate giant cell and macrophages (May-Grünwald Giemsa stain, 400x)

lective neck dissection of the lymph nodes. Hystopathological finding confirmed a rare sclerosing variant of papillary thyroid carcinoma of the right thyroid lobe, with multiple islands of tumor tissue in the left lobe, infiltration of thyroid capsule, with abundant psammoma bodies inside the tumor. It also showed several lymph nodes contained metastatic carcinoma. Two months later patient recieved radioablative therapy with 3700 MBq (100 mCi) of I-131 followed by levothyroxine replacement. Whole-body postablation scan performed with SPECT/low dose CT showed intensive uptake of the radioiodine in the thyroid bed and focal uptake in the right supraclavicular region (Figure 4) which was suspected as metastatic lymph node. An ultrasound of the neck detected enlarged lymph node in the right supraclavicular region,

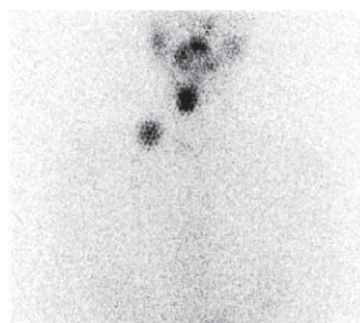


Fig. 4. Postablative I-131 scan of the head, neck and thorax showing focal intensive uptake in thyroid bed and right supraclavicular region

but ultrasound followed by FNAB revealed only reactive hyperplastic lymph node in that region. At the moment patient is without evidence of local (verified with neck ultrasound) or distant metastases (verified by chest X-ray, and with postablation scan). The outcome of ablation and medical treatment will be assessed in next regular control sheduled in 6 months by whole-body scan with 5 mCi of I-131 performed in hypothyroid state, neck ultrasound and determination of TSH, thyroglobulin (Tg) and thyroglobulin antibodies (TgAt).

## Discussion

A diffuse sclerosing variant of thyroid papillary carcinoma is rare form of thyroid malignancy usually presented with a diffuse goitre in patients who are mostly euthyroid. It occurs most frequently in young females and most of patients have lymph node involvement at the time of disease presentation. The disease could be mistaken clinically for benign disease particularly Hashimoto thyroiditis, because of similar echostucture, that could be potential pitfalls which may delay the diagnosis<sup>3-8</sup>. Sonographic features include heterogenous echogenicity, hypoechoic areas and numerous internal microcalcification which correlate to extensive fibrosis, lymphocytic infiltration and to psammoma bodies on histopathology diagnosis<sup>3,4,5</sup>. Precisely, the presence of microcalcifications detected as abundant psammoma bodies on ultra-

sonography may provide pre-operative evidence of those form of thyroid malignancy and should not be overlooked<sup>5</sup>. In this case, the clinical presentation, biochemical and initial ultrasound findings were all indicative of benign pathology. As metastases are frequently present it is therefore important to consider this rare malignancy when investigating a goitre in a young patient. The ultrasonographically presence of numerous internal microcalcifications should always stimulate to perform fine needle aspiration biopsy in spite of absence of nodal changes in thyroid. A diagnosis of diffuse sclerosing-variant of papillary thyroid carcinoma on FNAB should be considered when the typical cytological features of classical papillary carcinoma (papillary clusters, follicular cells with dense cytoplasm, well-defined margins, intranuclear cytoplasmic inclusions, multinucleate giant cells and psammoma bodies) are combined with sheets of squamous-like cells, numerous lymphocytes and absence

of colloid<sup>9</sup>. Ultrasound guided FNAB indicated malignancy leading to surgery demonstrating its importance in the diagnosis of those form of malignoma.

## Conclusion

Because of similar echostructure, diffuse sclerosing variant of papillary carcinoma could be mistaken for benign disease like Hashimoto thyroiditis. Our patient introduced with symptoms of both disease, but clinical appearance (asymmetric enlargement with echographically snow-storm picture) suggested possible thyroid malignoma. Ultrasound itself cannot exactly distinguish benign from malignant lesions, but some sonographic features like numerous punctate microcalcifications in spite of absence of nodal changes can suggest malignancy and help in the selection of changes to aspirate with FNAB that is crucial for final diagnosis.

## REFERENCES

1. CRILE G, FISHER ER, Cancer, 6 (1953) 57. DOI: 10.1002/1097-0142(195301)6:1<57::AID-CNCR2820060104>3.0.CO;2-D — 2. CHOW S-M, CHAN JKC, LAW SCK, TANG DLC, HO CM, CHEUNG WY, WONG ISM AND LAU WH. EJSO, 29 (2003) 446. — 3. KOBAYASHI K, FUKATA S, AMINO N, MIYAUCHI A, J Med Ultrasonics, 33 (2006) 159. — 4. KWAK JY, KIM EK, HONG SW, OH KK, KIM MJ, PARK CS AND CHEONG WY, Clin Radiol, 62 (2007) 382. — 5. FALVO L, BERNI A, CATTANIA A, D'ANDREA V, PALERMO S, GIUSTINIANI C AND DE ANTONI E, Surgery Today, 35 (2005) 304. — 6. KIM HS, HAN BK, SHIN JH, KO EY, SUNG CO, OH Y.L., SONGS.Y., Korean J Radiol, 11 (2010) 579. DOI: 10.3348/kjr.2010.11.5.579 — 7. LEE JY, SHIN JH, HAN BK, KO EY, KANG SS, KIM JY, OH YL AND CHUNG JH, Thyroid, 17 (2007) 567. — 8. MCELVANNA K, MCCUSKER G AND STIRLING I, UMJ 76(2) (2007) 113. — 9. CARUSO G, TABARRI B, LUCCHI I AND TISON V, Acta Cytol, 34 (1990) 352 DOI: 10.1186/1742-6413-2-12

A. Vukasović

University of Zagreb, Dubrava University Hospital, Centre of Nuclear Medicine, Avenija Gojka Šuška 6, 10 000 Zagreb, Croatia

e-mail: anamarijavukasovic@gmail.com

## DIFUZNO SKLEROZIRAJUĆI OBLIK PAPILARNOG KARCINOMA ŠTITNJAJE NALIK HASHIMOTO TIREOIDITISU: PRIKAZ SLUČAJA

### SAŽETAK

Opisan je slučaj petnaestogodišnje djevojke upućene na ultrazvučni pregled zbog bezbolnog zadebljanja štitnjače nastalog 10-ak dana prije dolaska na obradu. Bolesnica je bila eutiroidna uz povišena antitijela na peroksidazu (TPO-At) što je postavilo sumnju na postojanje autoimunog limfocitnog tireoiditisa. Ultrazvučnim pregledom verificirane su difuzne promjene ehostukture u parenhimu oba režnja štitnjače nalik kroničnom limfocitnom Hashimoto tireoiditisu. Međutim, obzirom na prisutnost punktififormnih kalcifikata unutar desnog režnja štitnjače, ipak je, unatoč nepostojanju nodoznih promjena u štitnjači učinjena citološka punkcija pod kontrolom ultrazvuka, te je potvrđena sumnja na difuzno sklerozirajući oblik papilarnog karcinoma u desnom režnju štitnjače. Učinjena je totalna tireoidektomija sa selektivnom disekcijom limfnih čvorova na vratu, a patohistološki nalaz je potvrdio dijagnozu difuzno sklerozirajućeg karcinoma u desnom režnju štitnjače s fokalnim žarištima tumora i u lijevom režnju, infiltraciju kapsule štitnjače, kao i više pozitivnih limfnih čvorova obostrano na vratu. Dva mjeseca kasnije bolesnici je aplicirana radiojodna ablacija sa 3700 MBq (100 mCi) I-131, a potom je stavljena na supresijsku terapiju L-tiroksinom. U ovom trenutku bolesnica je bez evidentnih znakova lokalnih ili distalnih metastaza i očekuje redovitu kontrolnu obradu predviđenu za oko 6 mjeseci. Kod mladih bolesnika sa bezbolnim povećanjem štitnjače i promjenama ehostukture u smislu kroničnog tireoiditisa Hashimoto, ali sa difuznim punktififormnim kalcifikatima unutar režnjeva potrebno je svakako imati u vidu i ovu rijetku vrstu papilarnog karcinoma. Stoga je u takvim slučajevima unatoč nepostojanju nodoznih promjena neophodno učiniti ciljanu citološku punkciju koja nam pomaže u postavljanju točne dijagnoze.