



Noninvasive imaging of craniocervical artery dissection

ARIJANA LOVRENČIĆ-HUZJAN
MARIJANA BOSNAR-PURETIĆ

University Department of Neurology
University Hospital Center »Sisters of Mercy«,
Referral Center for Neurovascular Disorders
of the Ministry of Health and Social Welfare
of the Republic of Croatia, Referral Center
for Headache of the Ministry of Health
and Social Welfare of the Republic of Croatia,
Zagreb, Croatia
E-mail: arijana.lovrencic-huzjan@zg.htnet.hr

Abbreviations

CCAD – craniocervical arterial dissection
MR – magnetic resonance
MRA – magnetic resonance imaging
CDFI – color Doppler flow imaging
TCD – transcranial Doppler
TIA – transient ischemic attacks
ICA – internal carotid artery
CT – computerized tomography
CTA – computerized tomography
angiography
BFV – blood flow velocity
TCCD – transcranial color-Doppler
MES – microembolic signals

Abstract

Craniocervical arterial dissections (CCAD) are being increasingly identified due to growing awareness of diverse clinical picture along with advances in imaging technologies. Although rare, CCAD are frequent cause of stroke in young adults. Neurosonological tests serve as an excellent noninvasive screening and monitoring tool, but brain MR and MRA are necessary for confirmation of the diagnosis. Ultrasound examination may show direct or indirect signs. Direct signs are: echolucent intramural hematoma, string sign, double lumen, or stenosis and/or occlusion of an arterial segment usually not affected by atherosclerosis. Indirect signs are: increased or decreased pulsatility index upstream or downstream of the suspected lesion, more than 50% difference in blood flow velocity compared to the unaffected side, or detection of intracranial collateral flow.

Since CCAD have been increasingly identified, a whole spectrum of clinical pictures are been recognizes. Neurosonology showed high sensitivity in CCAD detection.

INTRODUCTION

Craniocervical artery dissection (CCAD) is a major cause of transitory or permanent ischemic symptoms in young adults and can lead to various clinical symptoms (1, 2). Most dominant is pain in head and neck, usually developing after minor trauma, followed by ischemic symptoms within few hours to days. Some patients present only with headache, or a combination of headache and local signs (1, 2). Resolution is frequent and recurrence rate is relatively low. Genetic factors might have a role in the pathophysiology of CCAD, but despite ample work-up in most patients, the cause is not identified (1).

Traditional method for visualization of CCAD is catheter angiography that may show: smooth or slightly irregular luminal narrowing, pseudoaneurysm, intimal flap or double lumen (specific, but only in <10%) or distal branch occlusion (1, 3). MR images the eccentric or circumferential periarterial rim of intramural hematoma typically shows hyper intense signal on T1 and T2 weighted images (3). MR angiography has limited value, imaging the same pathomorphologic findings as angiography (3). Doppler and duplex sonography was underrated. Although color Doppler flow imaging (CDFI) showed good results in visualization of the dissection (4–11), the main limitation is visualization of the intracranial dissection, which appears to be common site of localization. While CDFI provide visualization of the direct

and some indirect findings of CCAD, TCD enables assessment of the intracranial hemodynamic and monitoring of the embolic potential that correlated with clinical picture (12, 13). The biggest advantage of neurosonological evaluation is its potential to enable noninvasive daily monitoring of the course of the dissection.

Incidence of the disorder is underestimated due to diverse clinical picture and sometimes pain as an only symptom. Resolution is common and recurrence rate is low, mostly within first month. Functional outcome is relatively good and mortality rate is low.

PATHOPHYSIOLOGY AND CLINICAL PICTURE

The incidence of the CCAD was reported to be in North American population-based study about 2.6 (95% CI 1.9–3.3) per 100 000 inhabitants per year (14), 2.5–3 per 100 000 for carotid artery, and 1–1.5 per 100 000 for vertebral artery dissection. Multi-vessel involvement is common. This number is probably underestimated, since clinical picture with mild symptoms including only headache and local signs remain undiagnosed (1).

In order to understand the different clinical pictures and imaging findings it is essential to understand the pathophysiology of the dissection. Arterial dissections begin with a tear in the intima or media resulting in bleeding within the arterial wall (2). Intramural blood dissects longitudinally and spreads along the vessel proximally and distally. Dissections can tear through the intima, allowing partially coagulated intramural blood to enter the lumen of the artery. Expansion of the arterial wall by intramural blood may cause compression of the lumen, and its narrowing. The blood flow stream is compromised and perturbation of the vascular endothelium causes activation of platelets and the coagulation cascade. These changes contribute to formation of an intraluminal thrombus. The intramural hematoma can create a false lumen that might reconnect with the true lumen and forms parallel flow. The true and false lumens are separated by an elongated intimal flap. If the dissection lies between the media and the adventitia, an aneurismal dilatation of the arterial wall may extrude. Intracranial, rupture through the adventitia causes subarachnoid bleeding.

Most researchers believe that patients with CCAD have a constitutional weakness of the arterial wall, and environmental factors such as minor trauma acts as a trigger (1, 2). The presence of an underlying vasculopathy is suggested by commonly present concomitant arterial anomalies such as fibromuscular dysplasia, monogenic connective tissue disease, mainly Ehlers-Danlos syndrome or Marfan's syndrome or inherited mechanism in familial cases of CCAD (15). Up to half of patients with CCAD have abnormalities in skin connective tissue that follow an autosomal dominant inheritance pattern (16). Traumatic dissections occur in patients with major penetrating or non-penetrating traumas, blunt traumas, or injuries associated with severe facial fractures, skull

base fractures and traumatic brain injury. Under the term spontaneous CCAD, dissections after minor trauma such as chiropractic manipulation (17), various sporting activities, whiplash injury, stretches and sudden neck movements during daily activities or severe coughing are assumed.

Clinical presentations result from bleeding in subintimal and subadventitial wall (2). If the dissections compromise the arterial lumen or cause thrombus formation in the lumen, clinical symptoms are the result of luminal compromise and the presence of luminal clot. Ischemic symptoms and infarction in the brain are caused by both reduced perfusion in the brain artery supplying territory or embolism. Neurological symptoms related to hypoperfusion are usually multiple brief transient ischemic attacks (TIAs) during a period of several hours to a few days. Hypoperfusion may decrease washout of emboli and contributes to the development of brain infarction. Occasionally, spinal cord infarction ensues because of hypoperfusion in the supply zones of vertebral artery branches that supply the cervical spinal cord (2).

Bleeding in the subadventitial wall results in compression of the adjacent structures to the outer arterial wall like lower cranial nerves (IX–XII) that exit near the skull base, or causes bleeding into adjacent tissues. Patients with subadventitial intracranial dissections often present with subarachnoid bleeding, because intracranial arteries have no external elastic envelope and have a thinner media and adventitia. Therefore the intracranial arteries are more prone to rupture (18).

The dominant symptom in all patients is sudden onset of pain in the region of dissection, in the head, neck, face or jaw (1, 2). For some patients it stays as the only symptom and such patients may remain undiagnosed. Headaches and other forms of pain sometimes precede ischemic symptoms by days or even weeks. When the vascular wall becomes expanded and dilated, as in mostly subadventitial dissection, Horner syndrome, pulsatile tinnitus and lower cranial nerve palsies coexist with the pain. Pulsatile tinnitus is explained by the course of the internal carotid artery (ICA) near the tympanic membrane. Sternocleidomastoid weakness, dysphagia with palatal weakness, hoarseness, and hemilingsual paralysis develop when nerves that emerge from the jugular and hypoglossal foramen are compromised.

Patients with intracranial dissections present with either brain infarction or subarachnoid hemorrhage. In general, the closer the dissection to the brain is, the higher probability of brain infarction is present (19). If the dissection is more extracranial, the higher is the probability of the local symptoms from space occupying lesions. Also, pain is stronger, and may even lead to syncope. This statement is true for arterial occlusive lesions of any cause—the closer the occlusion is to the brain, the more likely that infarction will develop (2).

IMAGING OF THE DISSECTION

Traditionally, imaging CCAD was performed by catheter angiography that may show smooth or slightly irregular luminal narrowing, string sign characterized by a long, narrow column of contrast material that begins beyond the ICA origin and might extend to the base of the skull (3). Flame-shaped tapering of the lumen is also common, or occlusion of the ICA, beginning more than 2 cm distal to the arterial origin. Localized aneurismal sacs or prominence, both proximal and distal, can be seen along a narrowed, normal or unusually dilated portion of the artery. Intimal flaps are specific findings, but rarely present or double lumen can be found (20).

MR images the eccentric or circumferential periarterial rim of intramural hematoma typically shows hyper-

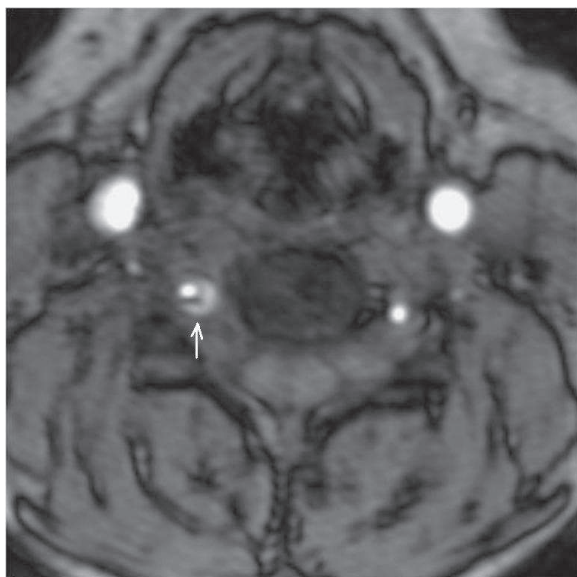


Figure 1. MR images the eccentric or circumferential periarterial rim of intramural hematoma that is typically hypertintense on T1 and T2 weighted image (Courtesy of the Department of Radiology, Sestre Milosrdnice University Hospital Centre, Zagreb).

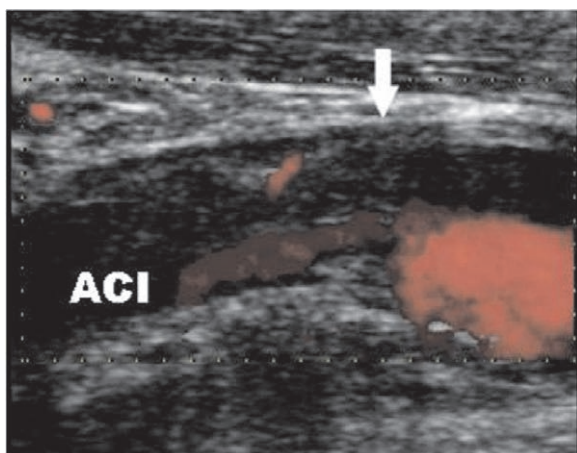


Figure 2. Echolucent intramural hematoma, string sign.

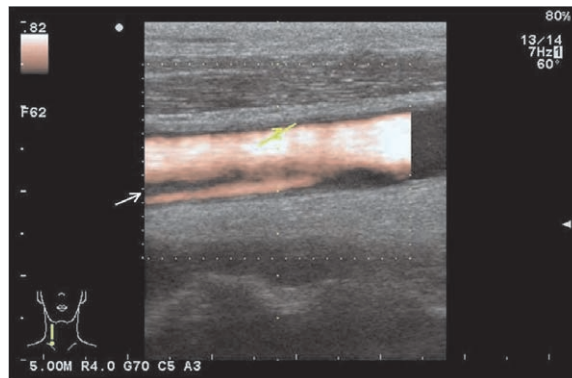


Figure 3. Double lumen and the intimal flap in between.

tintense signal on T1 and T2 weighted images (Fig. 1.) (21, 22, 23). MR angiography has limited value, imaging the same pathomorphologic findings as angiography (23).

MR and MRA showed sensitivity (SE) of 50–100%, and specificity (SP) of 29–100%. Computerized tomography (CT) and CT angiography (CTA) revealed SE of 51–100%, and SP of 67–100% (24). Doppler and duplex sonography was underrated. Although color Doppler flow imaging (CDFI) showed good results in visualization of the dissection (4, 5, 7–11, 17, 25–27), the main limitation is visualization of the intracranial dissection, which appears to be common site of localization. While CDFI provide visualization of the direct and some indirect findings of CCAD, TCD enables assessment of the intracranial hemodynamic and monitoring of the embolic signals (12, 28). The most important issue is that neurosonological evaluation enables noninvasive daily monitoring of the course of the dissection (12, 29).

The reported sensitivity of neurovascular ultrasound for detecting spontaneous CCAD varies from 80–96%. It may show direct or indirect signs (25). Direct signs are: echolucent intramural hematoma, string sign (Fig. 2.); double lumen (Fig. 3., Fig. 4., Fig. 5.), or stenosis and/or occlusion of an arterial segment usually not affected by atherosclerosis (Fig. 6.). Indirect signs are: increased or decreased pulsatility index upstream (Fig. 7.) or down-

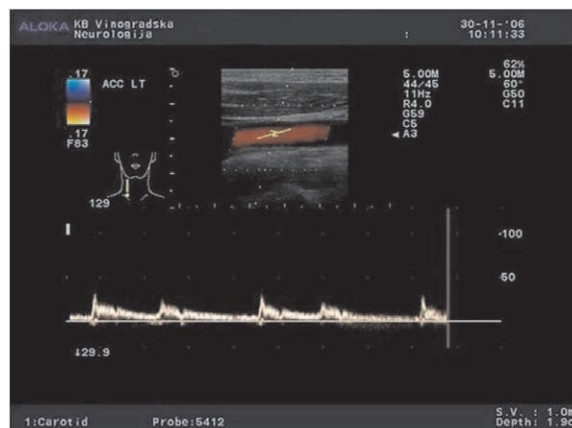


Figure 4. Double lumen: flow in the „real lumen“.

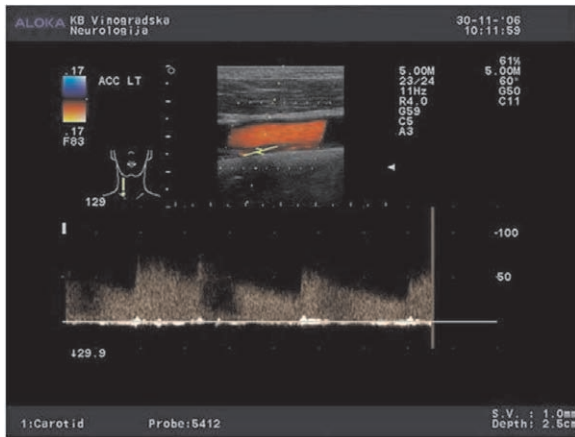


Figure 5. Double lumen: flow in the „false” lumen.

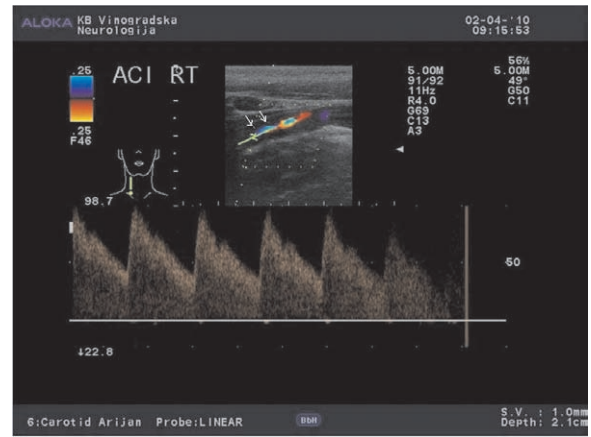


Figure 8. Increased pulsatility in the residual flow.

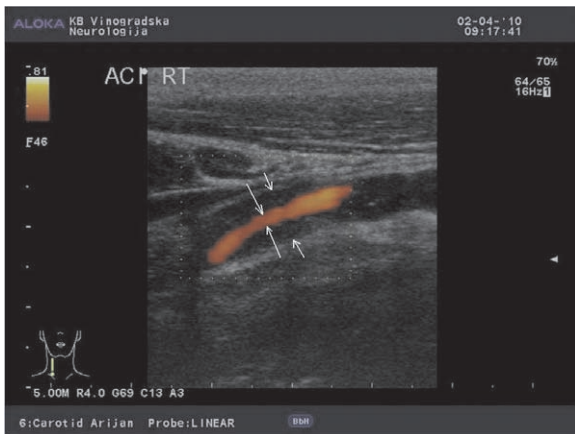


Figure 6. Stenosis of the distal part of internal carotid artery.

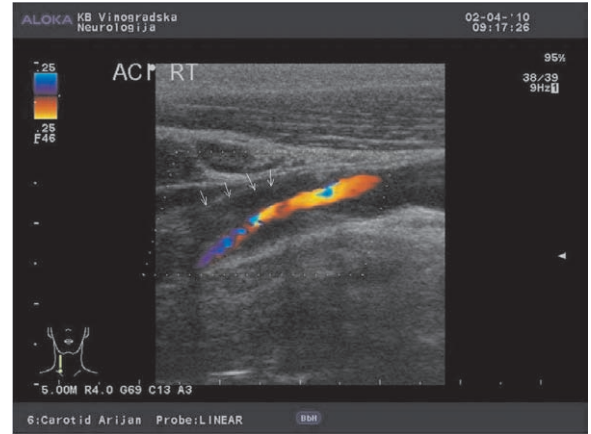


Figure 9. Tapering stenosis of the internal carotid artery.

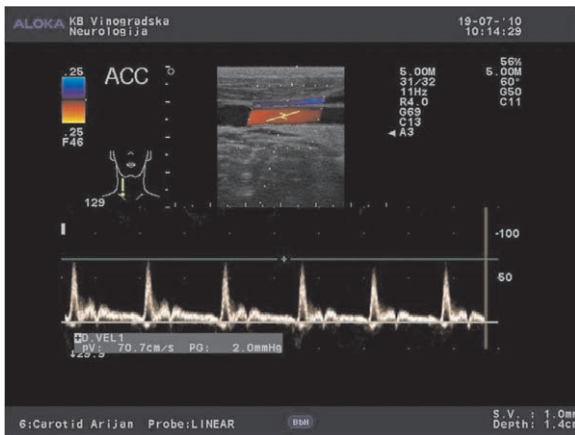


Figure 7. Increased pulsatility index downstream of the suspected lesion.

stream of the suspected lesion; more than 50% difference in blood flow velocity (BFV) compared to the unaffected side, or detection of intracranial collateral flow. Intramural hematoma is echolucent, compromising the color coded flow in the string sign (Fig. 2.) with increased pulsatility in the residual flow (Fig. 8.), or tapering steno-

sis (Fig. 9.). During follow up the regression of the hematoma will develop, and restitution of color coded filling of the arterial lumen will be visible (Fig. 10.). Resolution of the hematoma is the most specific sign for CCAD (26, 29). Double lumen (Fig. 11.), an irregular membrane crossing the lumen, is usually found in arteries originating from the aortic arch, and multi-vessel involvement is then present. If the dissection spreads to the subclavian artery, typical hemodynamic spectar in vertebral artery suggesting subclavian steal syndrome is found. In the real and false lumen different hemodynamic spectras are found. Stenosis and/or occlusion of an arterial segment not affected by atherosclerosis involve distal part of the ICA 2.0 cm or more downstream of the carotid bifurcation (Fig. 9.) or V2–V4 segment of the vertebral artery. Increased or decreased pulsatility upstream or downstream of the suspected arterial lesion (Fig. 12.) will suggest the presence of CCAD, as well as >50% difference in the BFV compared to the same segment of the artery on the unaffected side. If the hematoma compromises the flow, intracranial redistribution of hemodynamic will be detected by means of TCD or TCCD. It often shows diminished intracranial velocities in the ICA siphon and the middle cerebral artery. Usually

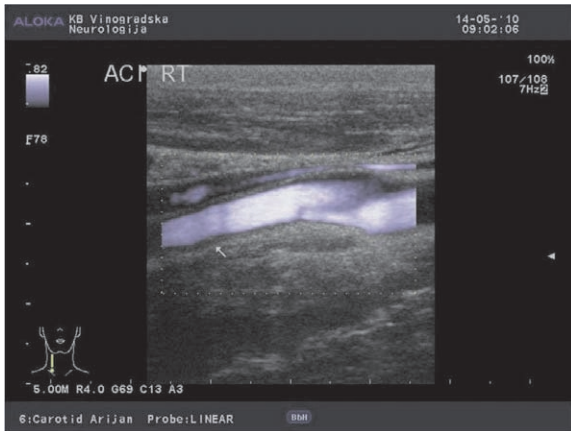


Figure 10. Restitution of color coded filling of the arterial lumen.

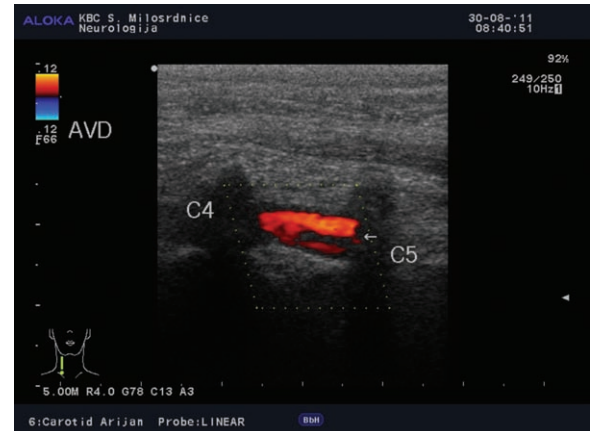


Figure 13. Double lumen as a result of vertebral artery dissection.

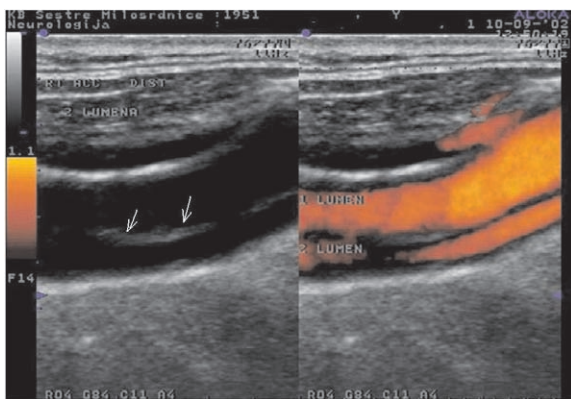


Figure 11. Double lumen and the flap in between.

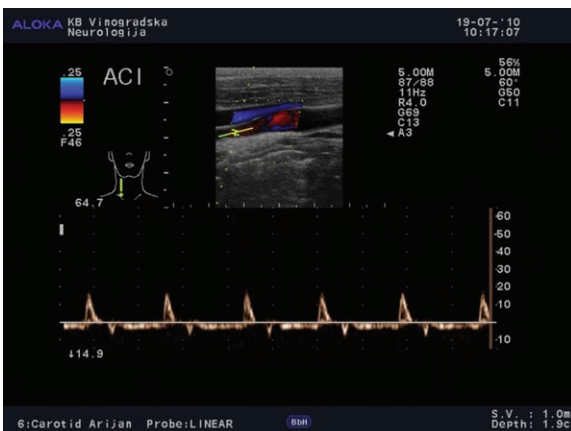


Figure 12. Increased pulsatility downstream of the suspected arterial lesion.

anterior collateral pathway is detected, and in most instances the posterior collateral pathway. Neurosonology enables noninvasive monitoring of the course of dissection, since resolution of the hematoma is the most specific finding. It enables also monitoring the microembolic signals (MES) in correlation with clinical picture. Amelioration of the clinical finding is found in correlation with reduction of MES, and worsening of the clinical picture was found in patients with increase of the num-

ber of MES. Therefore neurosonology offers the possibility of monitoring the therapeutic effect.

Ultrasound is also diagnostic in patients with vertebral artery dissections, showing the same characteristics of direct and indirect signs. Duplex ultrasound findings may show hematoma that is located usually in distal V1 part or V2 segment of the vertebral artery, due to the greater mobility of this segment and the potential to be injured in contact with bony structures such as cervical vertebrae. Double lumen can also be found (Fig. 13.). Finding also includes narrowed or dilated vascular segments. Doppler spectra might show no flow or high-resistance flow patterns at the atlas loop of the extracranial vertebral artery, and decreased velocities within proximal arterial segments that seemed normal on B-mode images, providing indirect evidence of dissection. Compensatory high flow velocities are often found in the contralateral vertebral arteries in the neck.

Ultrasound serves as a screening tool as it is highly operator dependent. The diagnosis should be confirmed with MRI and MRA. These techniques provide both a brain image that shows the location and extent of infarction, and images of the supply arteries. The MRA vascular images of the neck and intracranial arteries often show vascular narrowing, occlusions or dilatations that are characteristic (along with the clinical symptoms and signs) of a dissection etiology. Fat saturated cross-sectional images in the regions of vascular abnormalities can aid the diagnosis of dissection by showing blood within the arterial wall.

RESOLUTION OF THE ABNORMALITY

The proportion of patients with complete resolution of arterial abnormalities varies between studies and was estimated at about 46% for stenoses, 33% for occlusions, and 12% for dissecting aneurysms in the general population (14). The highest is the likelihood of complete recanalization in patients with CCAD presenting with only local symptoms and signs (27). Occlusions can re-analyze partially or completely, and residual aneurysms can appear after the acute phase in initially stenotic or

occluded arteries (1). In most patients complete resolution or stable residual luminal irregularity was achieved within the first year (14).

CONCLUSION

CCAD is a heterogeneous condition with diverse clinical pictures. Although the incidence is relatively low, it is high in young patients presenting with stroke. Neurosonological tests are a practical bedside screening tool, with a perfect monitoring capacity. Magnetic resonance angiography with cervical MRI are required to confirm the diagnosis.

REFERENCES

- DEBETTE S, LEYS D 2009 Cervical-artery dissections: predisposing factors, diagnosis, and outcome. *Lancet Neurol* 8: 668–78
- CAPLAN L R 2008 Dissections of brain-supplying arteries. *Nat Clin Pract Neurol CME* 4: 34–42
- PROVENZALE J M 2009 MRI and MRA for evaluation of dissection of craniocerebral arteries: lessons from the medical literature. *Emerg Radiol* 16: 185–93
- STURZENEGGER M, MATTLE H P, RIVOIR A, RIHS F, SCHMID C 1993 Ultrasound findings in spontaneous extracranial vertebral artery dissection. *Stroke* 24: 1910–21
- STEINKE W, RAUTENBERG W, SCHWARTZ A, HENNERICI M 1994 Noninvasive monitoring of internal carotid artery dissection. *Stroke* 25: 998–1005
- SIDHU P S, JONKER N D, KHAW K T, PATEL N, BLOMLEY M J K, CHAUDHURI K R, FRACKOWIAK R S J, COSGROVE D O 1997 Spontaneous dissections of the internal carotid artery: appearances on colour Doppler ultrasound. *Brit J Radiol* 70: 50–7
- TRATTNIG S, RAND T, THURNHER M, BREITENSEHER M, DAHA K 1995 Colour-coded Doppler sonography of common carotid artery dissection. *Neuroradiology* 37: 124–6
- DE BRAY J M, LHOSTE P, DUBAS F, EMILE J, SAUMET J L 1994 Ultrasonic features of extracranial carotid dissections: 47 cases studied by angiography. *J Ultrasound Med* 13: 59–64
- BARTELS E, FLUGEL K A 1996 Evaluation of extracranial vertebral artery dissection with duplex color-flow imaging. *Stroke* 27: 290–5
- LOVRENČIĆ-HUZJAN A, JURAŠIĆ M J, LOVRENČIĆ-PRPIĆ G, VUKOVIĆ V, DEMARIN V 2006 Aortic arch dissection presenting with hemodynamic spectrum of aortic regurgitation on transcranial Doppler. *Ultraschall Med* 27: 280–3
- LOVRENČIĆ-HUZJAN A, BOSNAR-PURETIĆ M, VUKOVIĆ V, DEMARIN V 2002 Sonographic features of craniocervical artery dissection. *Acta clin Croat* 41: 307–12
- LOVRENČIĆ-HUZJAN A, KLANFAR Z, BOSNAR-PURETIĆ M, DEMARIN V 2002 Embolic stroke due to internal carotid dissection: non-invasive monitoring of recanalisation by color Doppler flow imaging and transcranial Doppler. *Acta clin Croat* 42: 201–5
- MOLINA C A, ALVAREZ-SABIN J, SCHONEWILLE W, MONTANER J, ROVIRA A, ABILLEIRA S, CODINA A 2000 Cerebral microembolism in acute spontaneous internal carotid artery dissection. *Neurology* 55: 1738–41
- LEE V H, BROWN R D, MANDREKAR J N, MOKRI B 2006 Incidence and outcome of cervical artery dissection: a population-based study. *Neurology* 67: 1809–12
- SCHIEVINK W I, MOKRI B, PIEPGRAS D G, KUIPER J D 1996 Recurrent spontaneous arterial dissections: risk in familial versus nonfamilial disease. *Stroke* 27: 622–4
- BRANDT T, ORBERK E, WEBER R, WERNER I, BUSSE O, MÜLLER B T, WIGGER F, GRAU A, GROND-GINSBACH C, HAUSSER I 2001 Pathogenesis of cervical artery dissections: association with connective tissue abnormalities. *Neurology* 57: 24–30
- ČERIMAGIĆ D, GLAVIĆ J, LOVRENČIĆ-HUZJAN A, DEMARIN V 2007 Occlusion of vertebral artery, cerebellar infarction and obstructive hydrocephalus following cervical spine manipulation. *Eur Neurol* 58: 248–50
- HART R G, EASTON J D 1983 Dissections of cervical and cerebral arteries. *Neurol Clin* 1: 155–93
- LOVRENČIĆ-HUZJAN A, VUKOVIĆ V, AŽMAN D, BENE R, DEMARIN V 2008 Pain and ischemic symptoms in craniocervical artery dissection. *Acta Med Croatica* 62: 223–7
- HOUSER O W, MOKRI B, SUNDT T M, BAKER H L, REESE D F 1984 Spontaneous cervical cephalic arterial dissection and its residuum: angiographic spectrum. *AJNR* 5: 27–34
- RODALLEC M H, MARTEAU V, GERBER S, DESMOTTES L, ZINS M 2008 Craniocervical arterial dissection: spectrum of imaging findings and differential diagnosis. *Radiographics* 28: 1711–28
- HOFFMANN M, SACCO R L, CHAN S, MOHR J P 1993 Non-invasive detection of vertebral artery dissection. *Stroke* 24: 815–9
- AUER A, FELBER S, SCHMIDAUER C, WALDENBERGER P, AICHNER F 1998 Magnetic resonance angiographic and clinical features of extracranial vertebral artery dissection. *J Neurol Neurosurg Psychiatry* 64: 474–81
- PROVENZALE J M, SARIKAYA B 2009 Comparison of test performance characteristic of MRI, MR angiography and CT angiography in the diagnosis of carotid and vertebral artery dissection: a review of the medical literature. *AJNR* 193: 1167–74
- NEDBELSIECK J, SENGLHOFF C, NASSENSTEIN I, MAINTZ D, KUHLEBAUMER G, NABAVI DG, RINGELSTEIN EB, DITTRICH R 2009 Sensitivity of neurovascular ultrasound for the detection of spontaneous cervical artery dissection. *J Clin Neurosci* 16: 79–82
- ARNING C 2005 Ultrasonographic criteria for diagnosing a dissection of the internal carotid artery. *Ultraschall Med Eur J Ultrasound* 26: 24–8
- NEDELTCHEV K, BICKEL S, ARNOLD M, SARIKAYA H, GEORGIADIS D, STURZENEGGER M, MATTLE H P, BAUMGARTNER R W 2009 R2-recanalization for spontaneous carotid artery dissection. *Stroke* 40: 499–504
- MOLINA C A, ALVAREZ-SABIN J, SCHONEWILLE W, MONTANER J, ROVIRA A, ABILLEIRA S, CODINA A 2000 Cerebral microembolism in acute spontaneous internal carotid artery dissection. *Neurology* 55: 1738–41
- BARACCHINI C, TONELLO S, MENAGHETTI G, BALLOTTA E 2010 Neurosonographic monitoring of 105 spontaneous cervical artery dissections: a prospective study. *Neurology* 75: 1864–70